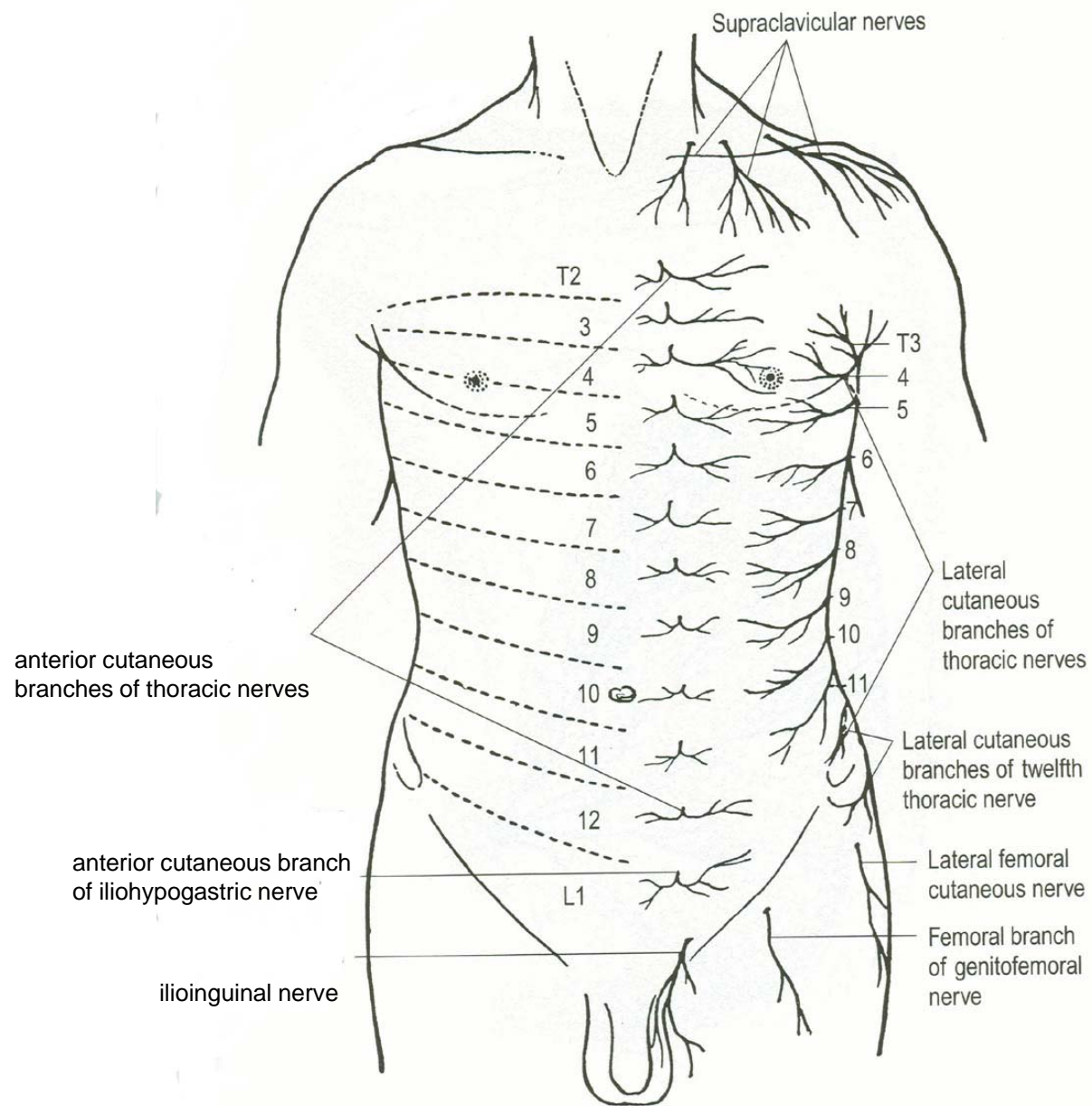
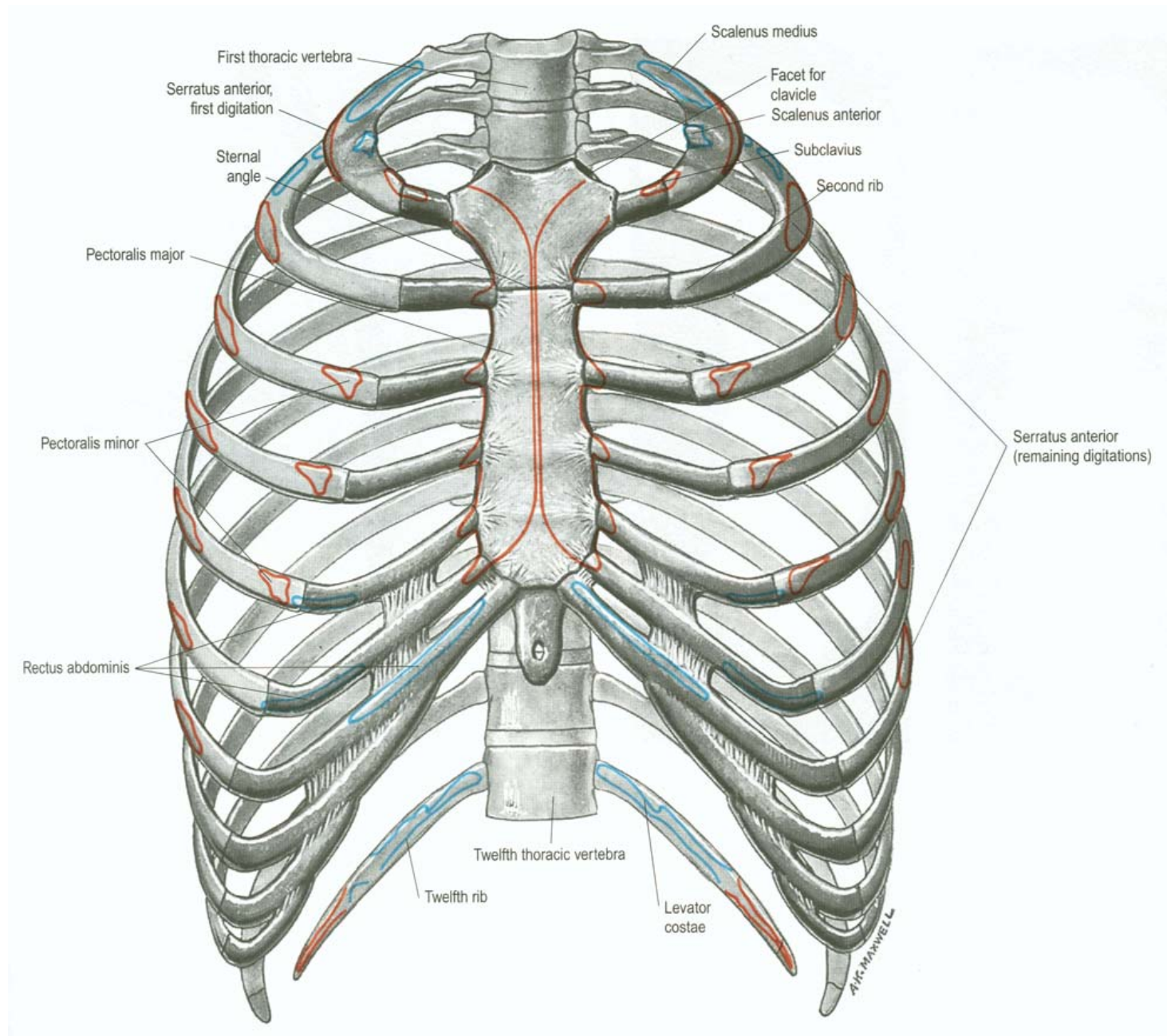
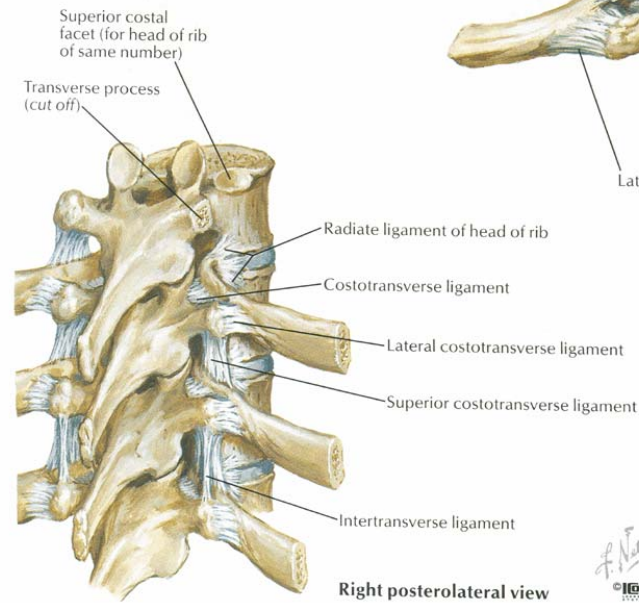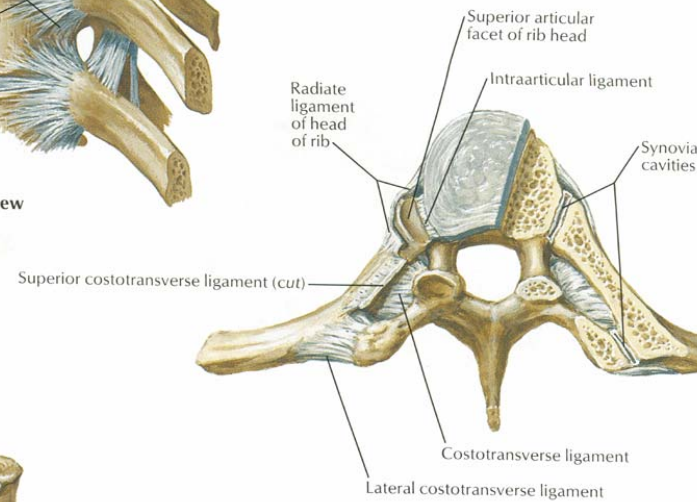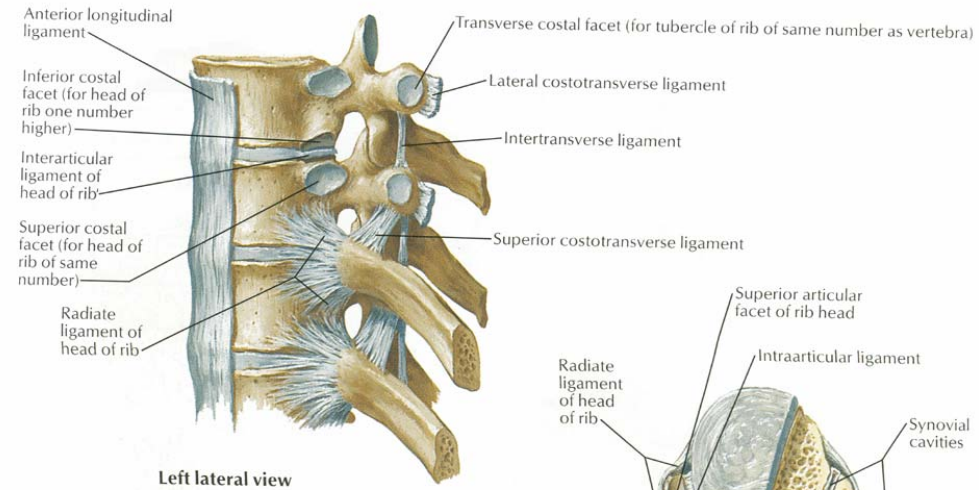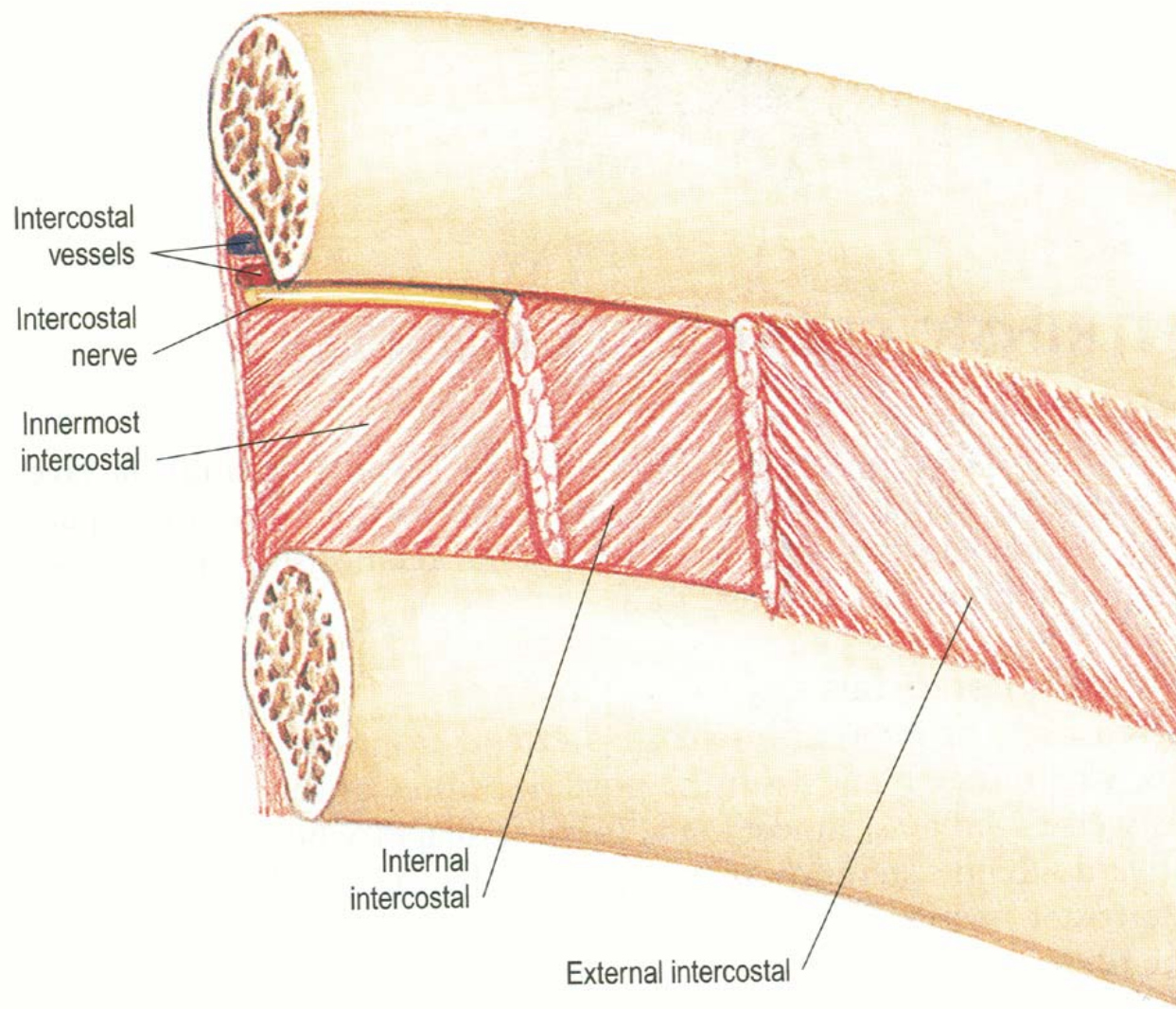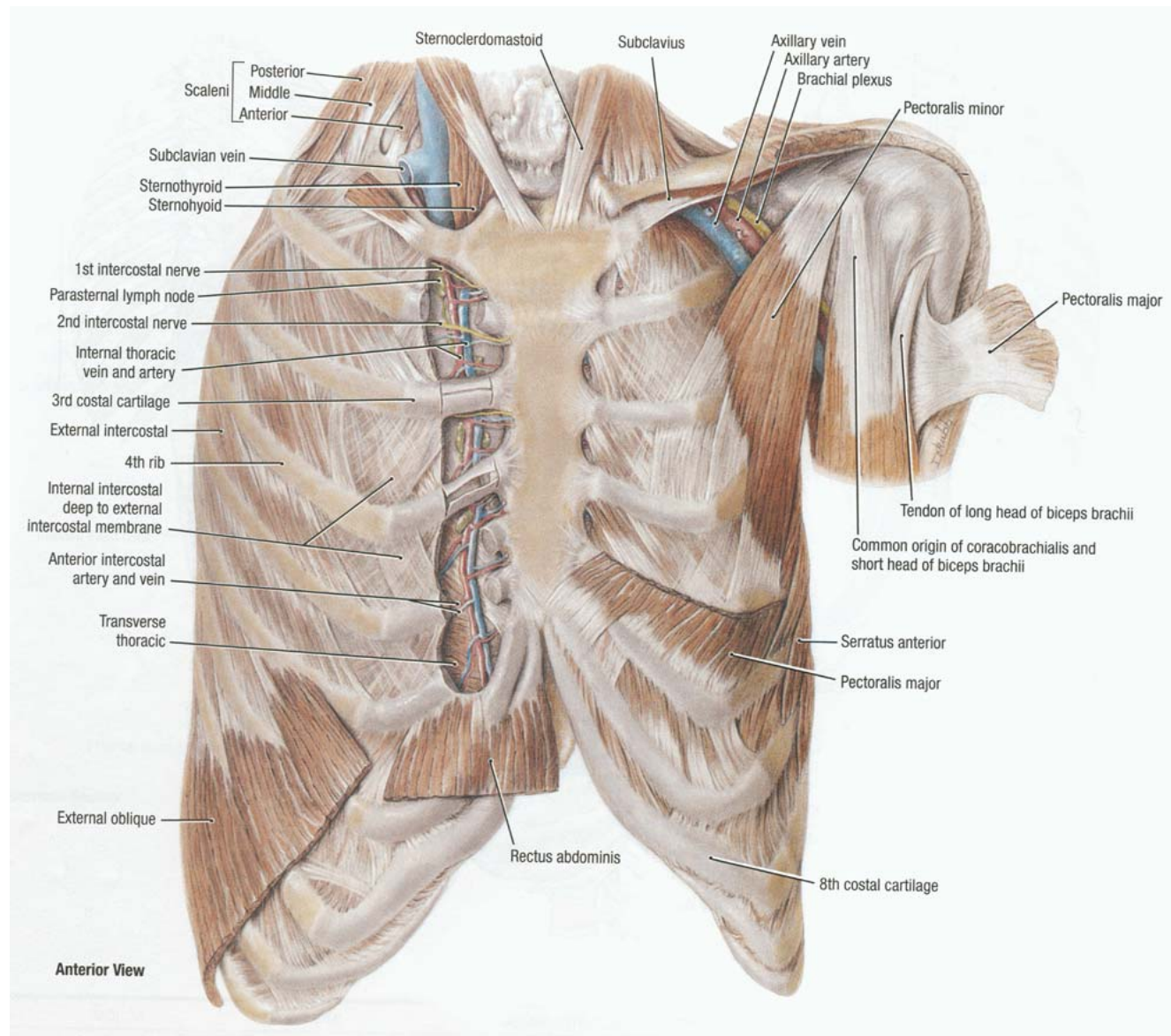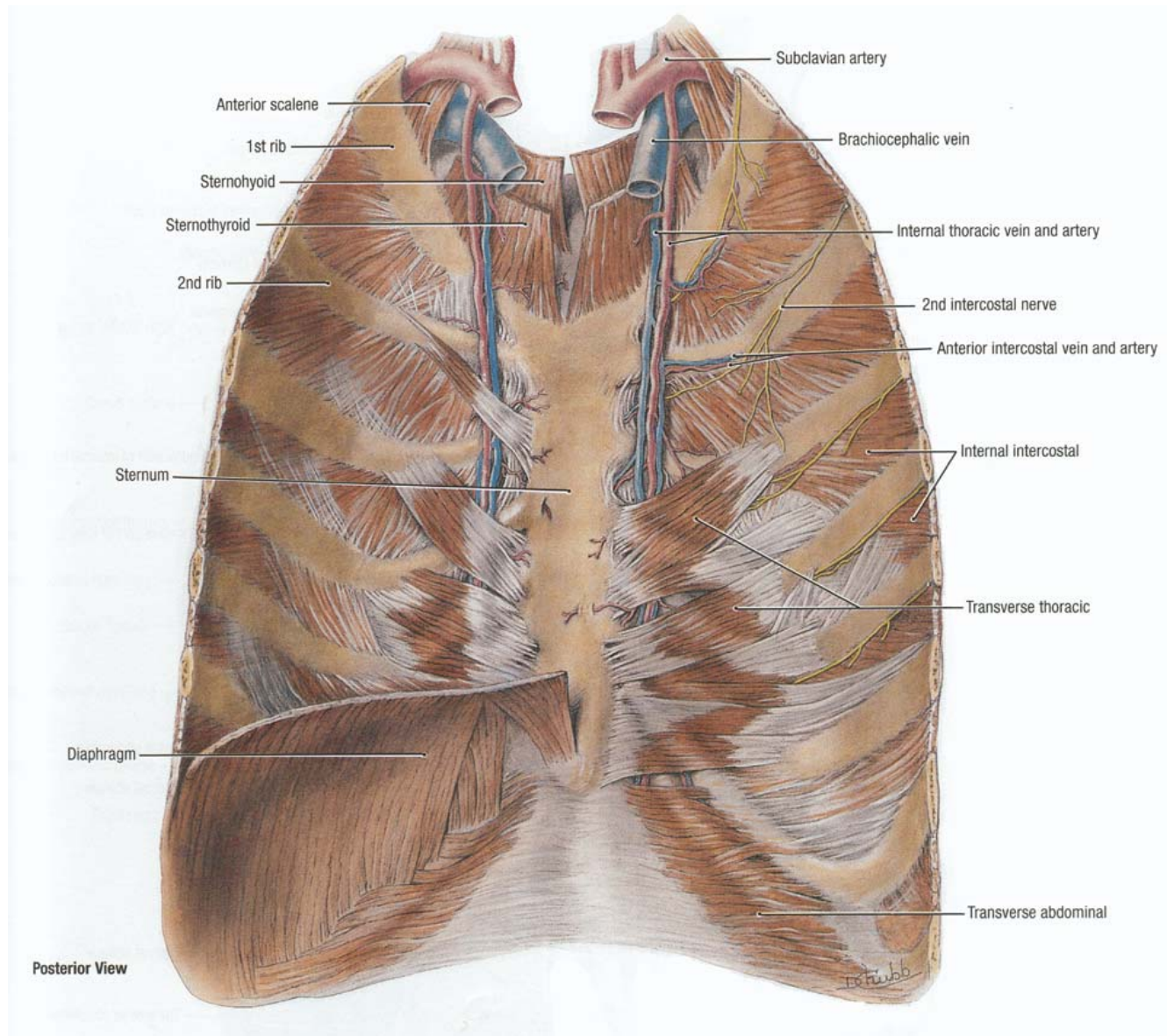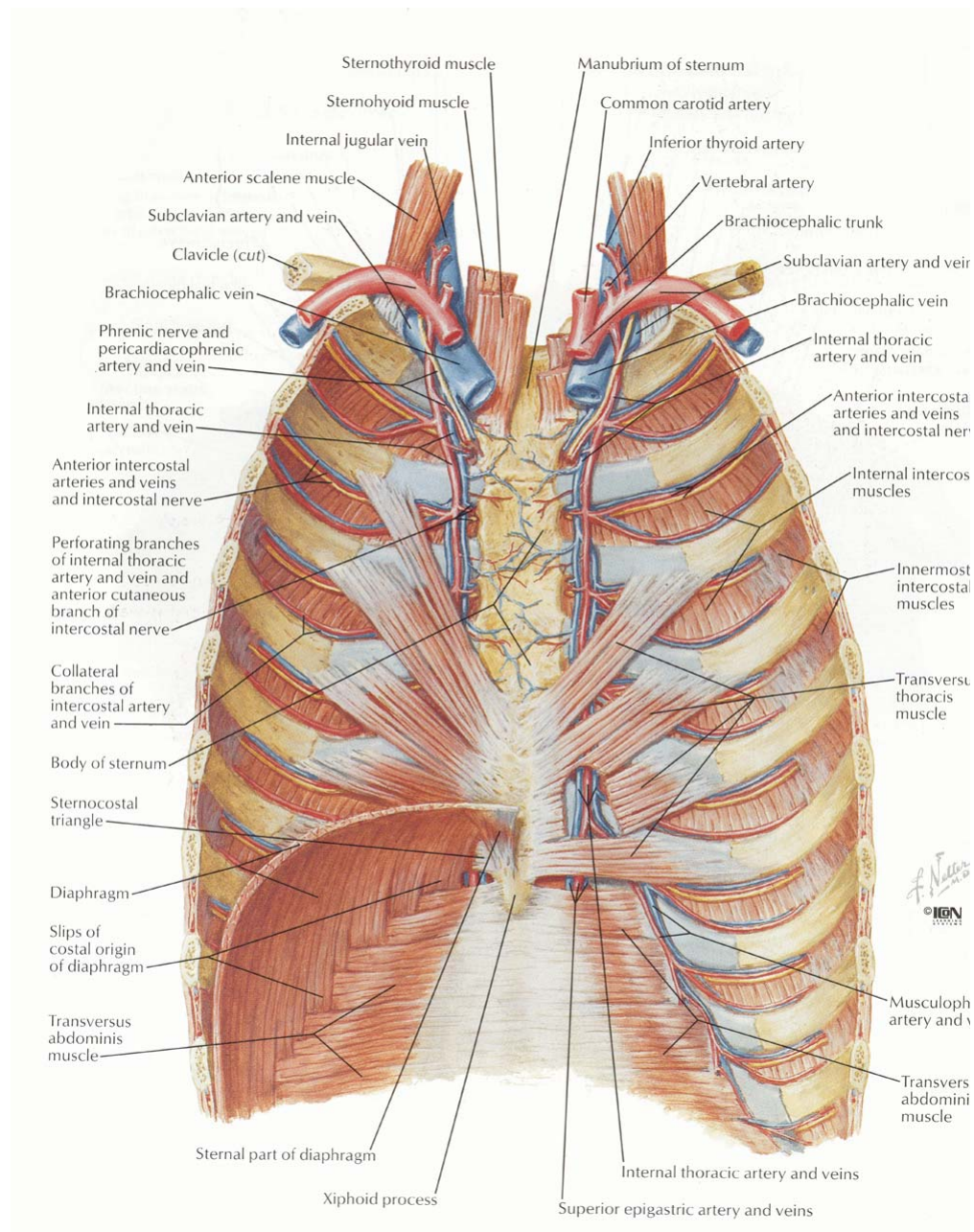EXTERNAL INTERCOSTAL MUSCLE

Origin:

Inferior border of rib above.

Insertion:

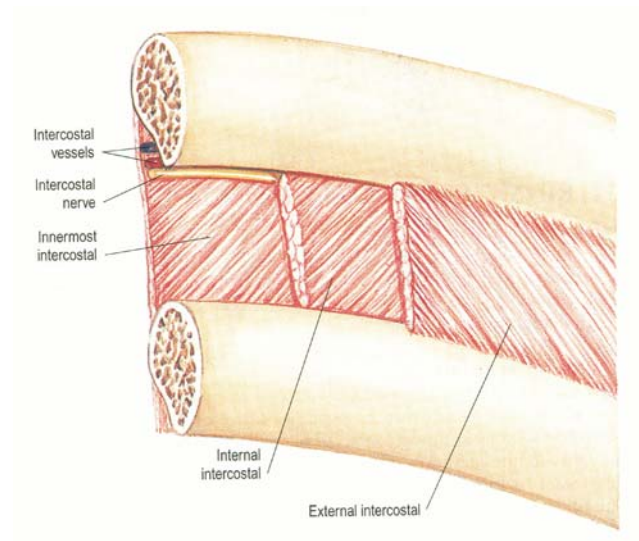
Superior border of rib below.

Extent:

From tubercle of rib posteriorly to costochondral junction anteriorly. Medial to it, it is replaced by external intercostal membrane.

Direction of fibres:

Downwards and laterally at the back and downwards, forwards and medially in front.



INTERNAL INTERCOSTAL MUSCLE

Origin:

Floor of subcostal groove of rib above.

Insertion:

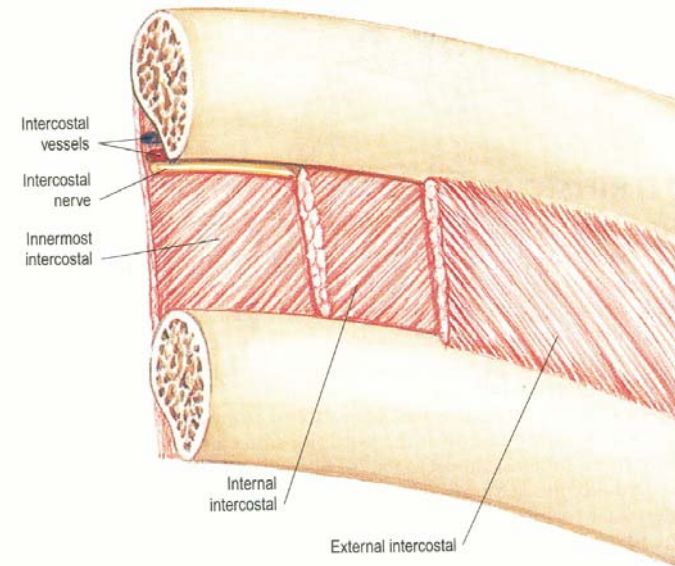
Superior border of rib below
(inner to the attachment of
external intercostal muscle).

Extent:

From lateral border of sternum anteriorly
to angle of rib posteriorly. Medial to it,
it is replaced by internal intercostal membrane.

Direction of fibres:

At right angle to the direction of external intercostal.



INNERMOST INTERCOSTAL MUSCLE

Origin:

Upper margin of subcostal groove of rib above.

Insertion:

Superior border of rib below
(inner to the attachment of
internal intercostal muscle),
or inner surface of the rib close to the
superior border.

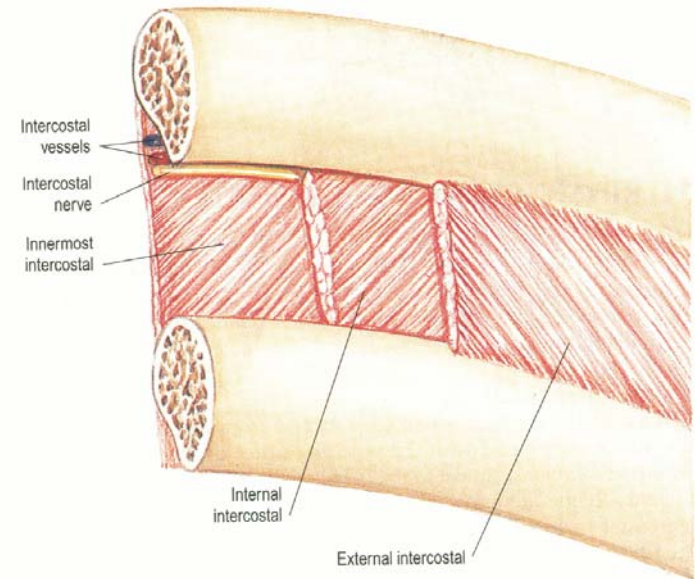
Extent:

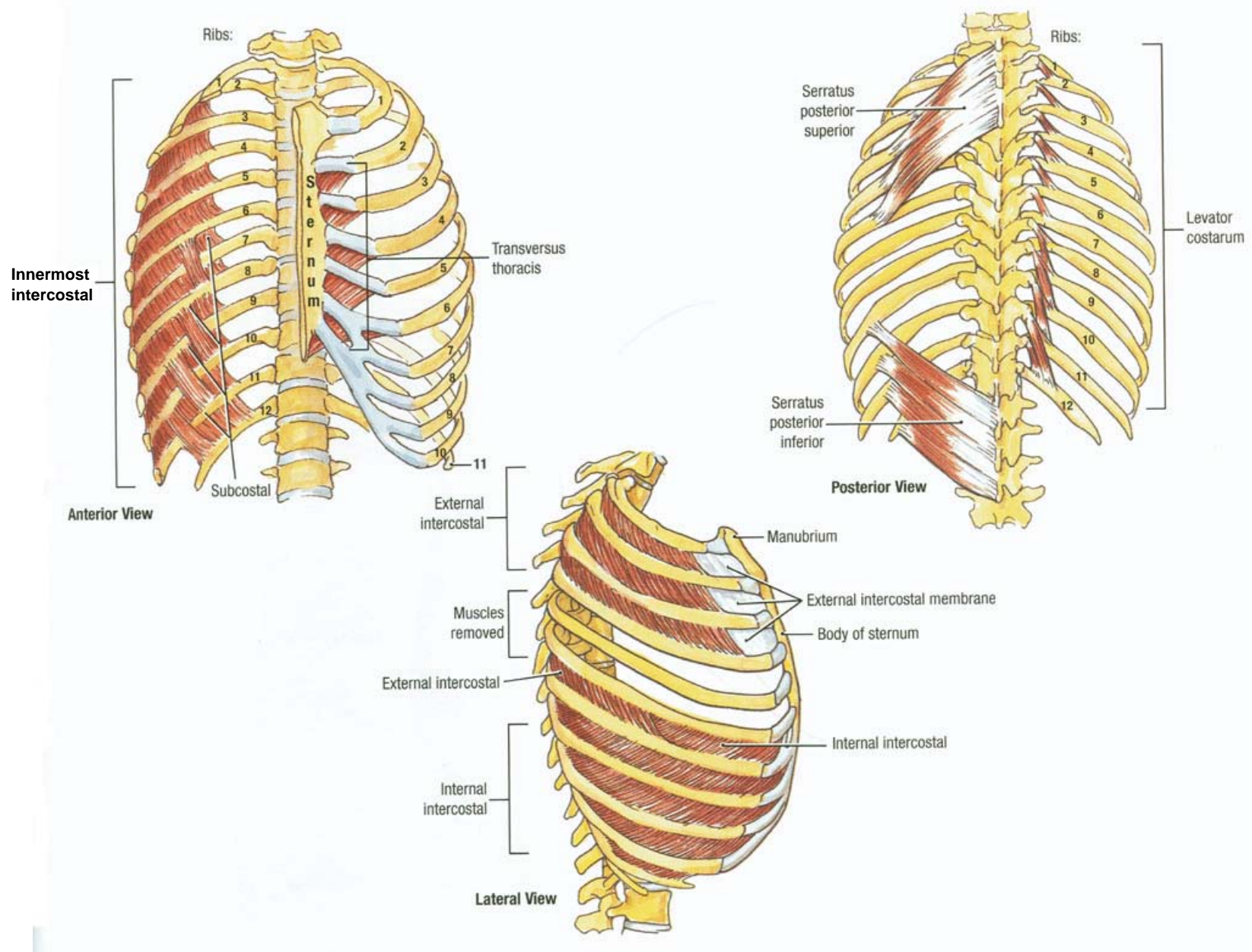
Present in middle two fourths of the lower intercostal spaces.

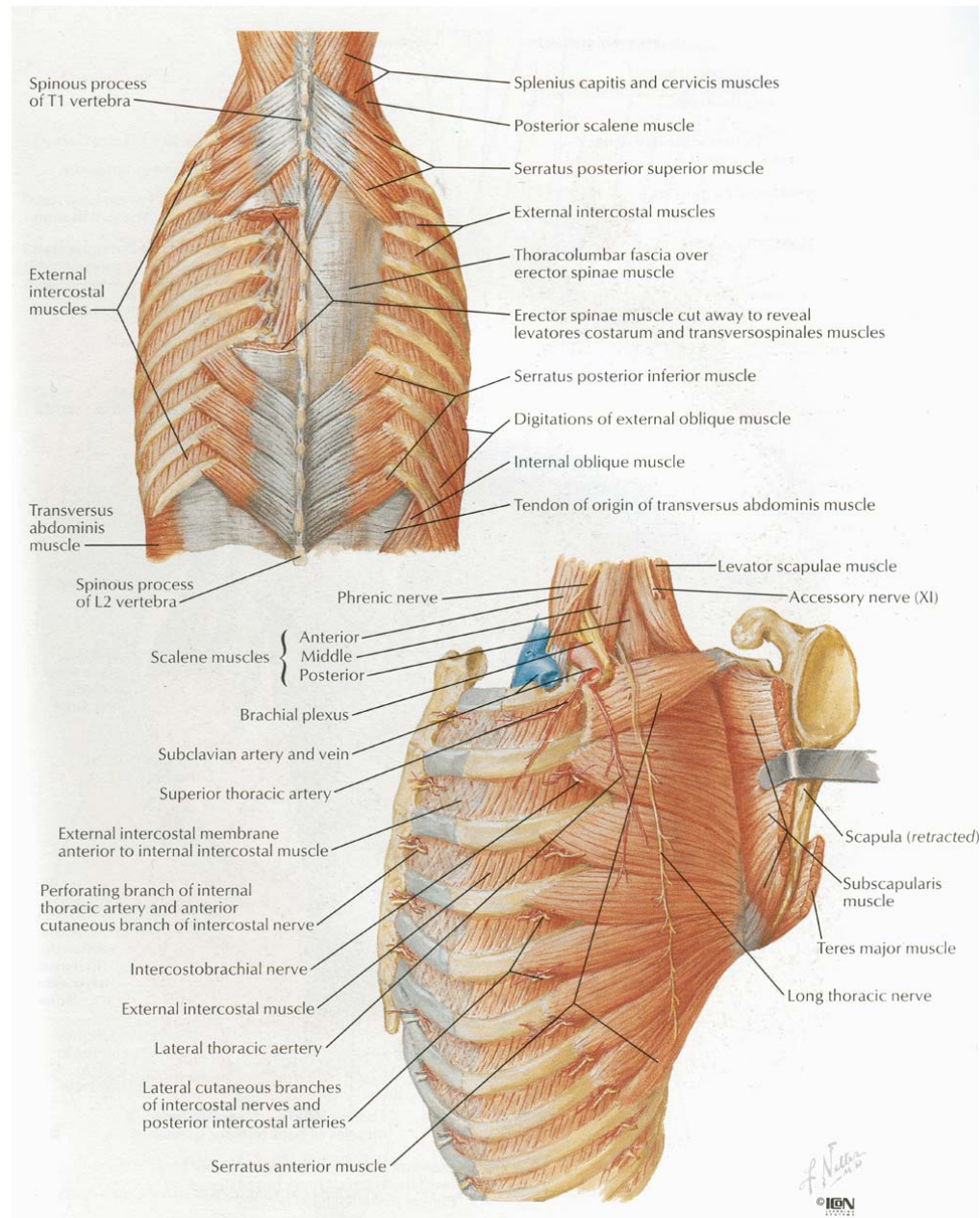
Poorly developed or even absent in the upper spaces.

Direction of fibres:

Same as internal intercostal (at right angle to the direction of external intercostal).







SUBCOSTALIS

Present on the inner aspect of intercostal spaces posteriorly.

Origin:

Inner surface of rib above, near its angle.

Insertion:

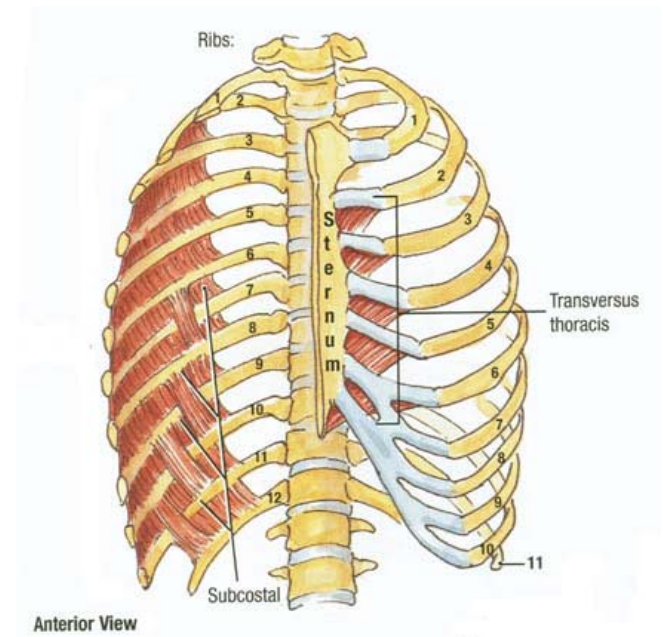
Inner surface of second or third rib below.

Extent:

Present in middle two fourths of the lower intercostal spaces. Well developed only in the lower spaces.

Direction of fibres:

Same as innermost intercostal.



TRANSVERSUS THORACIS

Present on the inner surface of anterior thoracic wall.

Origin:

Lower 1/3 of posterior surface of sternum,
posterior surface of xiphisternum &
posterior surfaces of costal cartilages of 4th to
7th ribs.

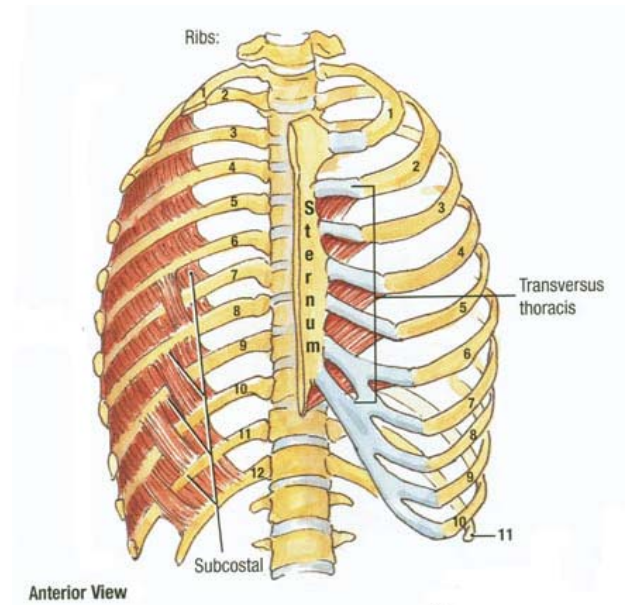
Insertion:

Lower border and posterior surfaces costal cartilages of 2nd to 6th ribs.

Attachments are variable and may even differ on the two sides.

Direction of fibres:

Lowest fibres are horizontal, become gradually oblique and upper most fibres are directed upwards and laterally.



LEVATORES COSTARUM

12 muscle bundles on each side.

Origin:

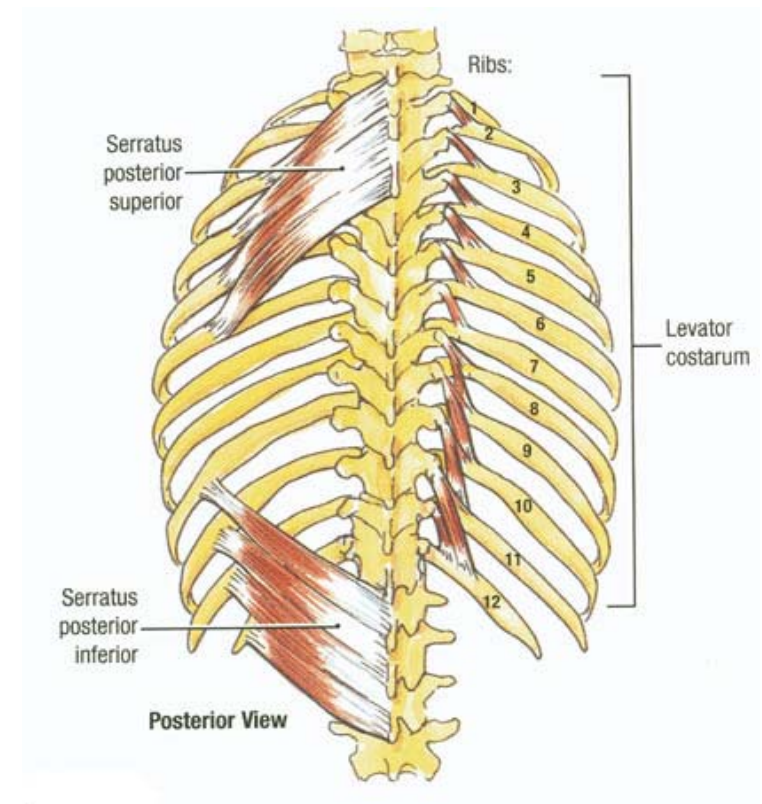
From near the tip of transverse processes of 7th cervical and upper 11 thoracic vertebrae.

Insertion:

Posterior surface and upper border of the rib immediately below, between the tubercle and the angle.

Each of the lower 4 muscles divides into two bundles –

One is attached to the rib immediately below and the other is attached to the *second* rib below its origin.



SERRATUS POSTERIOR SUPERIOR

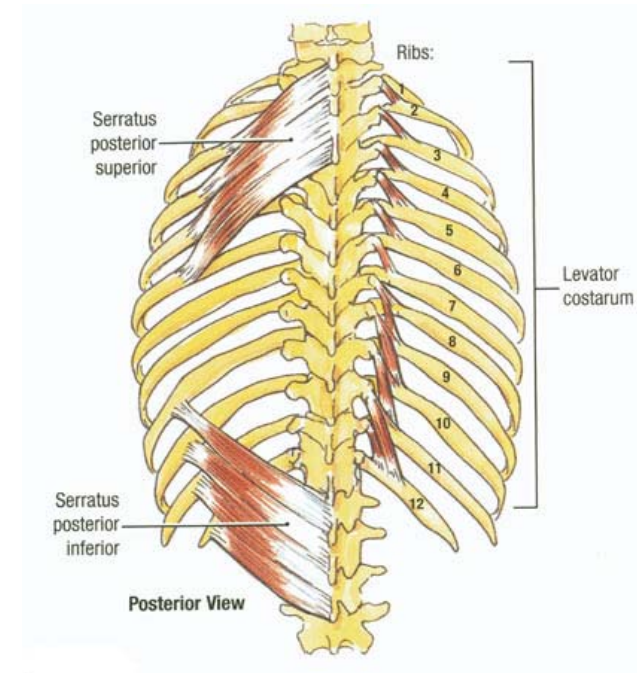
Lies deep to the rhomboids.

Origin:

Lower part of ligamentum nuchae,
spines of 7th cervical and upper 2 or 3 thoracic
vertebrae and supraspinous ligament.

Insertion:

By four digitations, into
upper border and posterior surfaces of 2nd to
5th ribs, lateral to their angles.



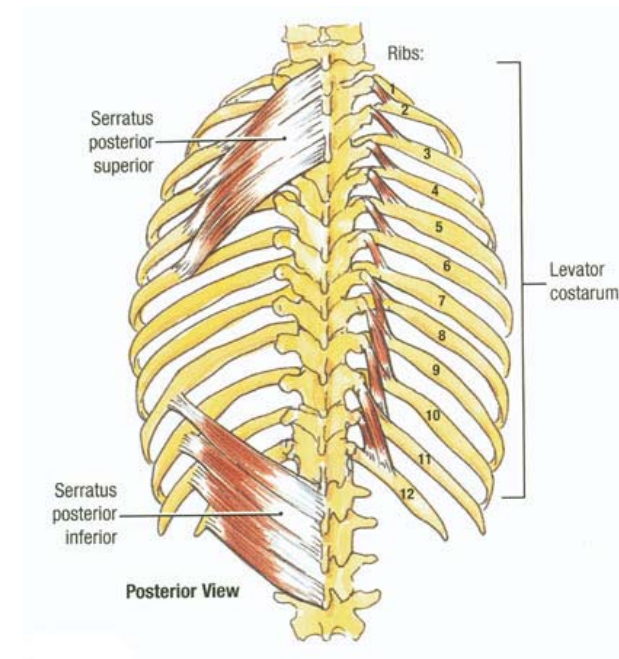
SERRATUS POSTERIOR INFERIOR

Origin:

Spines of 11th & 12th thoracic and 1st to 3rd lumbar vertebrae and supraspinous ligaments.

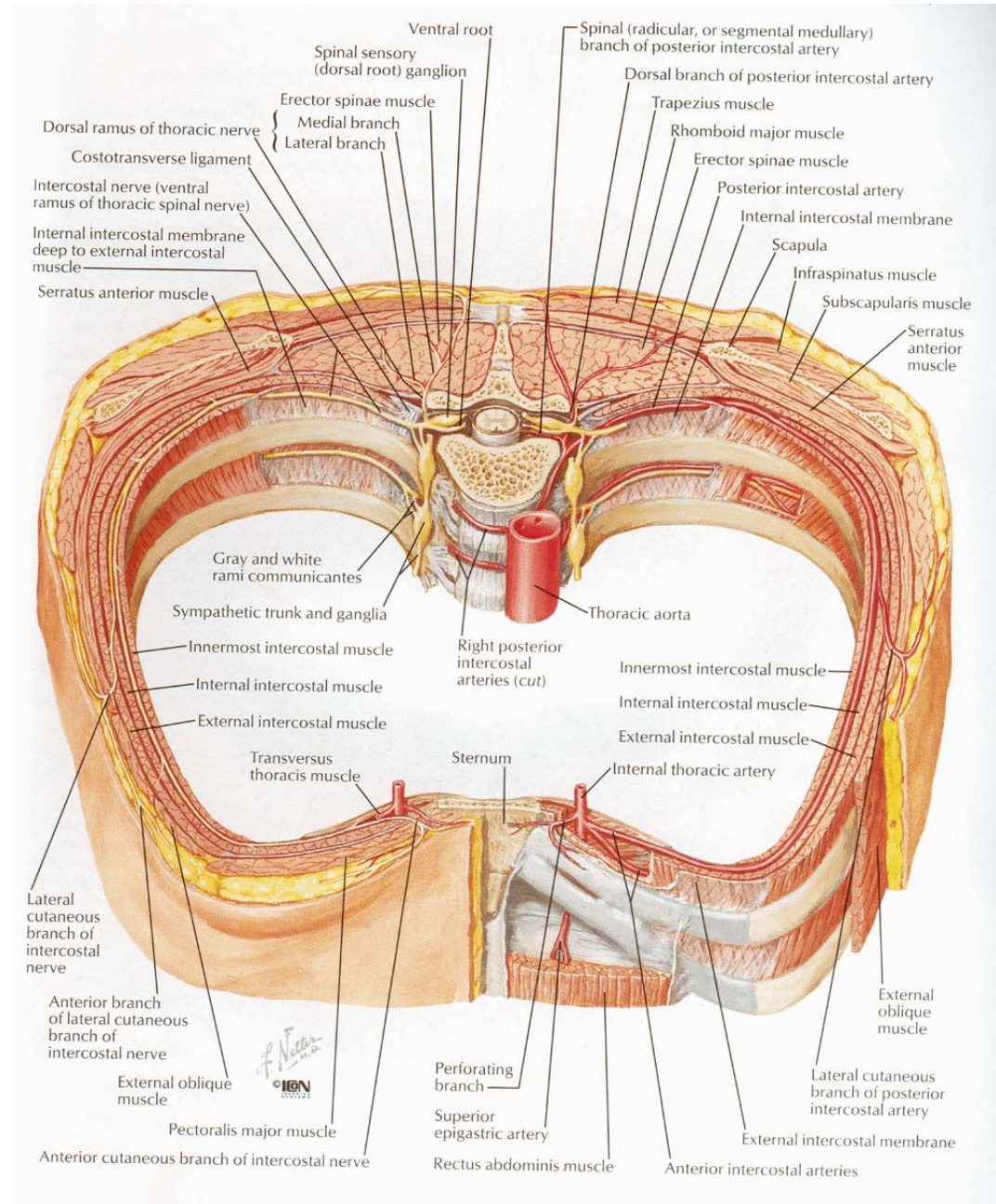
Insertion:

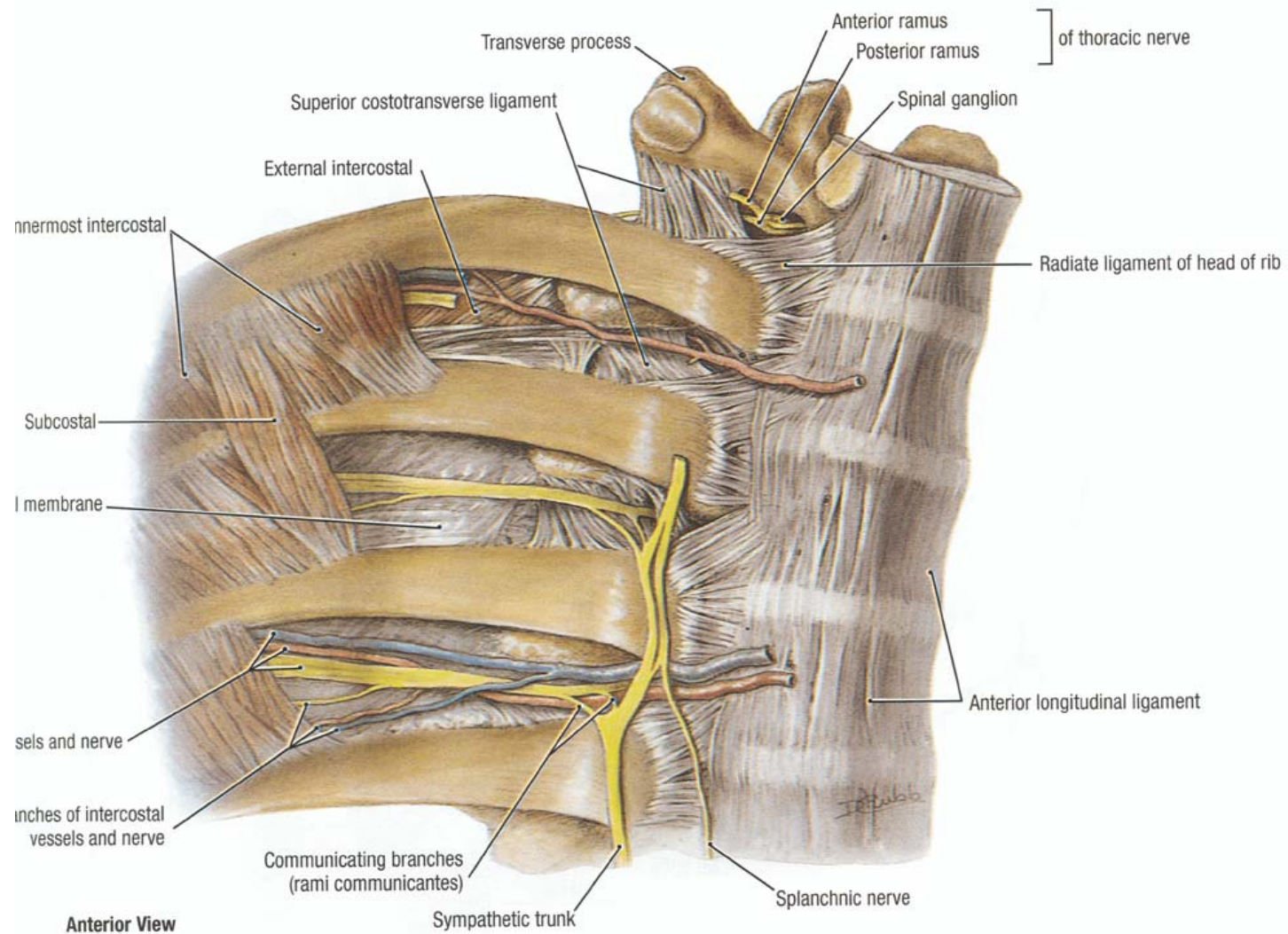
By four digitations, into lower border and posterior surfaces of 9th to 12th ribs, lateral to their angles.

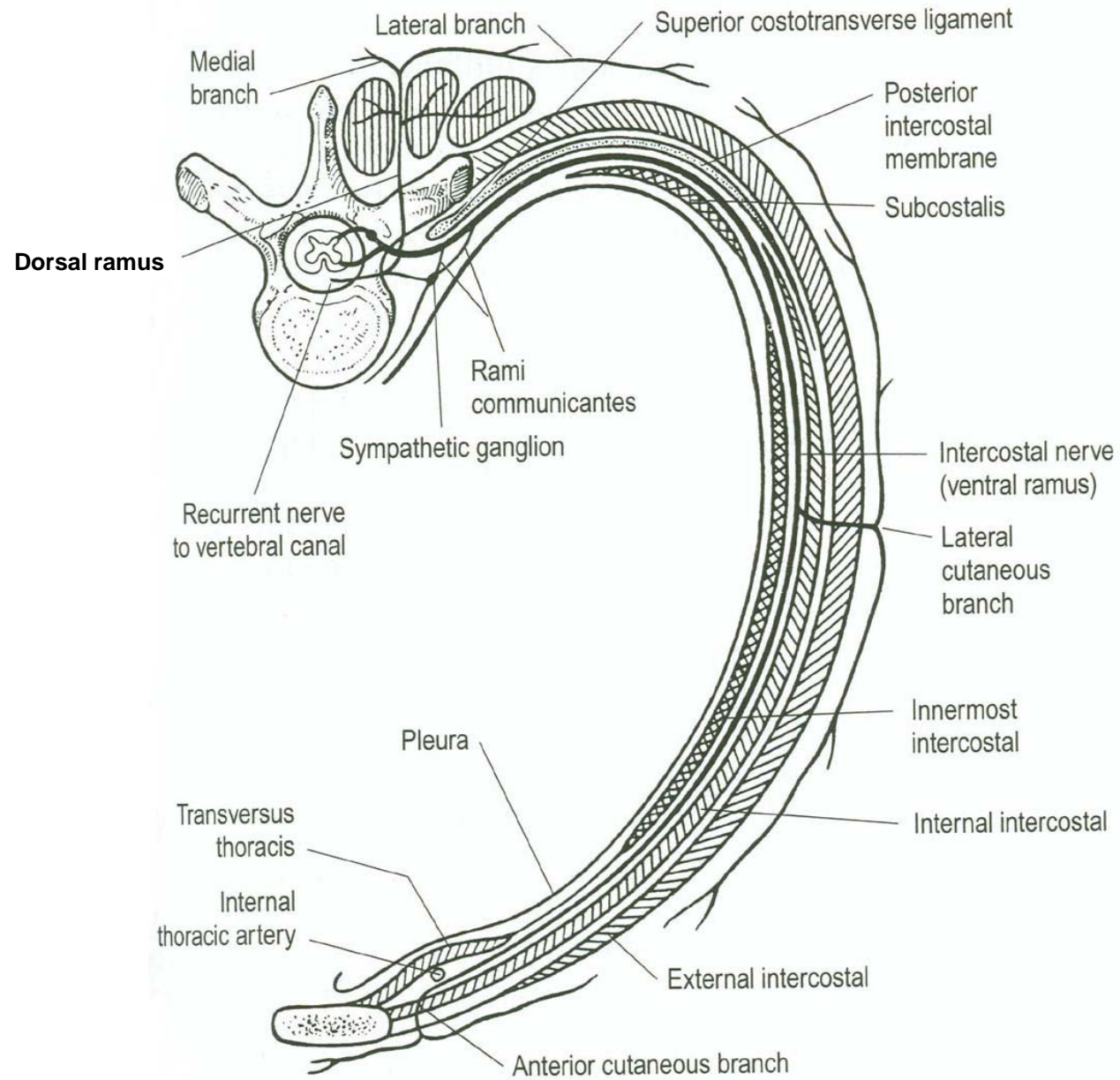


Actions

- Ext. intercostal-Inspiration, moves ribs superiorly
- Int. intercostal- Expiration, moves ribs inferiorly
- Innermost intercostal-Expiration
- Subcostales – depress ribs
- S.P.S → elevates sup. 4 ribs, raising the sternum and ↑ AP diameter
- S.P.I. → depresses the inf. Ribs, so prevents them to be picked up. By dia.
- Transverse thoracis
- Lev. Costarum unimportant







Arterial supply

- Thoracic aorta – posterior intercostal
subcostal
- Subclavian artery – internal thoracic
superior intercosta
- Axillary artery – superior thoracic
lateral thoracic

Posterior intercostal – Dorsal, collateral,
muscular, cutaneous; anastomoses with
anterior intercostal arteries.

Internal thoracic artery

- 1st branch of subclavian
- Runs in the 1st six IC spaces
- Bifurcates into musculophrenic and superior epigastric arteries

Branches: Sternal

Perforating

Ant. Intercostal—two in each space
none in lower two
spaces

Venous drainage

- Ant. Intercostal V – internal thoracic V
- Post. Intercostal V

Ist IC space – highest intercostal vein →
brachiocephalic vein

2nd & 3rd IC space – superior IC vein

4th to 11th (Right) → azygos vein

4th to 8th (Left) → acc. Hemiazygos

9th to 11th (Left) → hemiazygos

12th – subcostal vein

Nerve supply

- Ant. rami of thoracic spinal nerves
- Branches
 - Dorsal
 - Rami communicantis
 - Collateral
 - Lateral cutaneous – anterior, posterior
 - Ant. Cutaneous – medial and lateral
 - Muscular branch
 - Pleural / peritoneal branch
- Exceptions
 - 1st IC nerve – contributes to brachial plexus no. ant. / lateral cutaneous branch
 - 2nd IC nerve – lateral anterior branch also supplies arm (IC branchial nerve)

Lymphatic drainage

- Internal thoracic (Parasternal) –
bronchomediastinal trunk → thoracic duct
- Intercostal
- Diaphragmatic