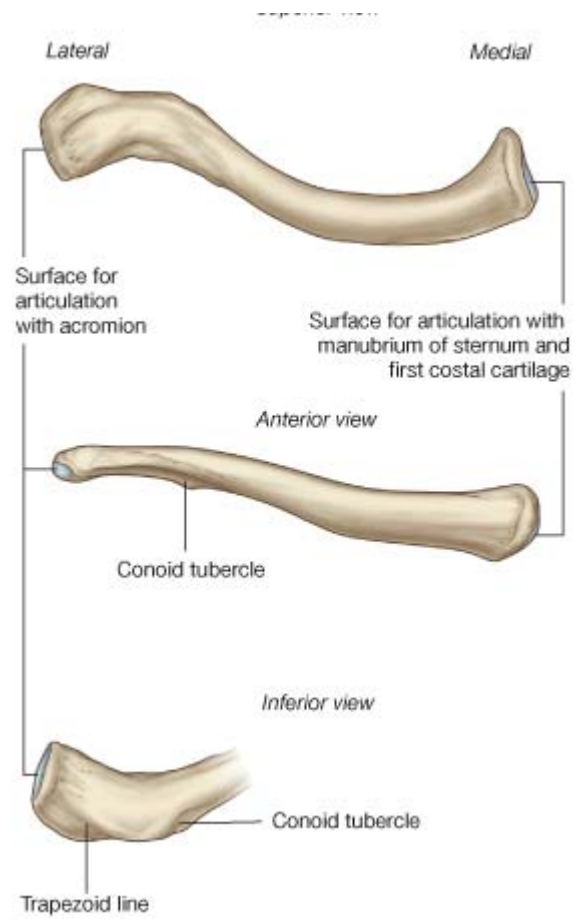
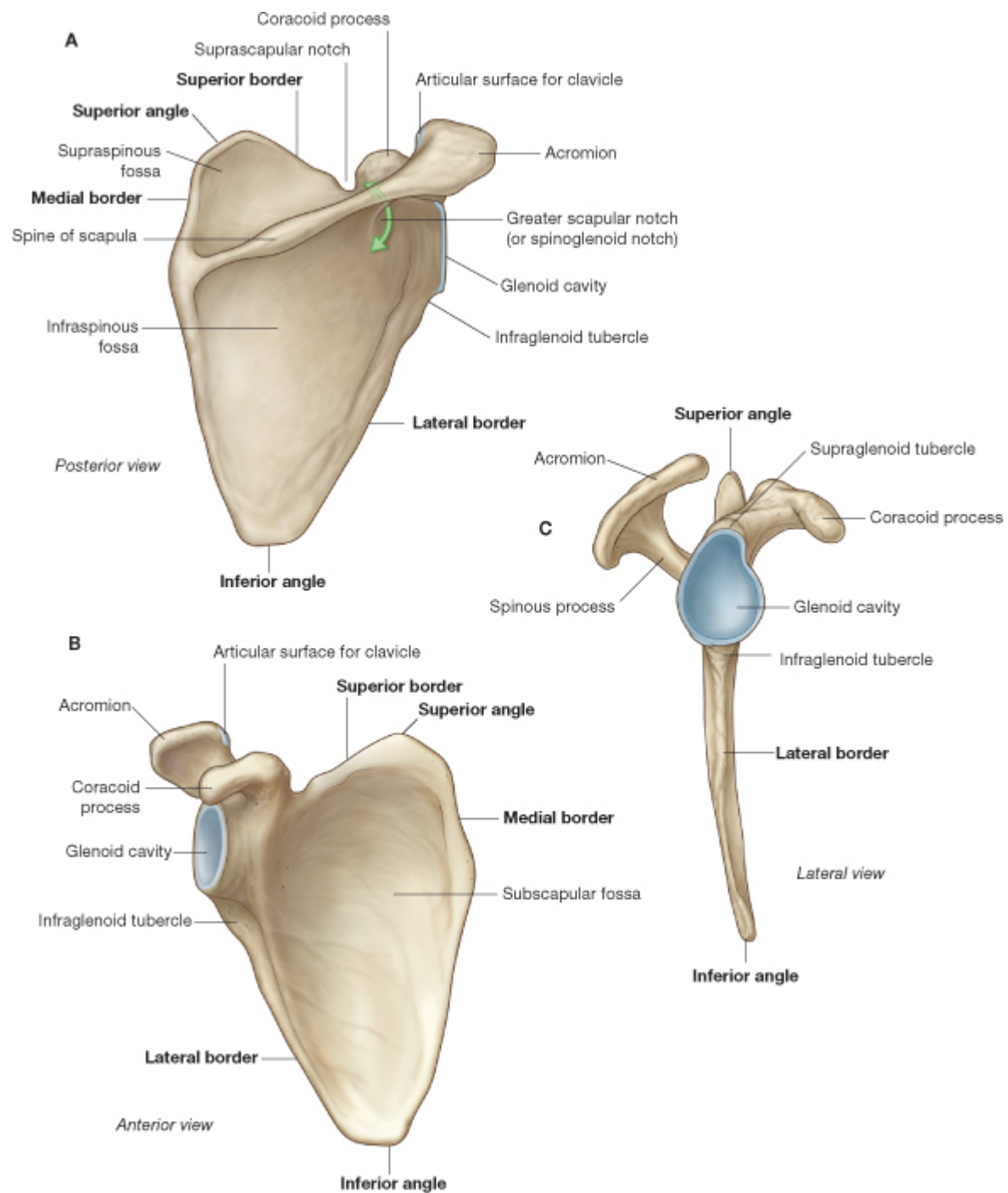
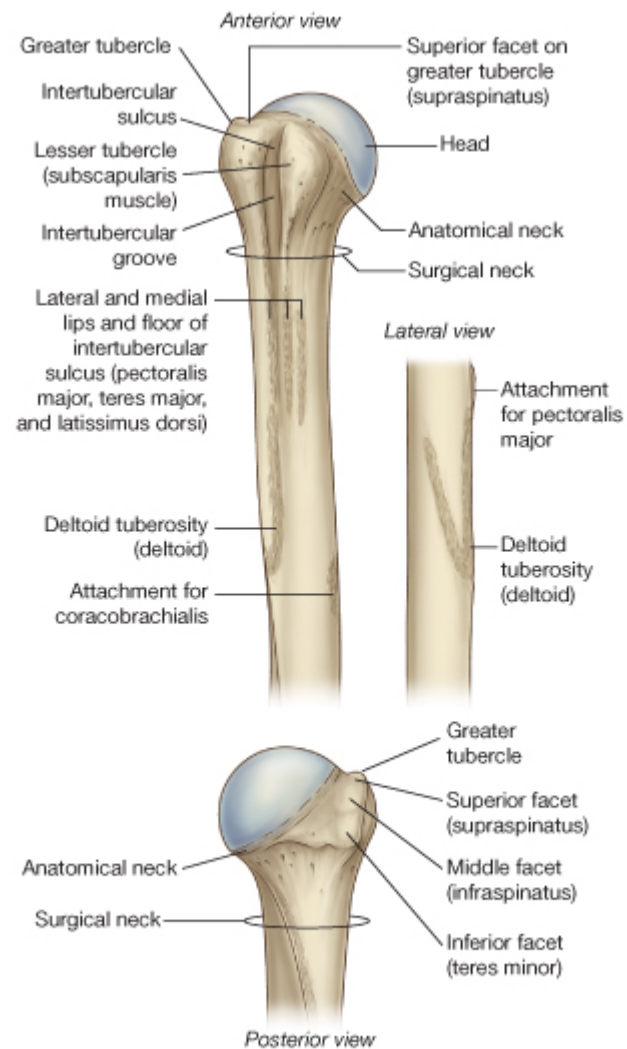
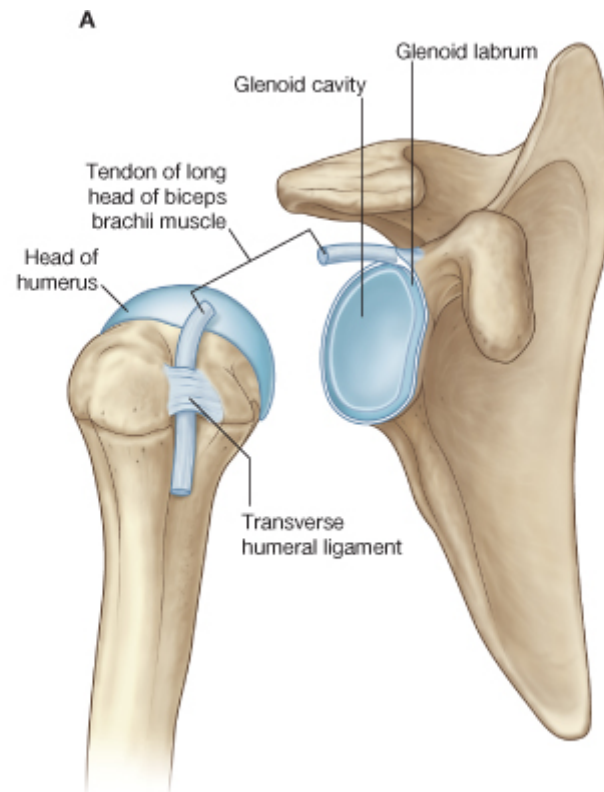


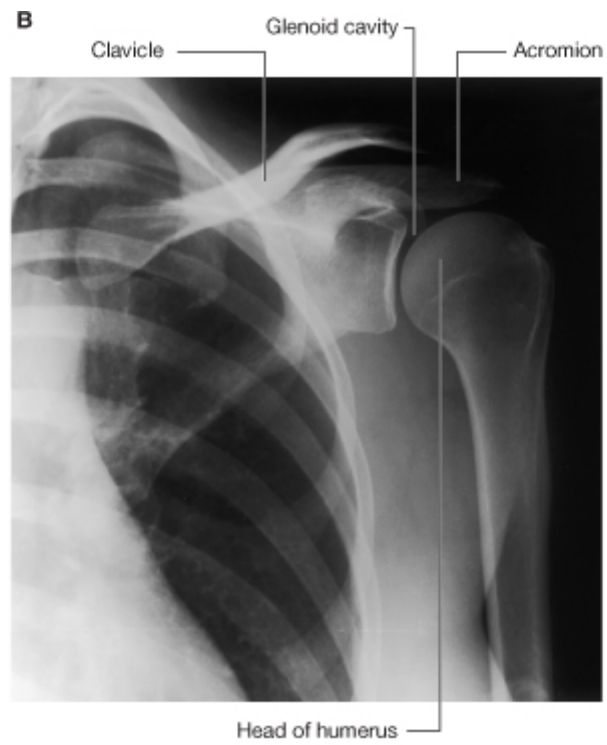
Shoulder joint



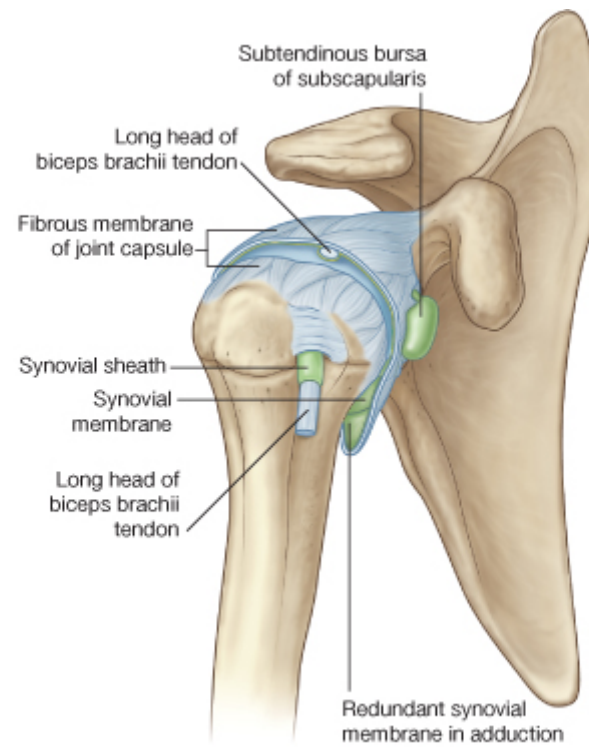


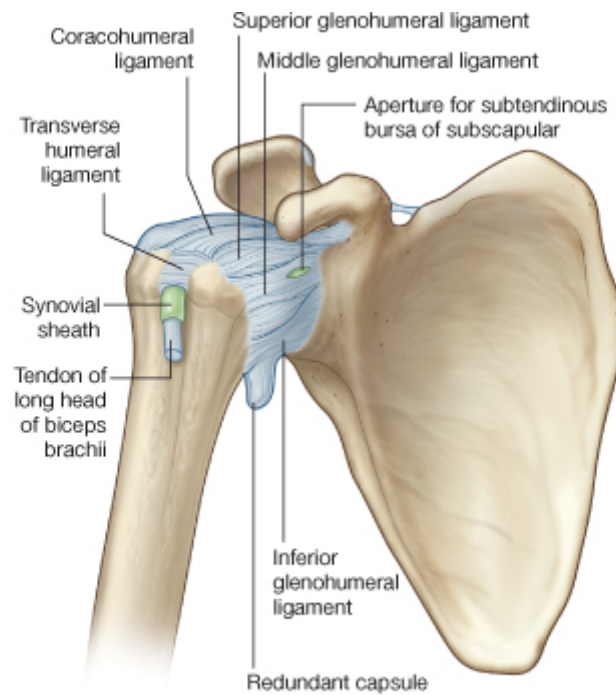


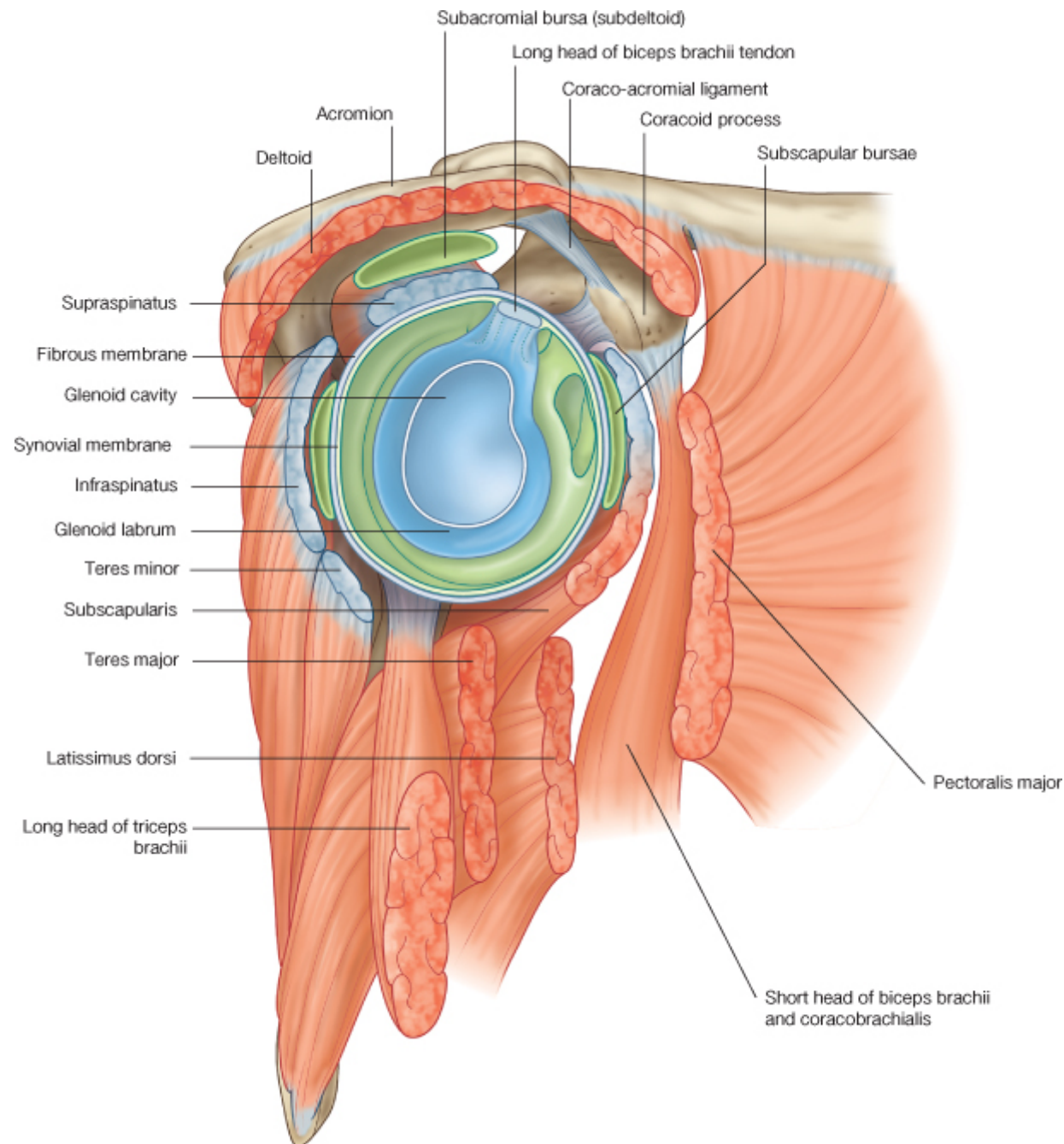




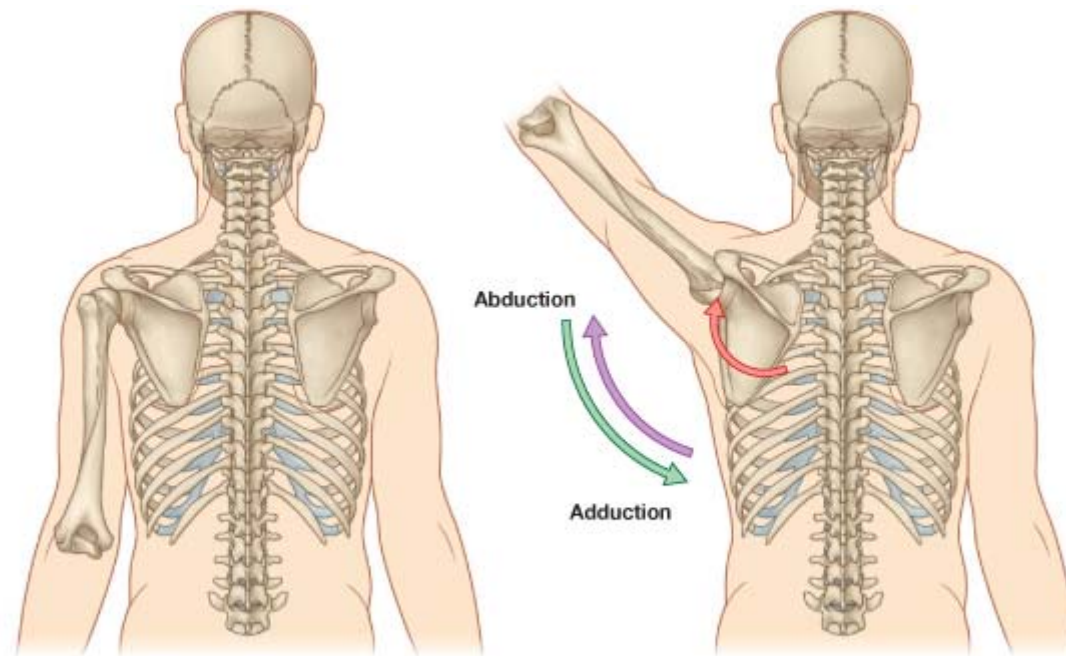
© Elsevier. Drake et al: Gray's Anatomy for Students - www.studentconsult.com



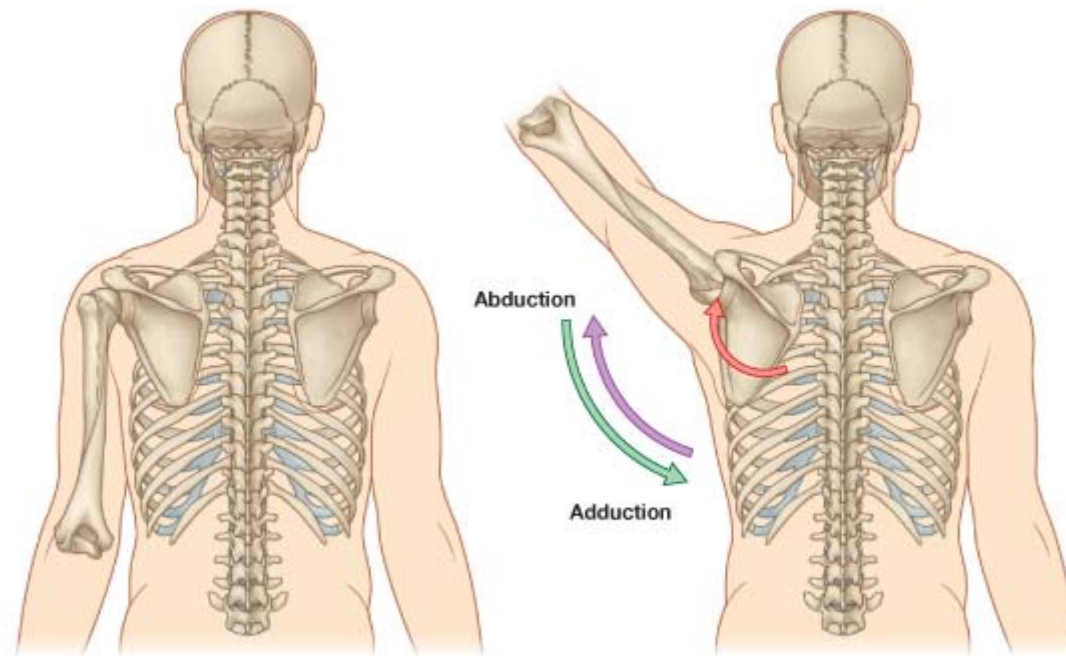




A



A



B

