
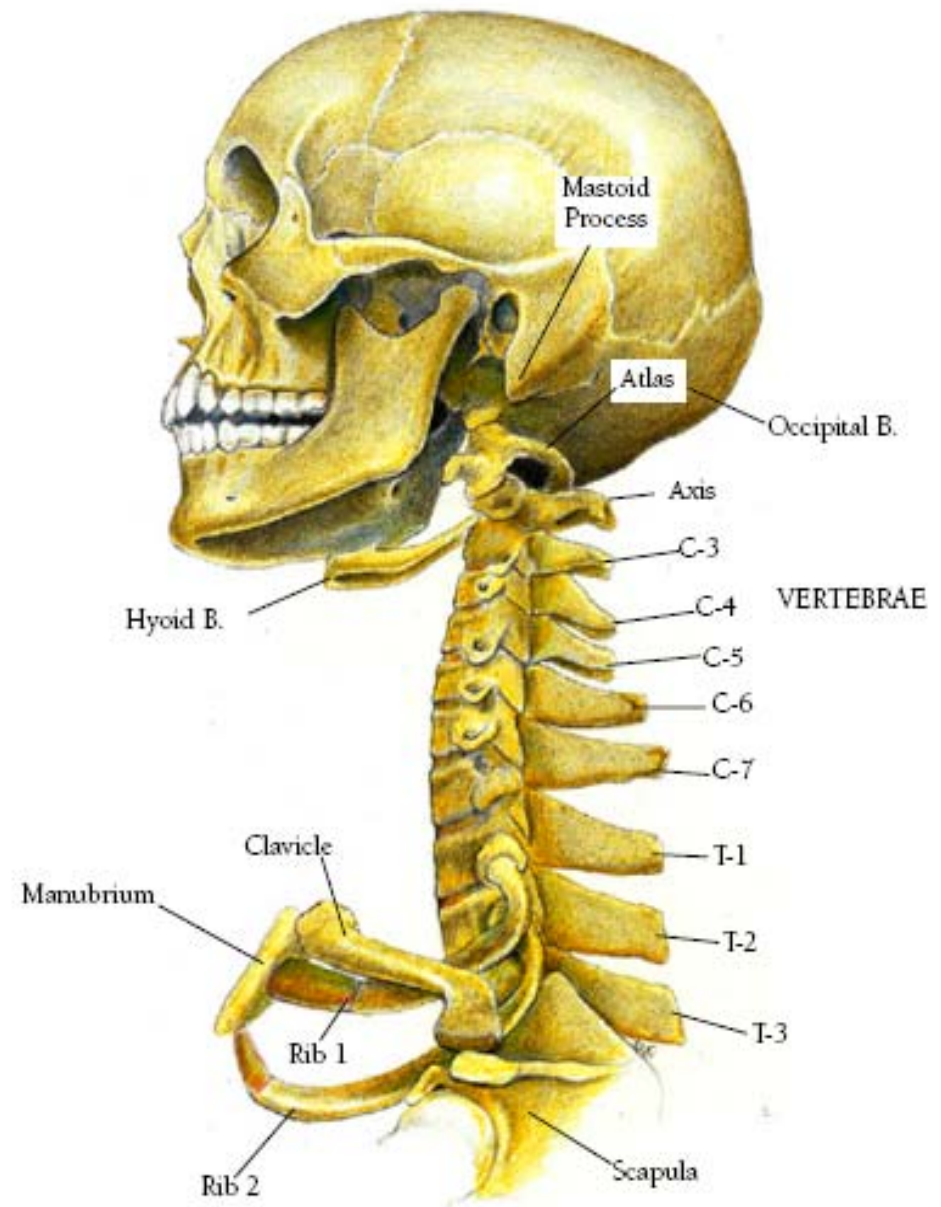


Anterior triangle



- The hyoid bone is situated at the angle of the throat where the chin meets the neck just above the thyroid cartilage—the Adam's Apple. It is the one bone in the body that is not articulated with another bone, rather it is held in place by the suprahyoid and infrahyoid muscles—those involved with swallowing.
- *Hyoid means shaped like the Greek letter upsilon: u. Oid at the end of a word means like, as in resemble.*



Anterior triangle

Boundres

Anteriorly→the midline of the neck

Posteriorly→anterior border of the SCM

Superiorly→lower border of the mandible

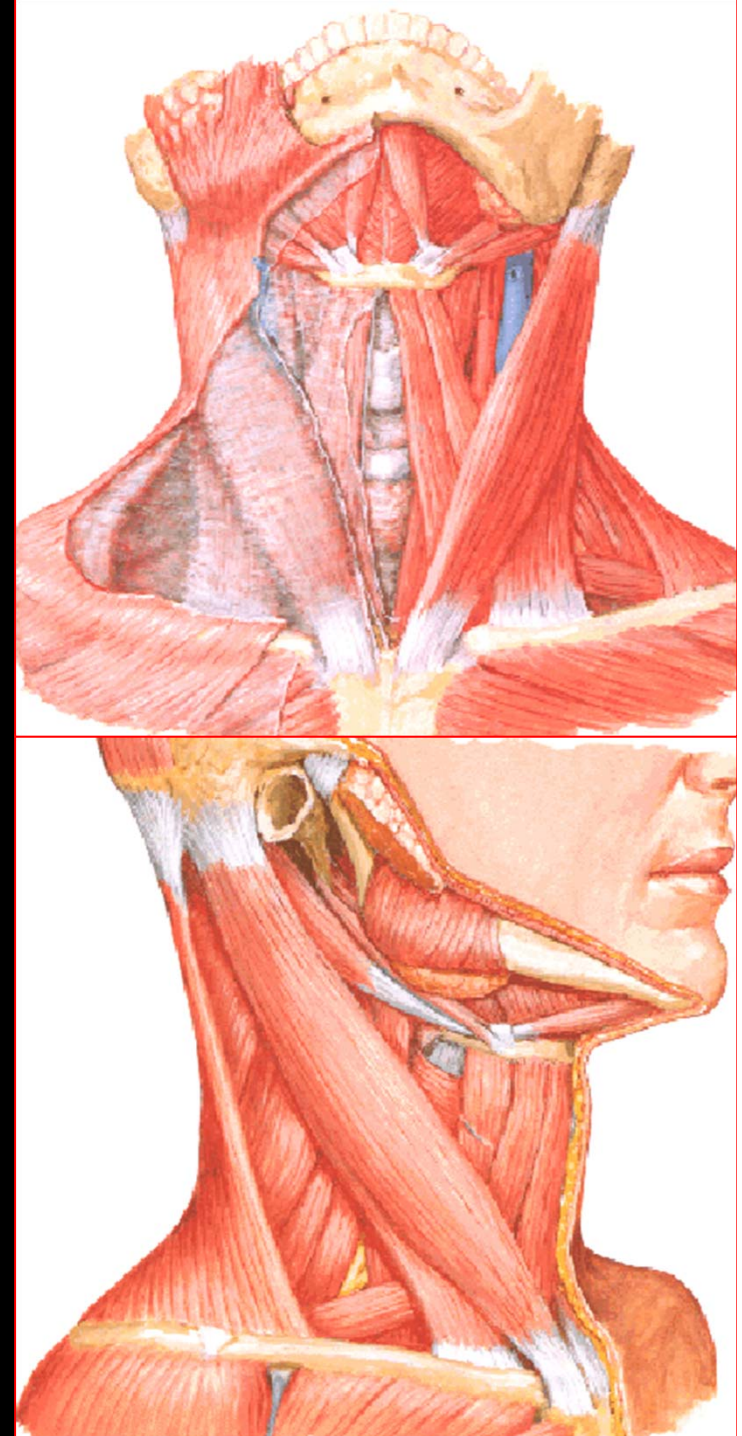
Roof

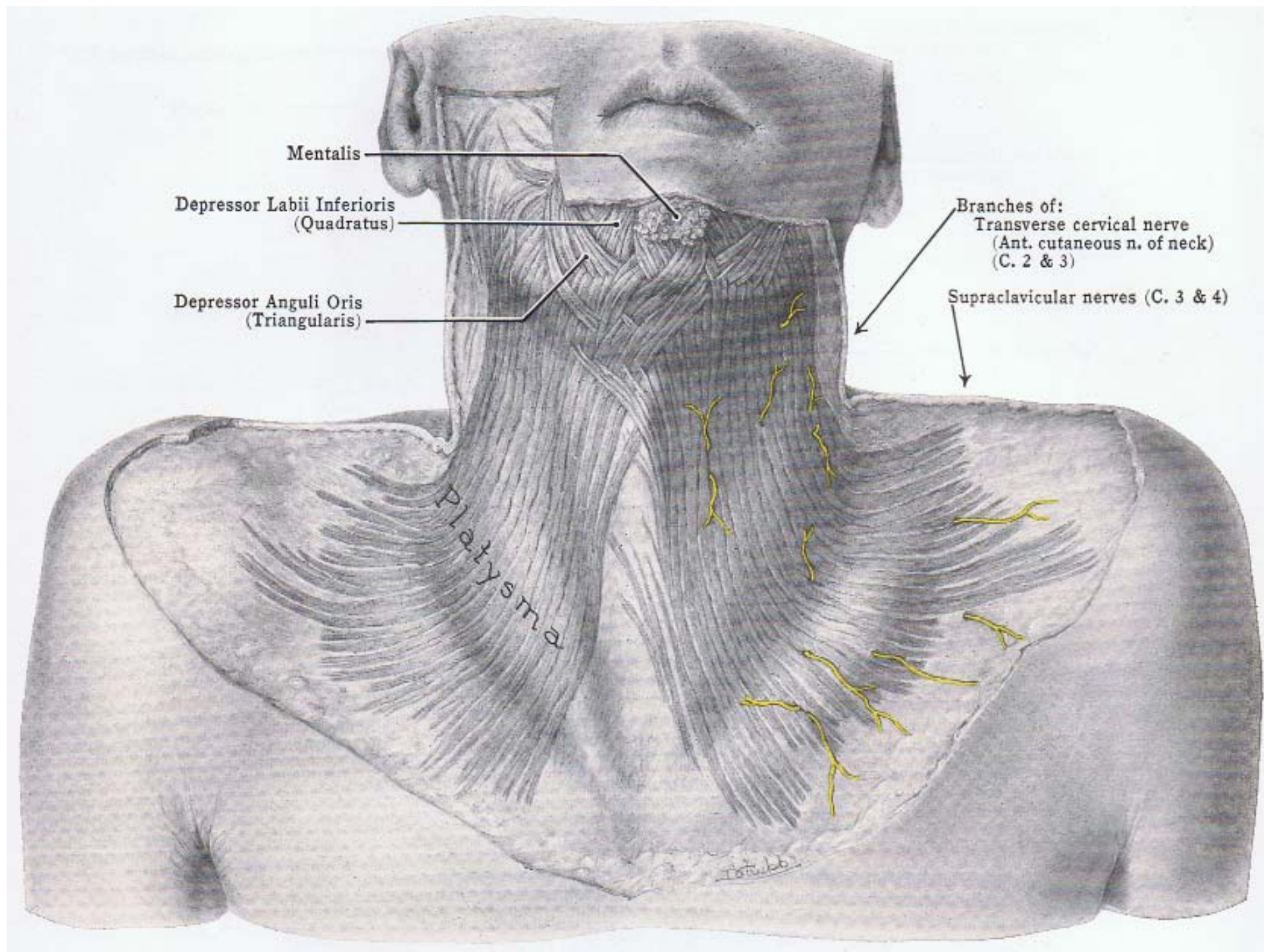
- skin
- superficial fascia
- platysma
- investing layer of deep fascia

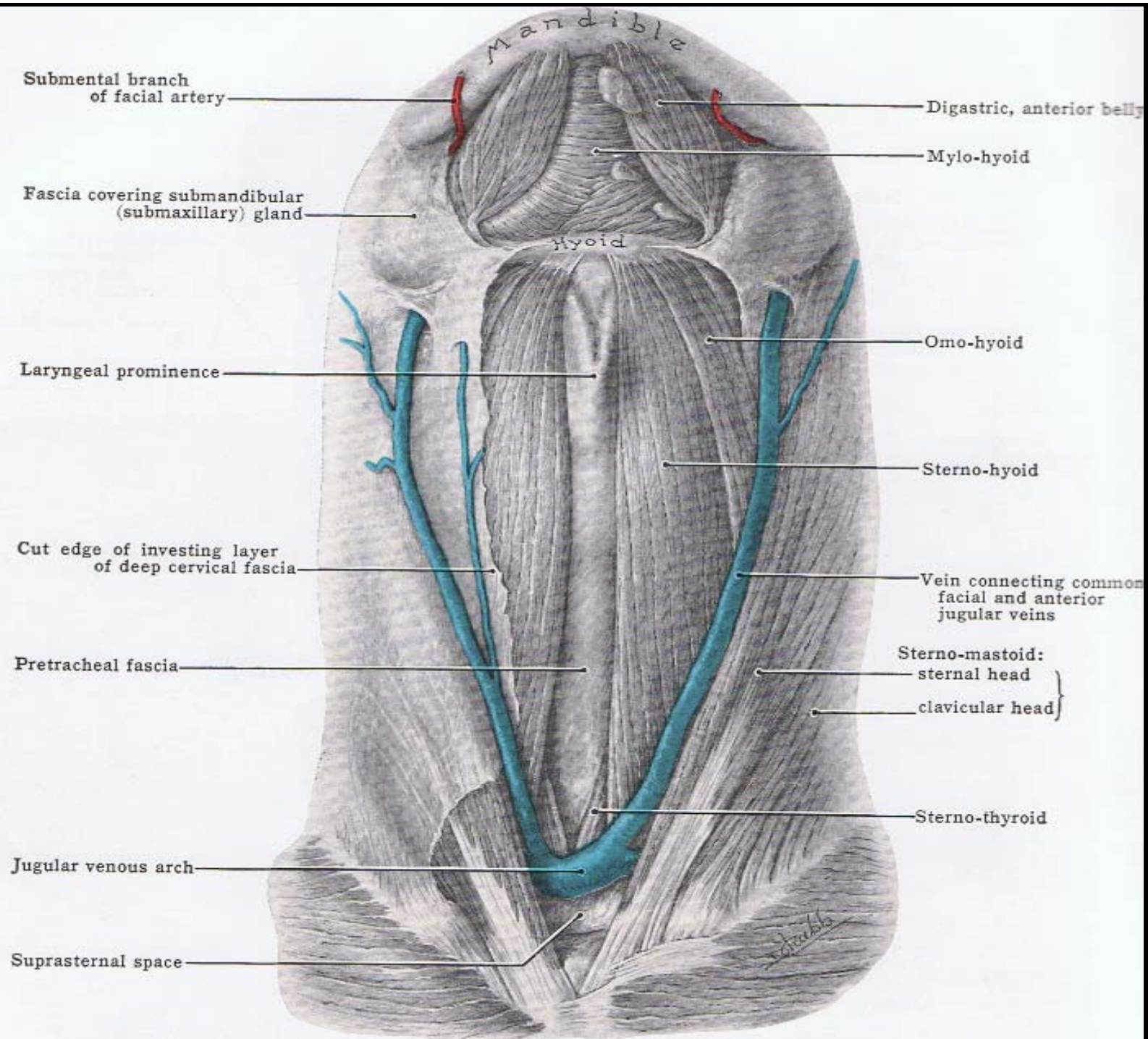
crossed by

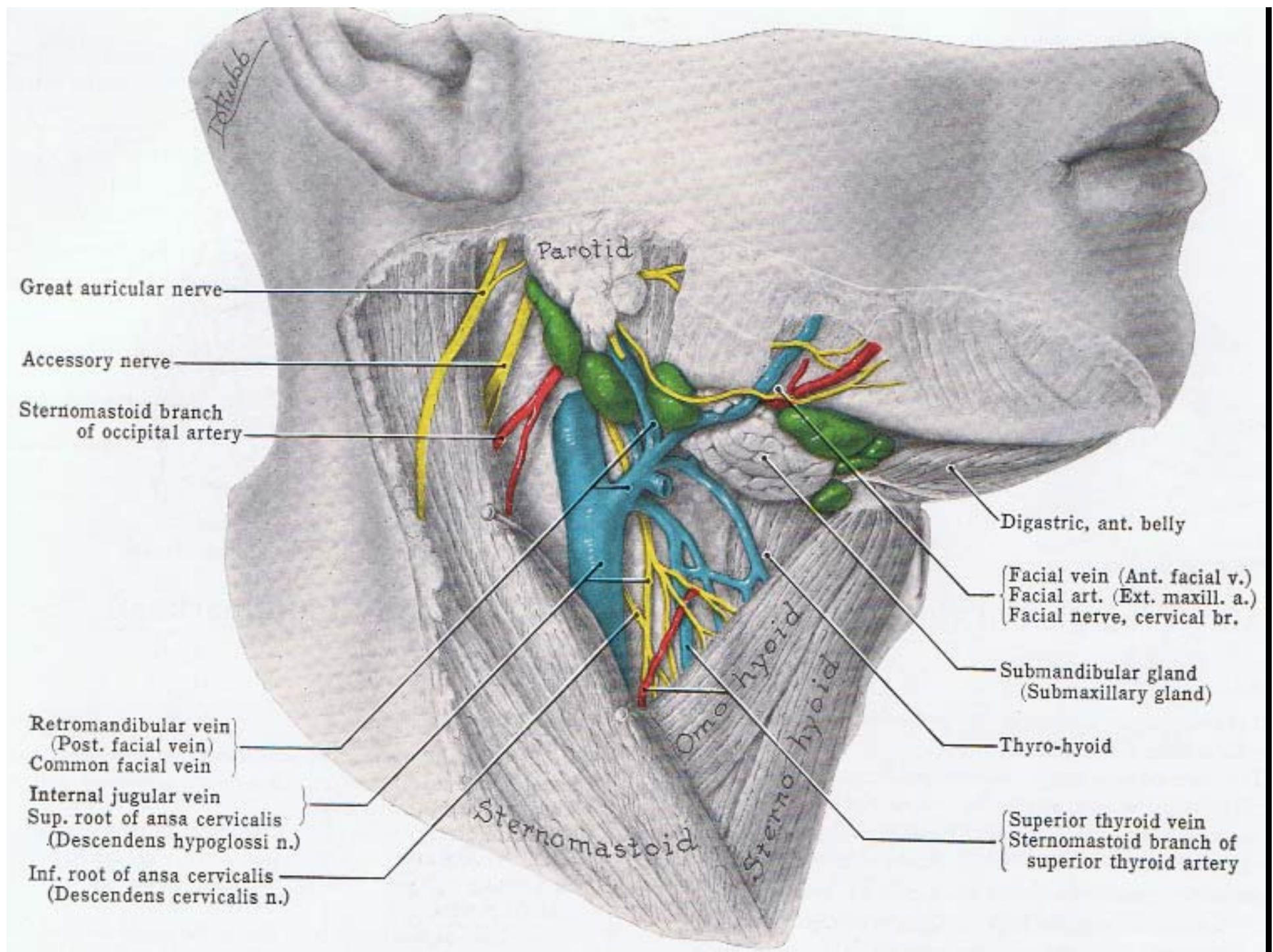
cervical branches of the facial nerve

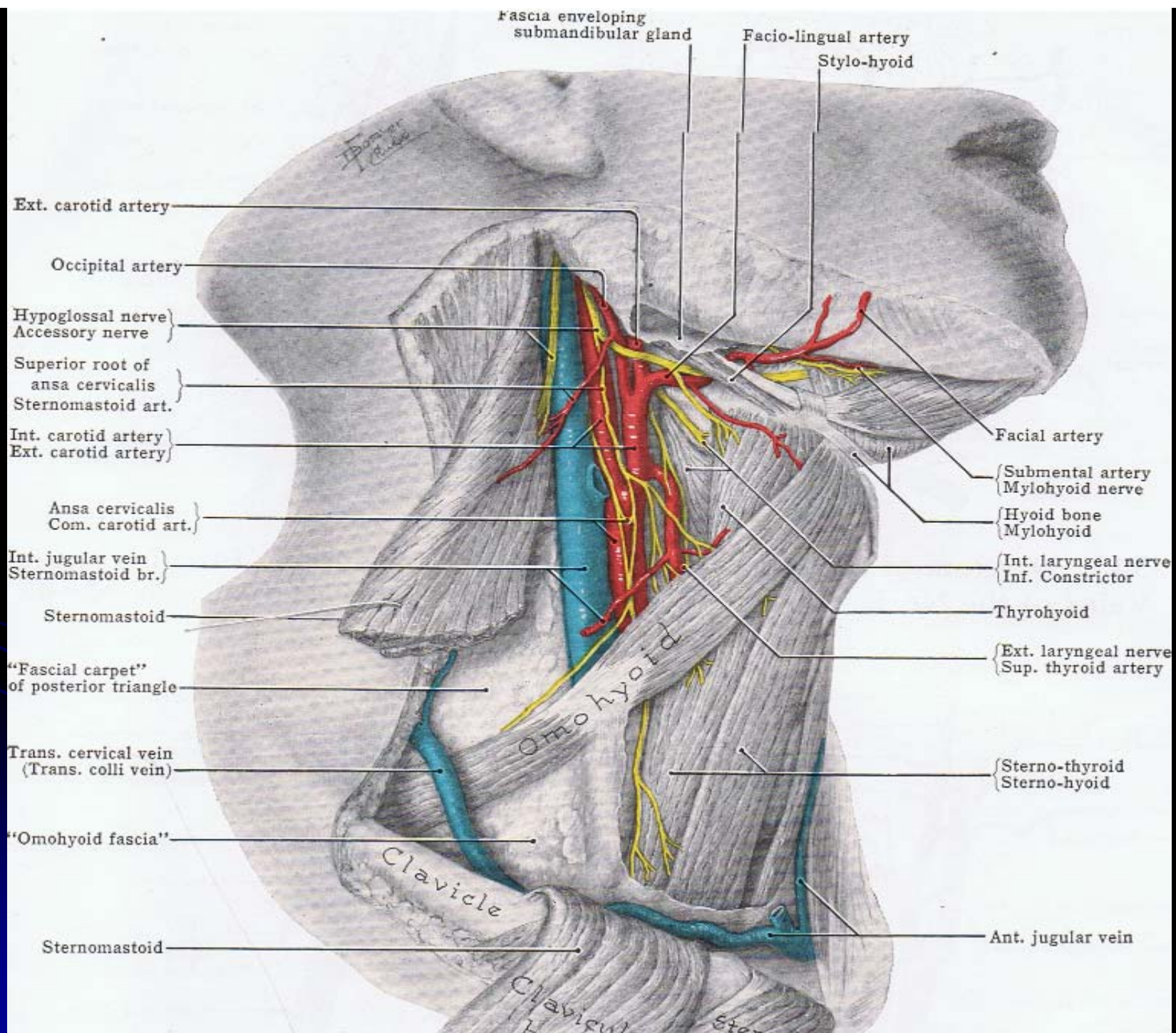
transverse cut.nerve(cervical plexus)





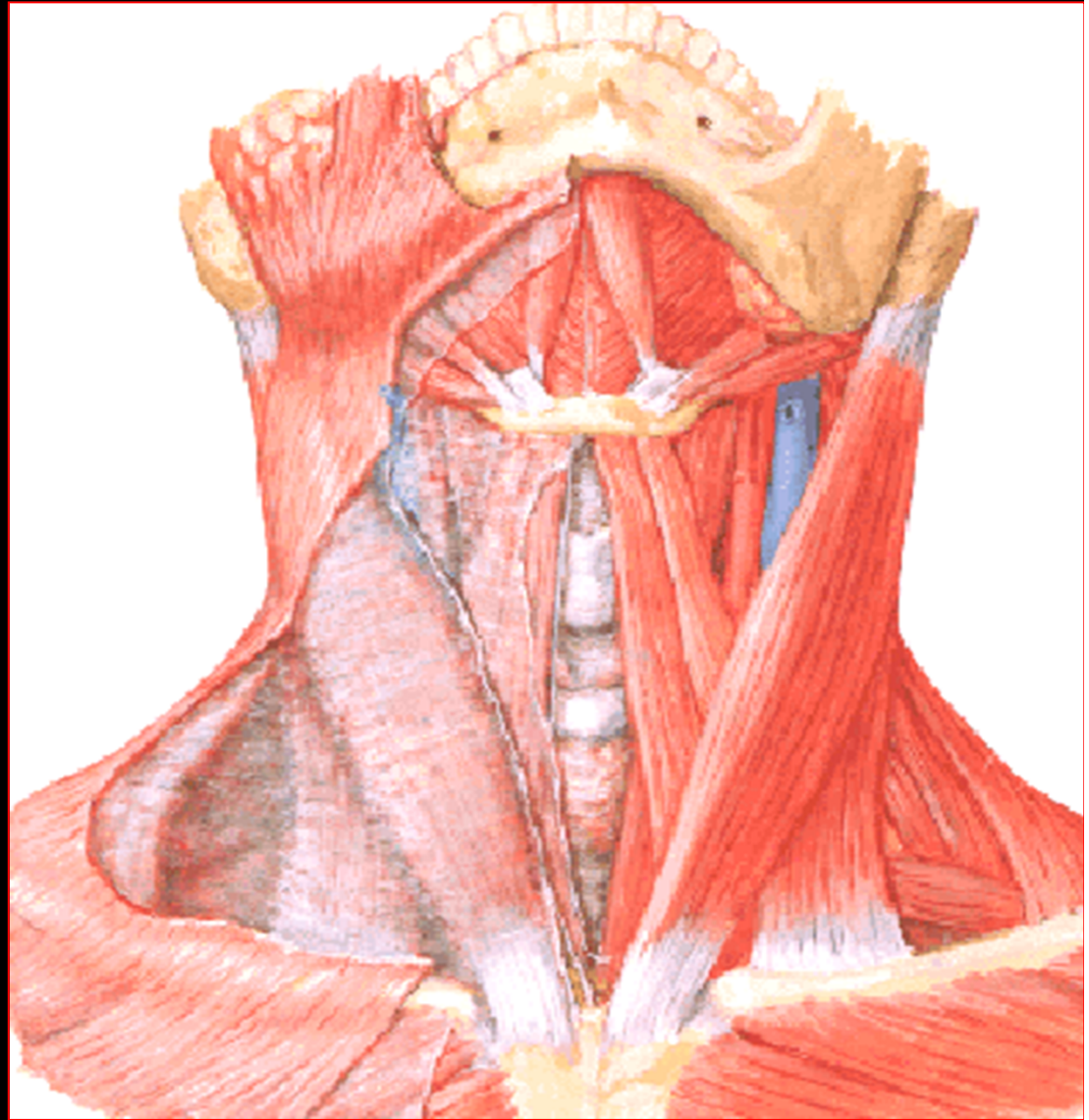
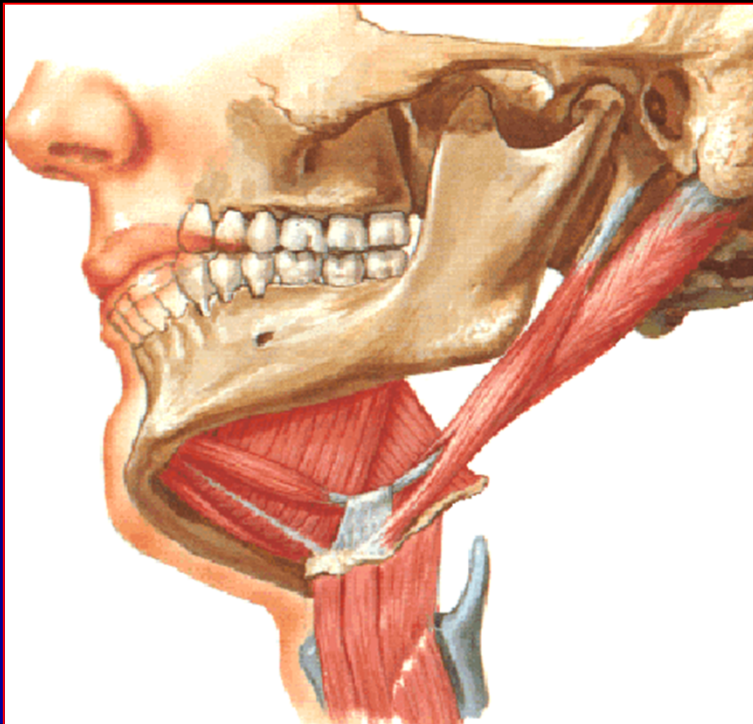






Is subdivided by The
1- digastric muscle
2- the sup.belly of the
omohyoid

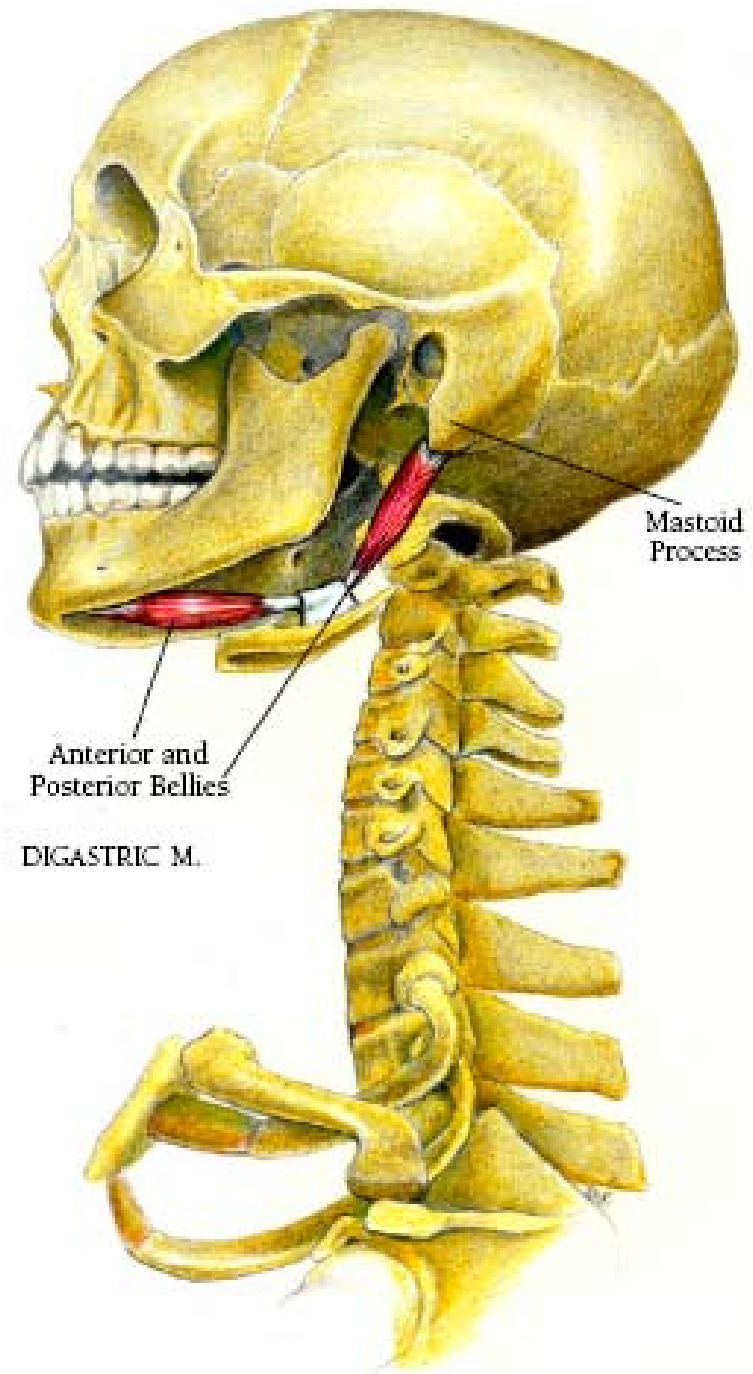
Into→ 4 triangles



Digastric muscle

The name digastric derives from the Greek *di*, meaning *two* and *gastēr*, meaning *bellies*.

The digastric muscle becomes tendinous in the middle so that it can go through a fibrous ring which is attached to the hyoid bone. It arises in the rear of the mastoid process, a bony process just below and behind the ear, slopes down and forward through its ring on the hyoid bone and then swings forward to insert on the inside of the chin on the mandible.



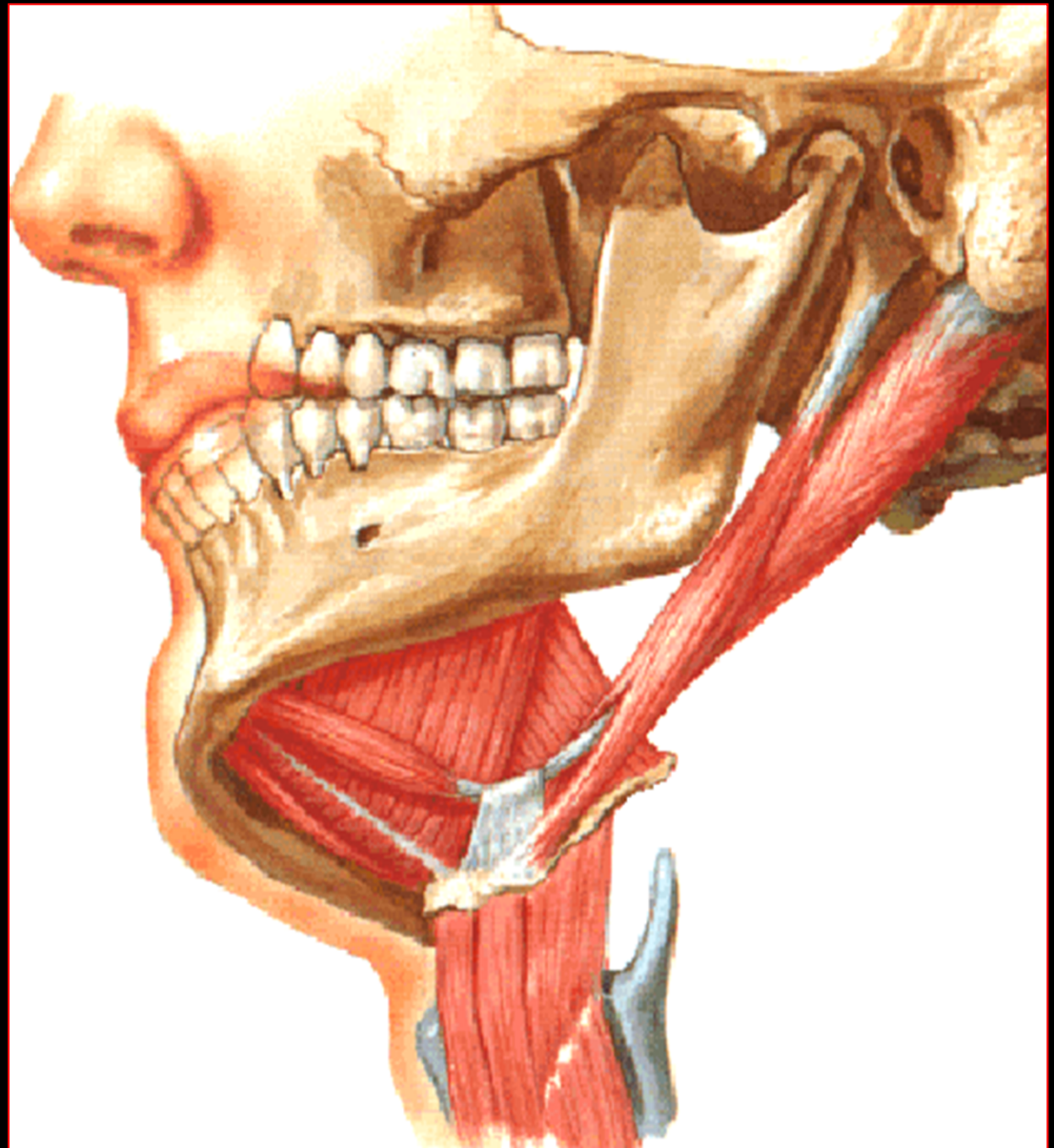
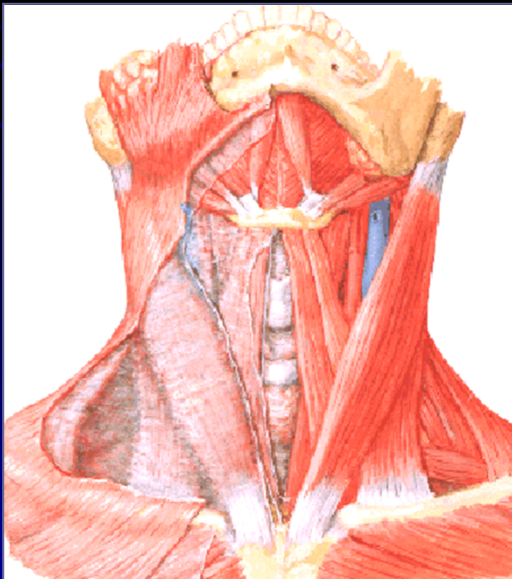
Digastric muscle

Nerve supply

- 1- post belly → facial nerve
- 2- ant.belly →
n.to the mylohyoid(br.of V3)

Action

- A-depresses the mandible
- B-elevate the hyoid bone

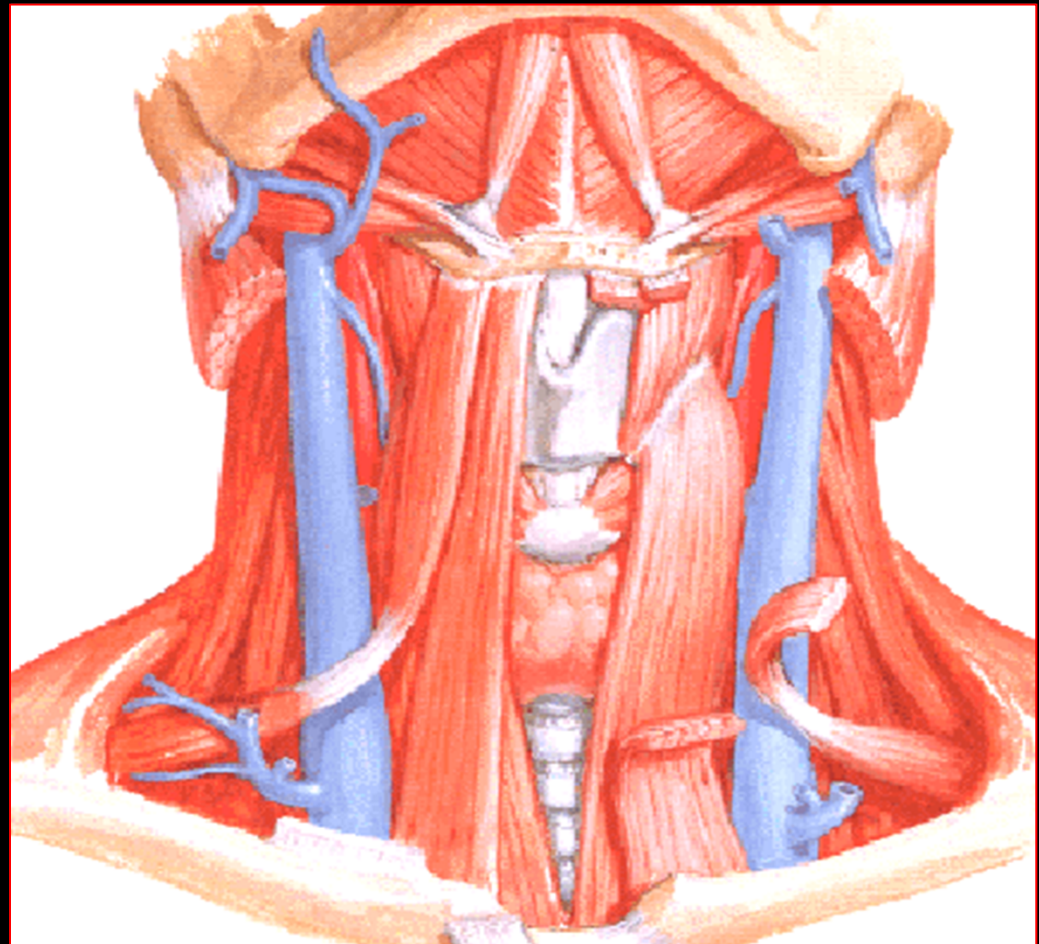
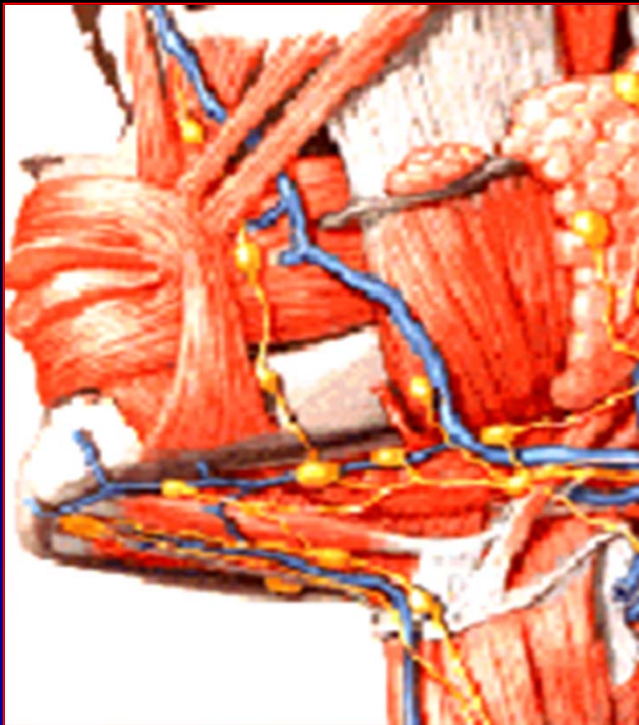

Submental Triangle

- **Medial** → midline of the neck
- **Lateral** → ant. belly of the digastric muscle
- **Inferior** → body of the hyoid bone
- **Floor** → mylohyoid muscle

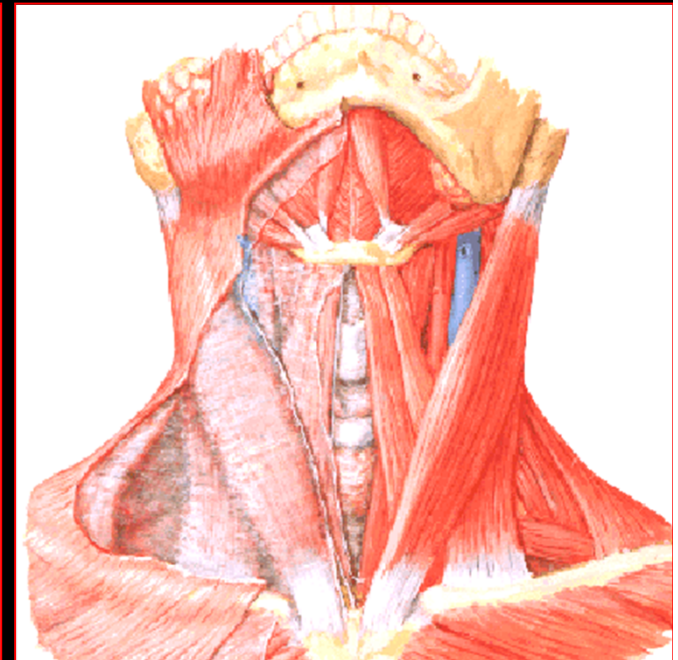
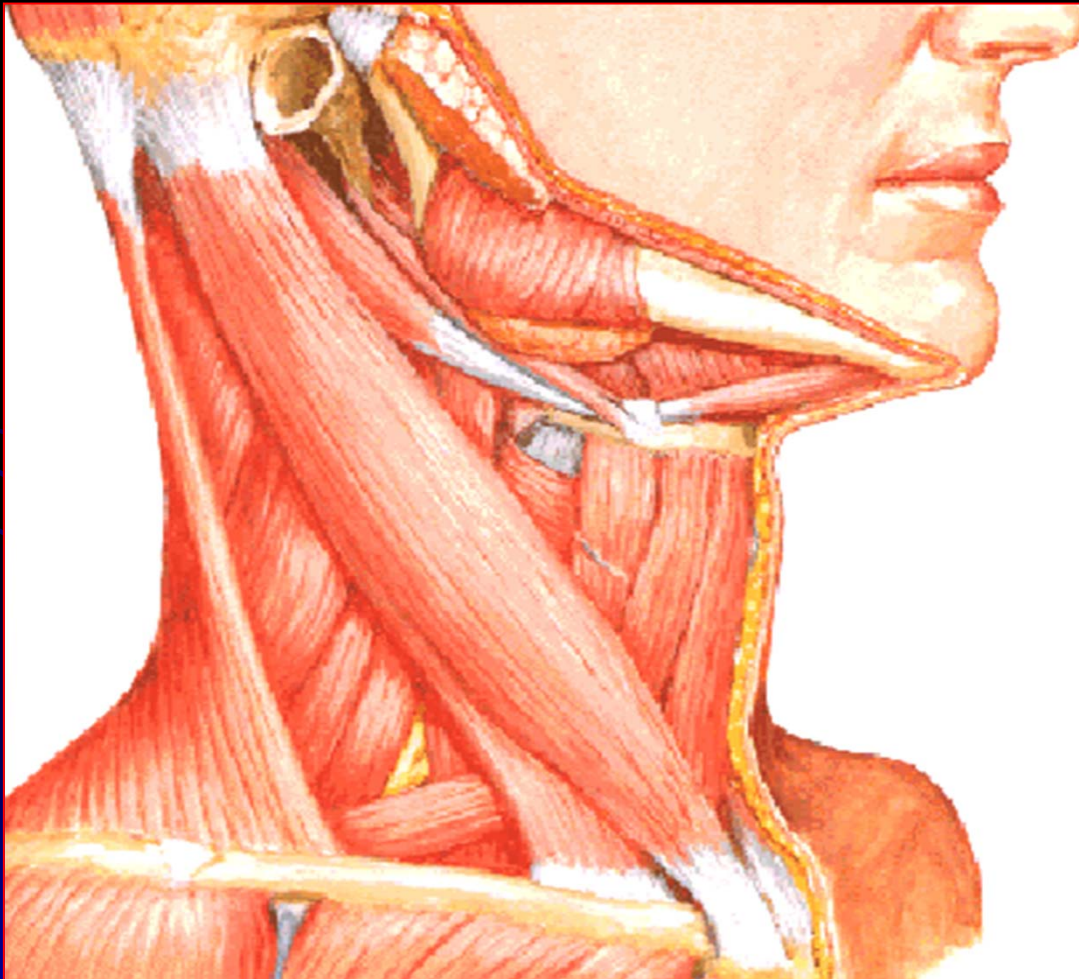
Contains

- Submental LNs
- ant. jugular v



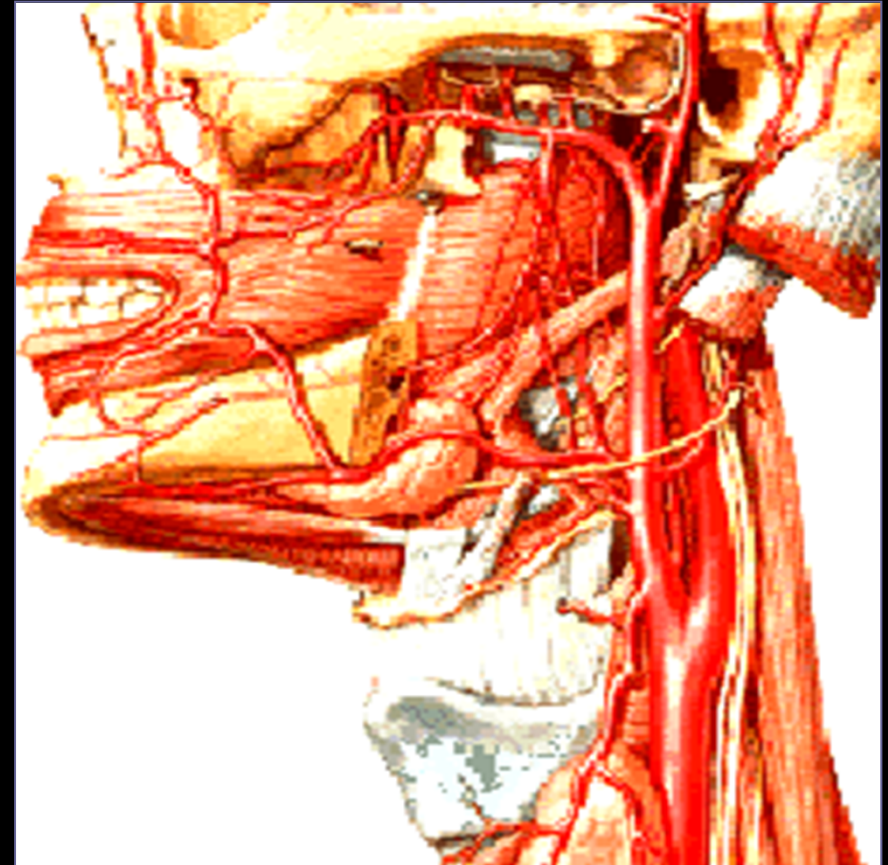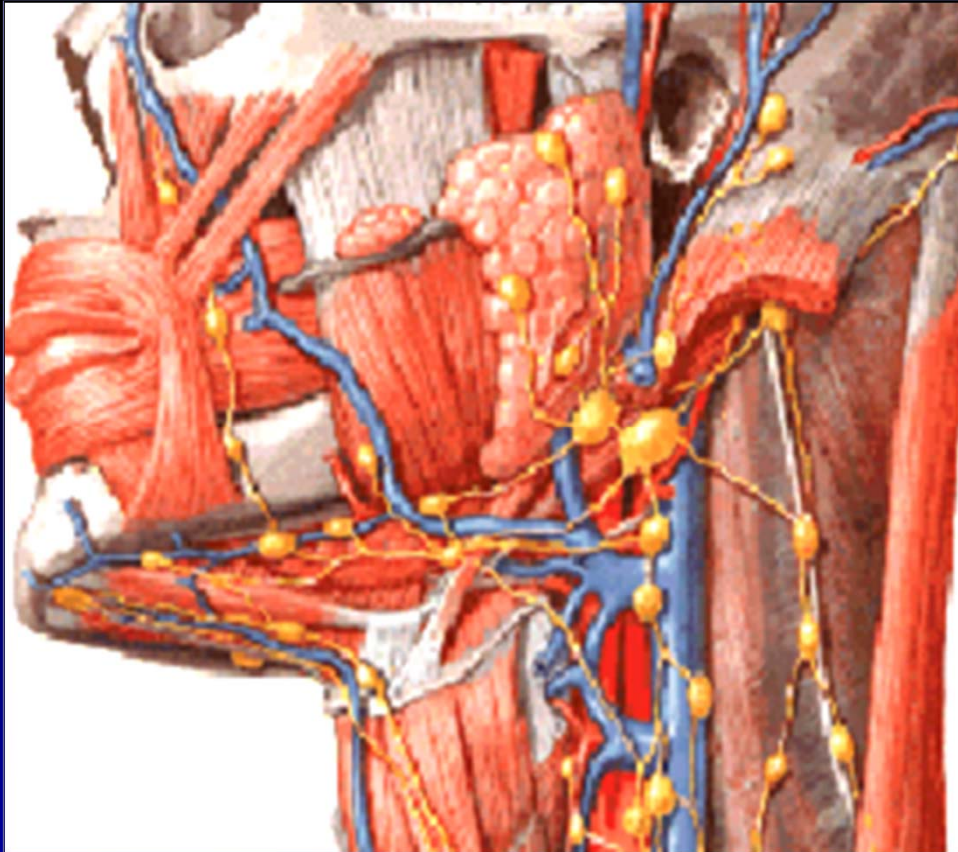
Digastric triangle (submandibular)

- Anterior → ant. belly of the digastric muscle
- Posterior → post. belly of DGM + stylohyoid muscle
- Superior → lower border of the mandible
- Floor → mylohyoid - hypoglossus muscles



Contents

- 1- submandibular salivary gland (superficial part)
- 2- facial artery (deep to the gland)
- 3- facial vein (superficial to the gland)
- 4- submandibular LNs (superficial to it)
- 5- hypoglossal nerve (deep to the gland and on the hyoglossus m)



Swelling in the submandibular triangle

- Enlarged LN (tumor of the tongue)
- Enlarged submand.g (calculus or tumor)
- Surgery risks the following
 - Mandibular branch of the facial n
 - Cervical branch of the facial n

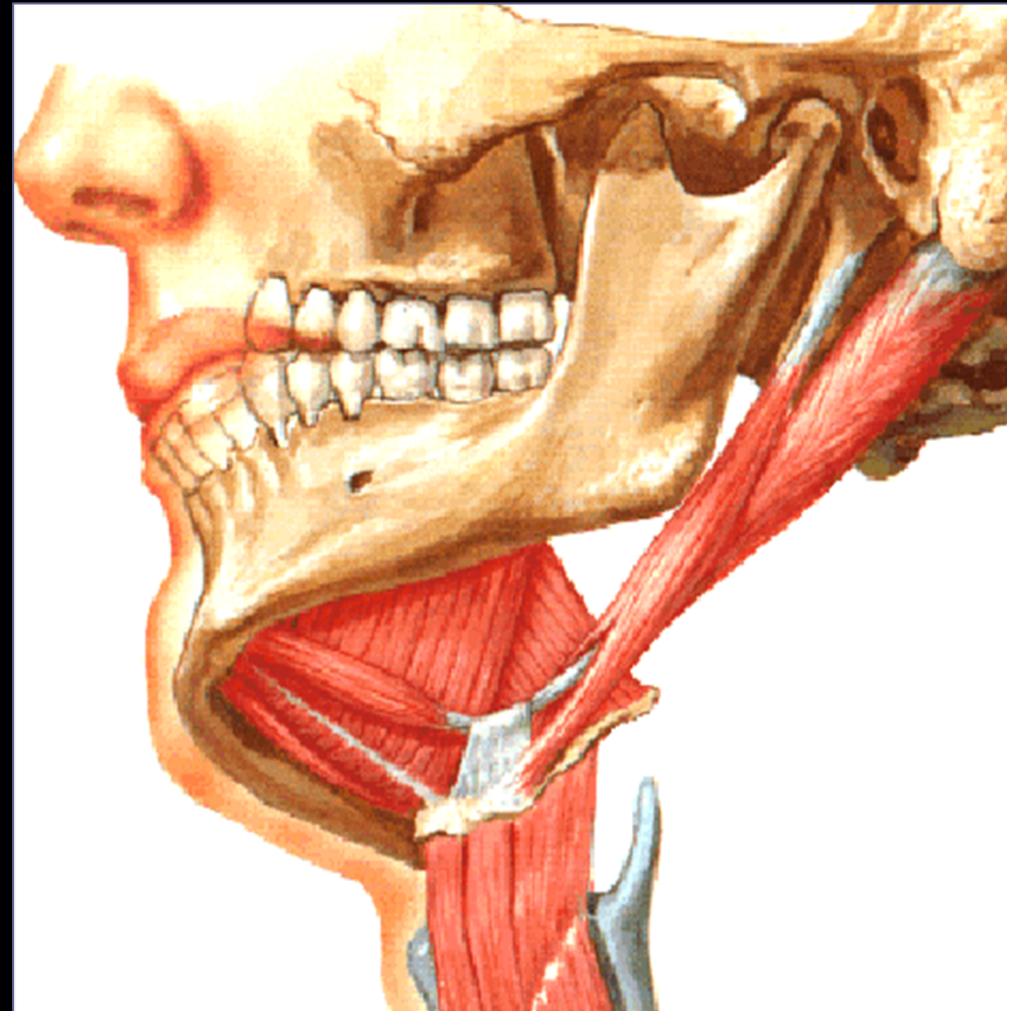
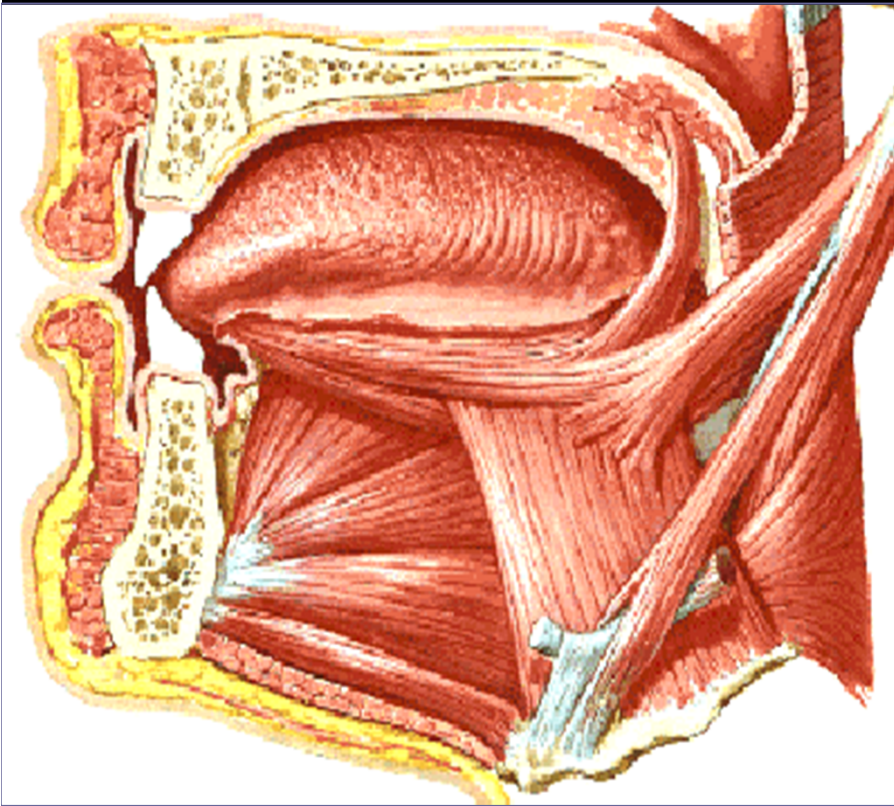
Stylohyoid muscle

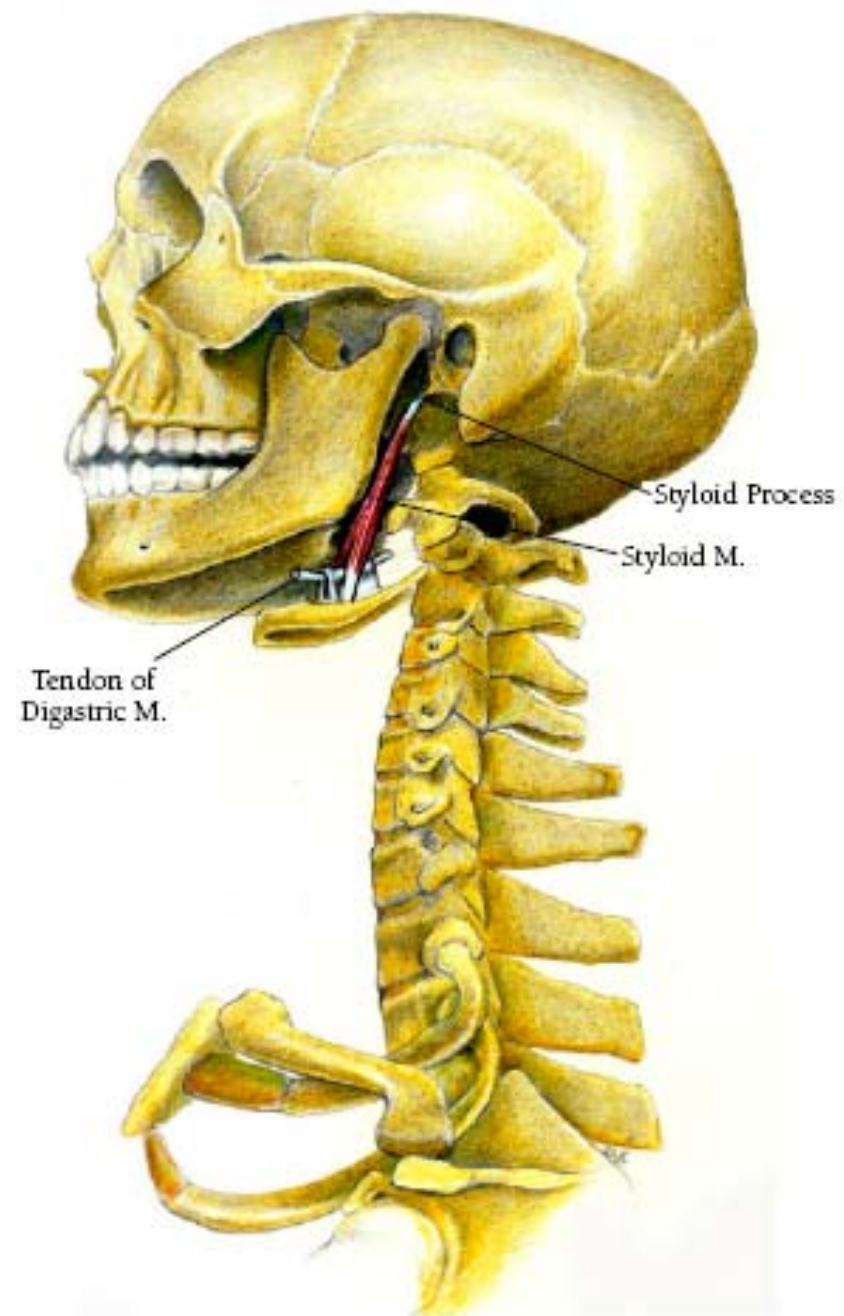
Styloid derives from the Latin word for pointed and refers to the shape of the bone.

Attachment → Styloid process → hyoid bone

Nerve supply → facial nerve

Action → elevates the hyoid bone





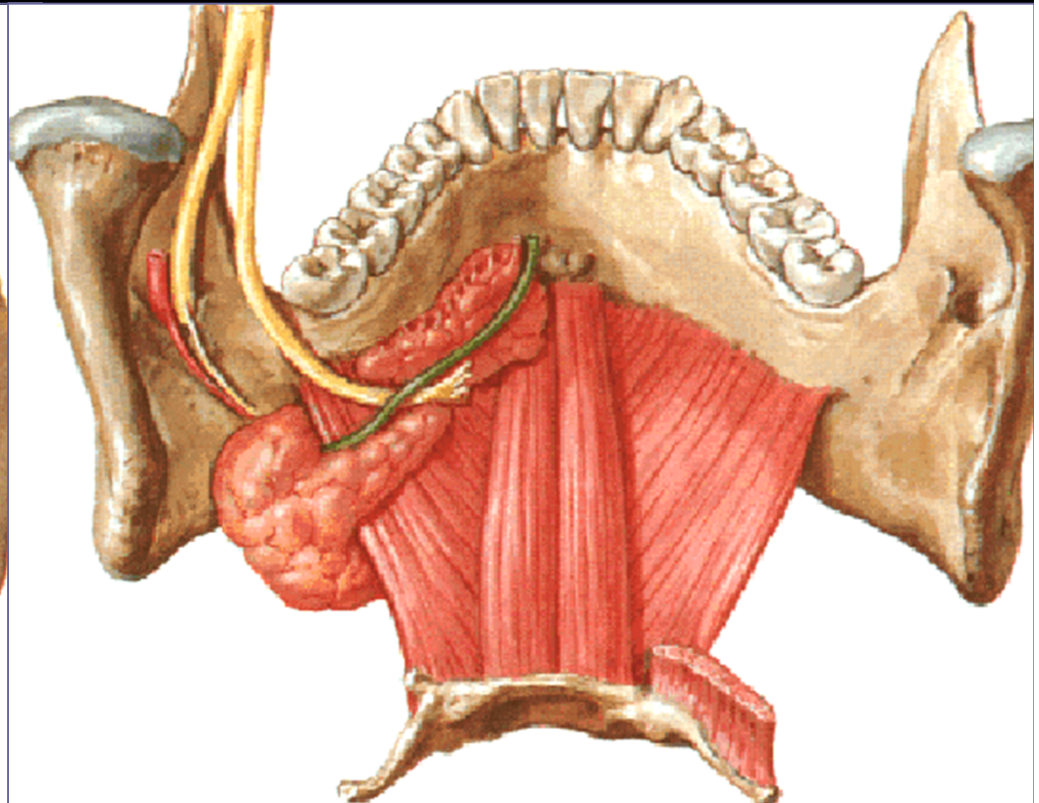
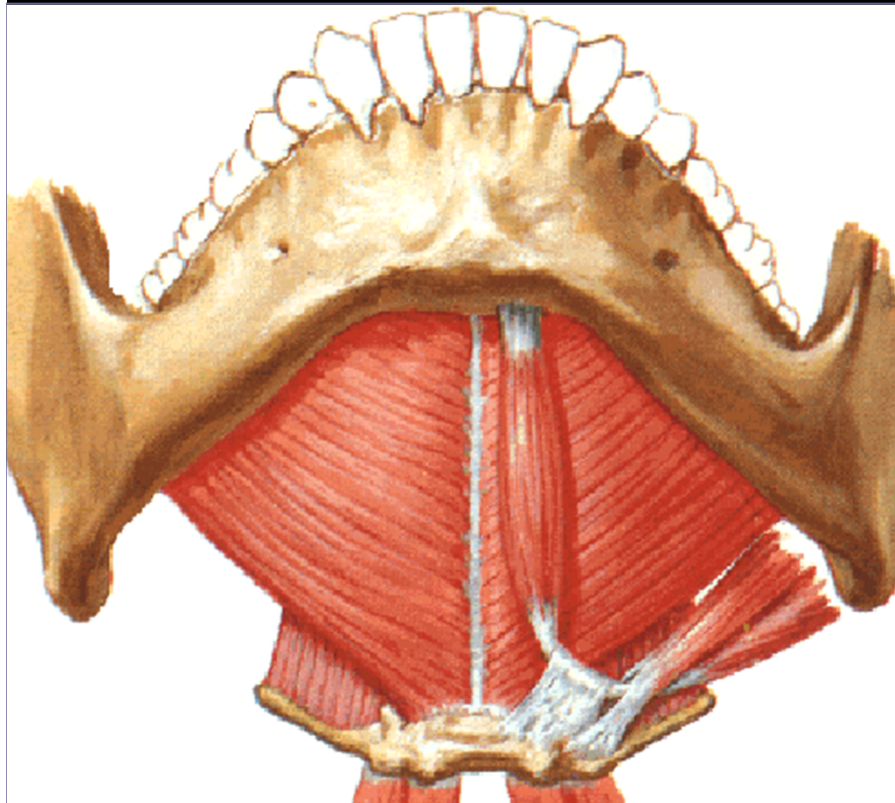
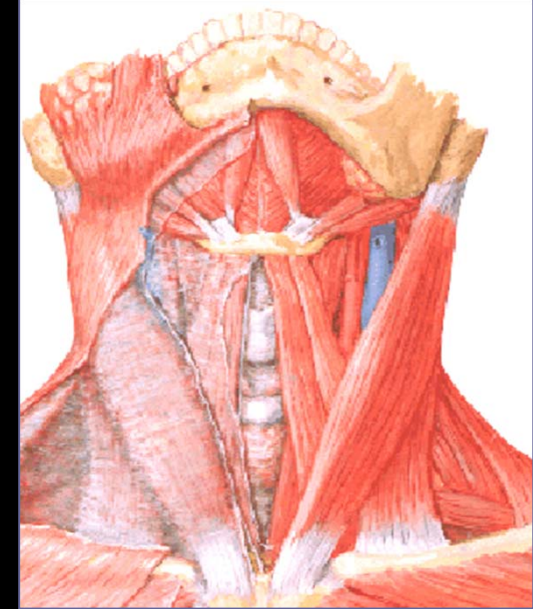
Mylohyoid muscle

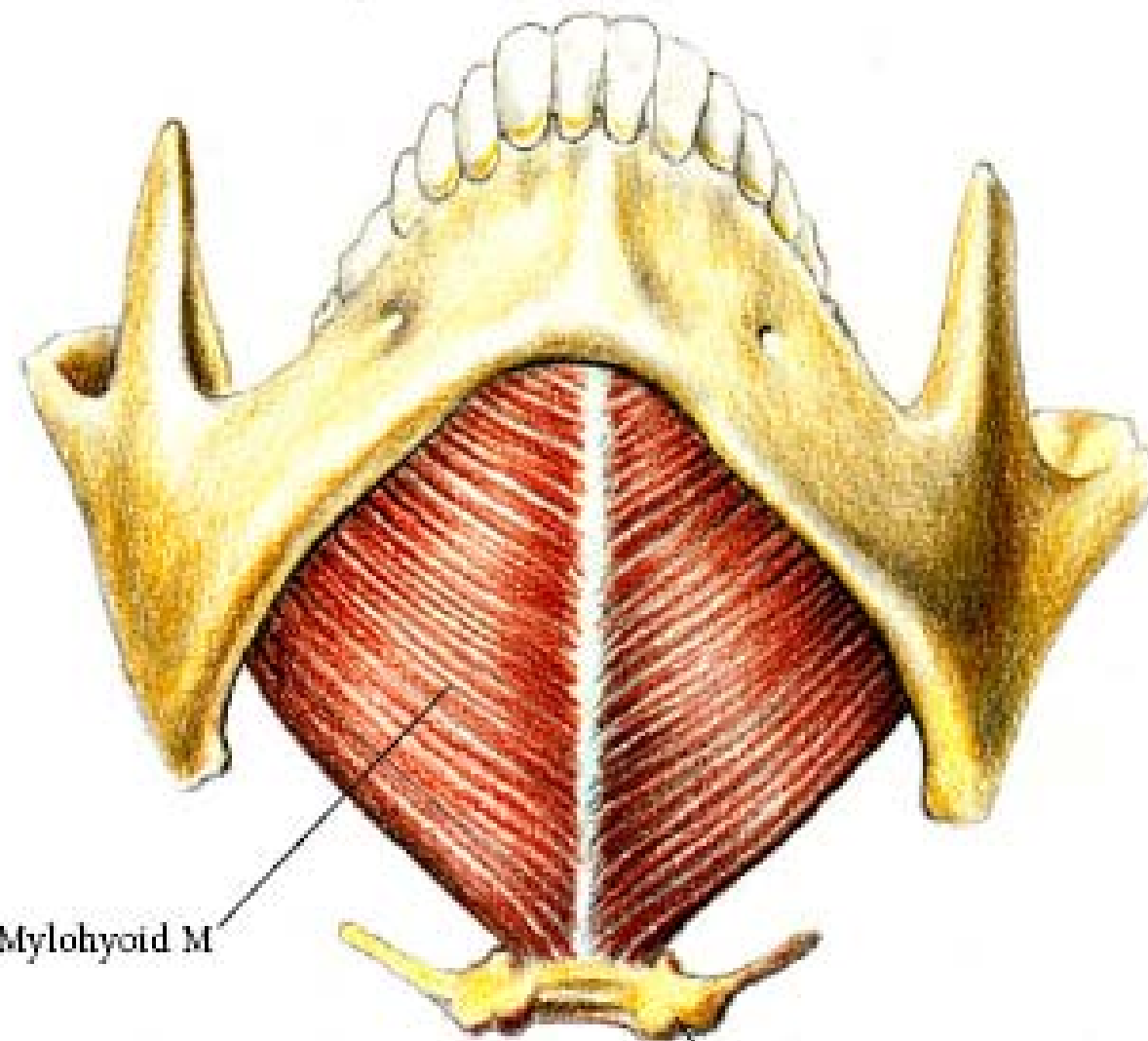
Mylo is the Greek word for mill, a place where grinding is done and hence relates to the molars.

Attachment → body of the mandible (mylohyoid line) → hyoid bone

NS → n. to mylohyoid m (br. V3, inferior alveolar nerve)

Action → elevates floor of the mouth and hyoid bone- depresses the mandible





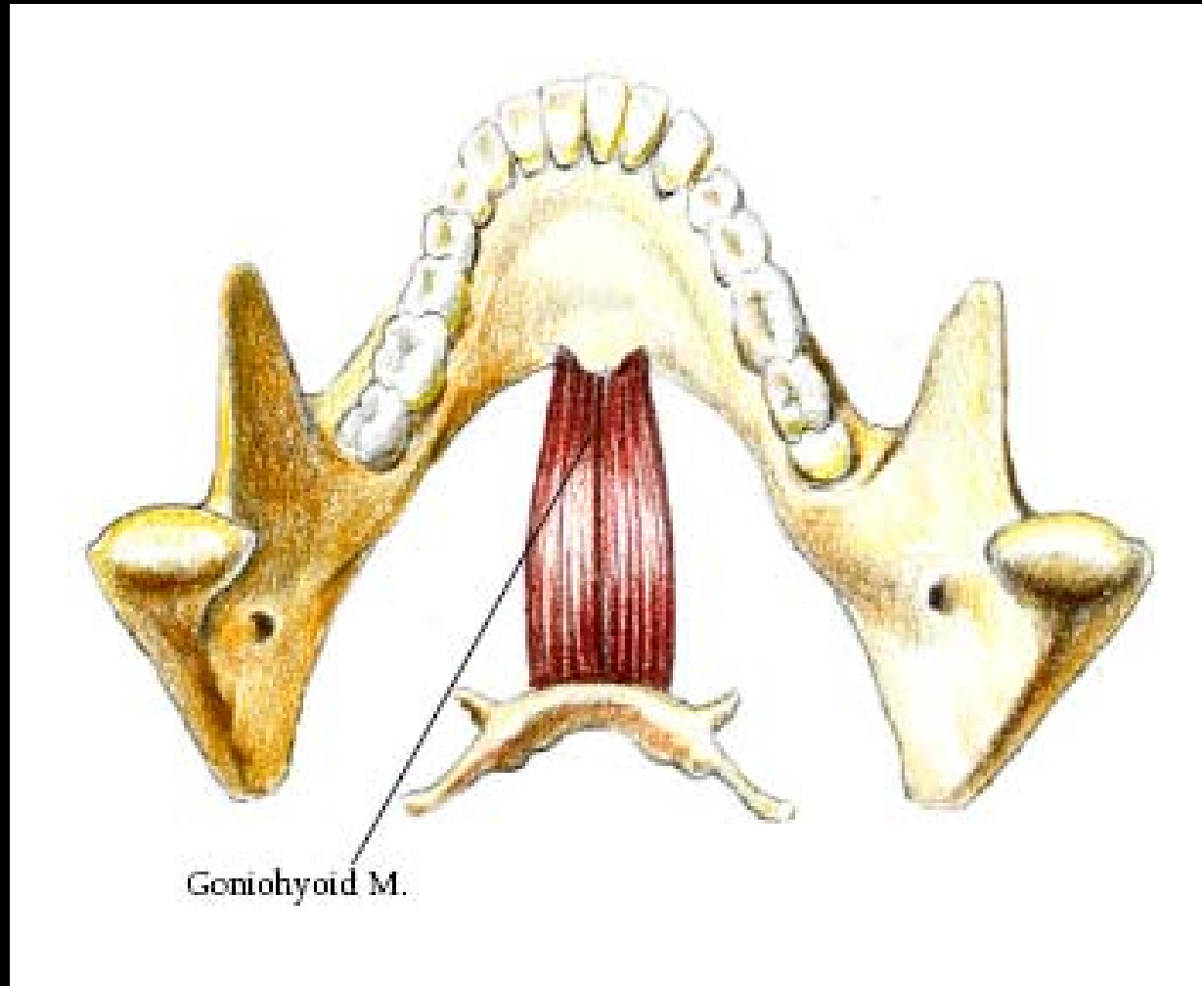
Mylohyoid M

Hyoid B.

GONIOHYOID MUSCLE

Gonio is the Greek word for angle, and refers here to the angle of the lower jaw.

The goniohyoid muscle, which lies beneath the mylohyoid muscle, arises from behind the point of the chin and inserts on the body of the hyoid bone.



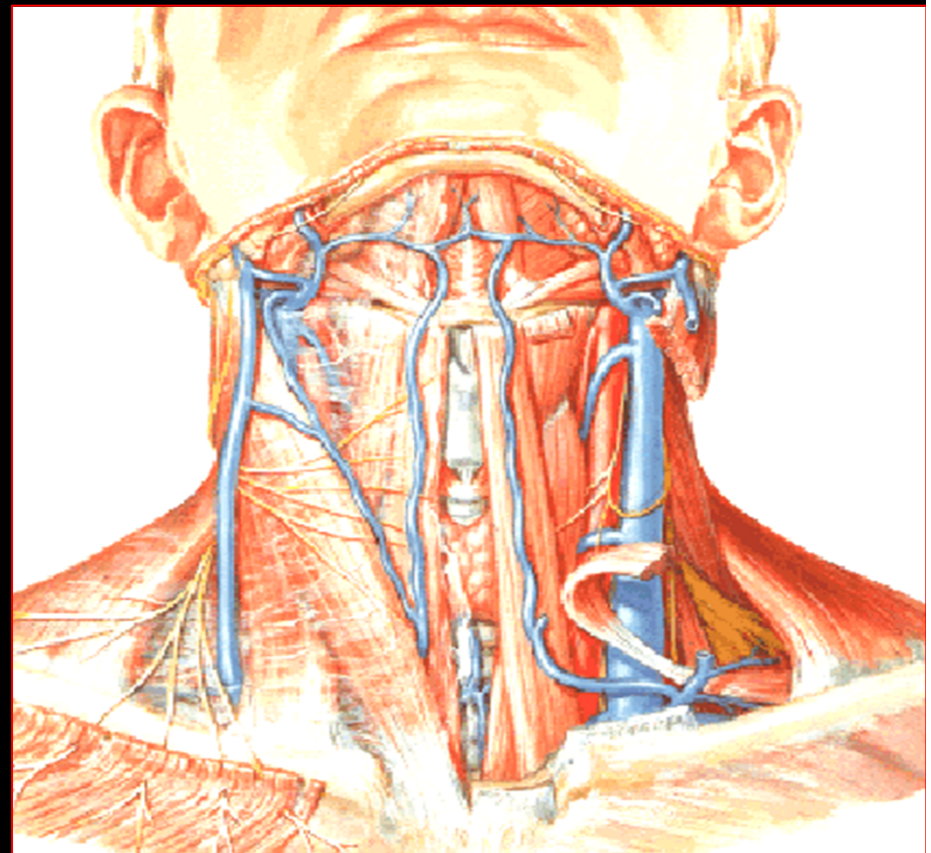
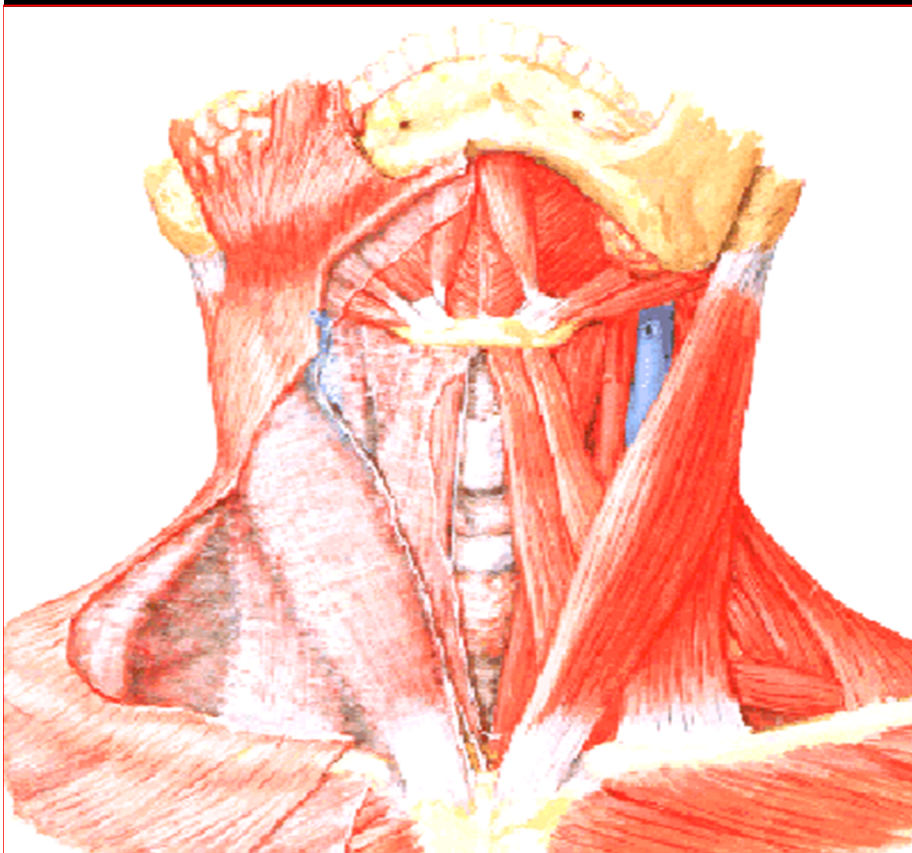
Muscular triangle

- Anterior →midline of the neck
- Superior→sup. Belly of the omohyoid m.
- Inferior→ant. Border of the SCM

Ant jugular v runs in fascia superficial to triangle

contains

- 1-anterior jugular vein
- 2-infrahyoid muscles
- 3- beneath the floor →thyroid gland-larynx –trachea-esophagus



The Infrahyoid muscles

They lie over

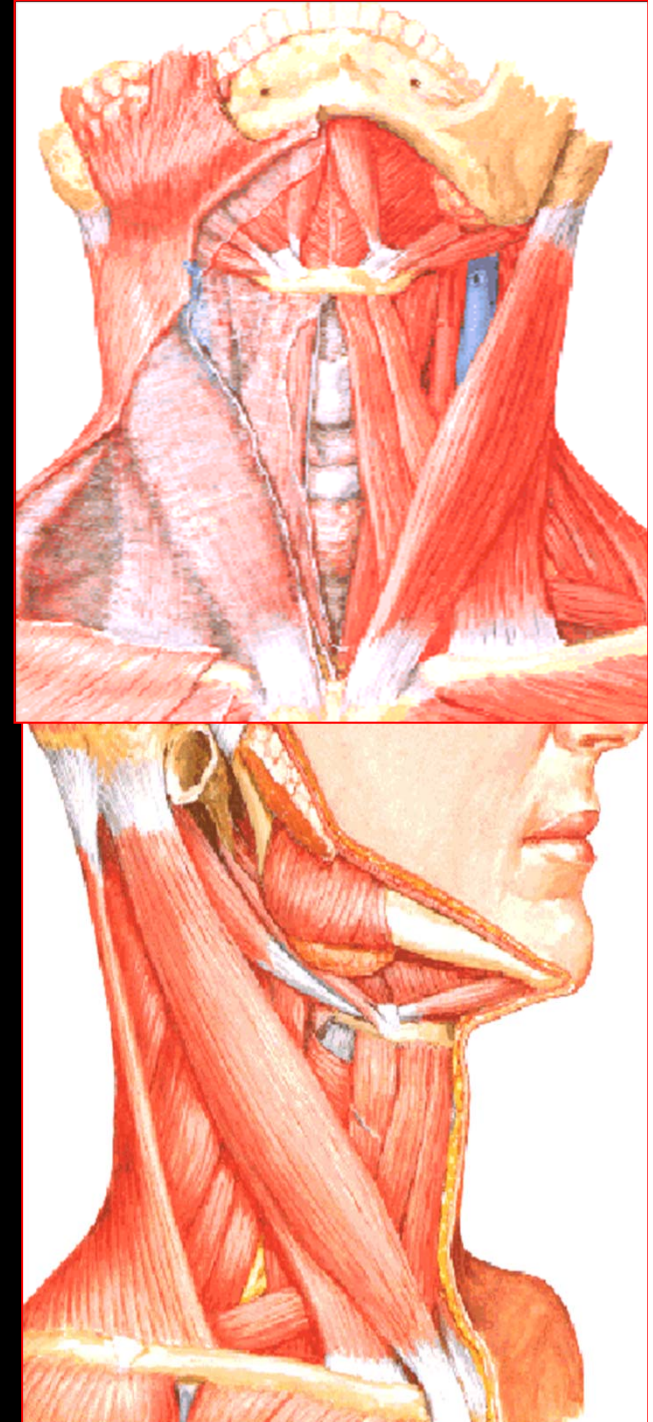
- the thyroid gland
- the trachea
- and the larynx

The following muscles work to lower the hyoid bone when swallowing, except for the sternothyroid muscle, which moves the thyroid cartilage backward when swallowing. The thyroid cartilage is known as the Adam's Apple. The infrahyoid muscles are those below the hyoid bone.

Consist of
4 muscles arranged into 2 layers

1-The superficial layer

2-The deep layer



The superficial layer

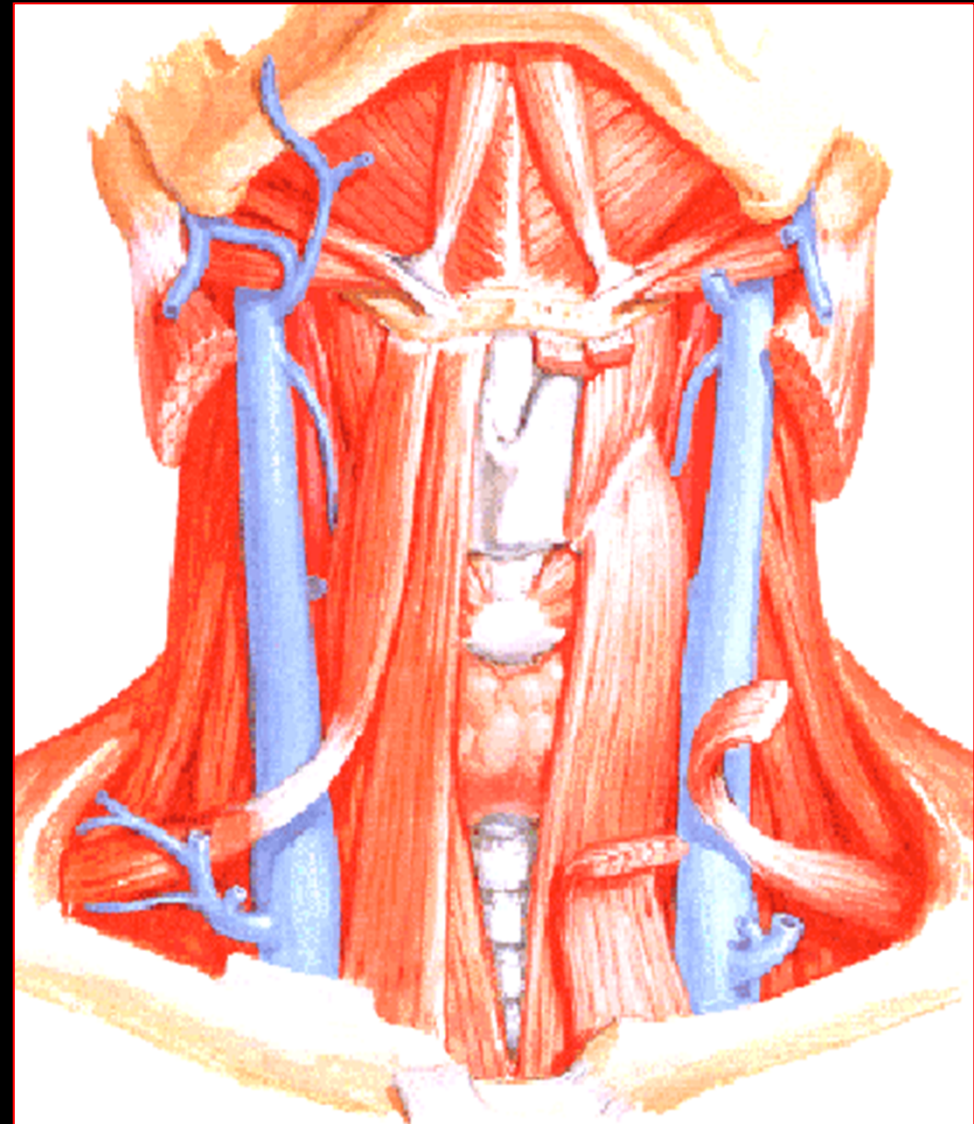
1-the sternohyoid

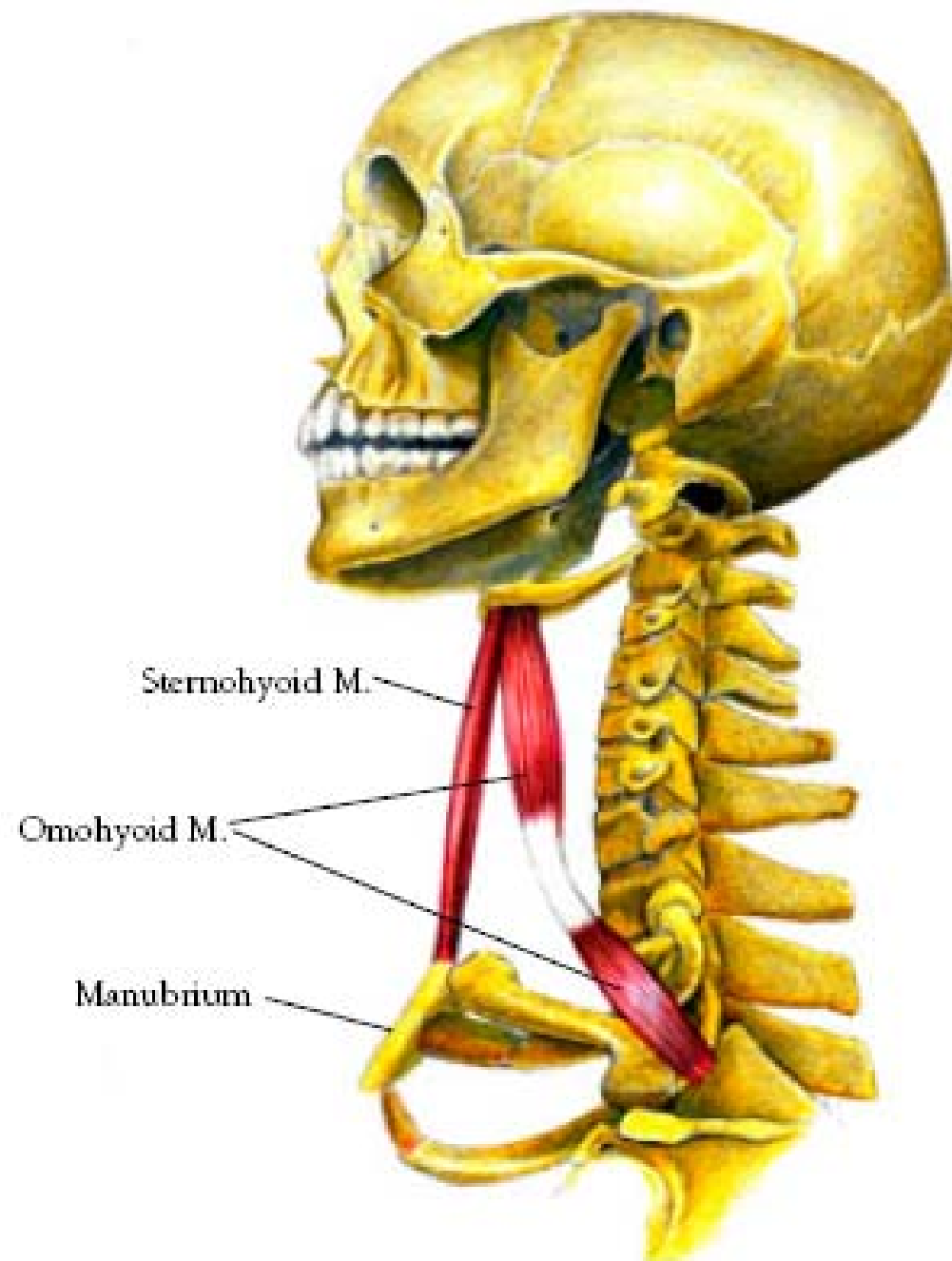
- lies near the middle line
- covers the other 2 muscles
- back of manubrium →
lower border of body of hyoid

2- the omohyoid

Omo is Greek for shoulder.

- The omohyoid muscle has two bellies connected by a tendon, the front portion lying just next to the sternohyoid muscle. It arises from the upper border of the scapula, passes through a tendinous loop attached to the clavicle, and then continues upward to insert on the hyoid bone.



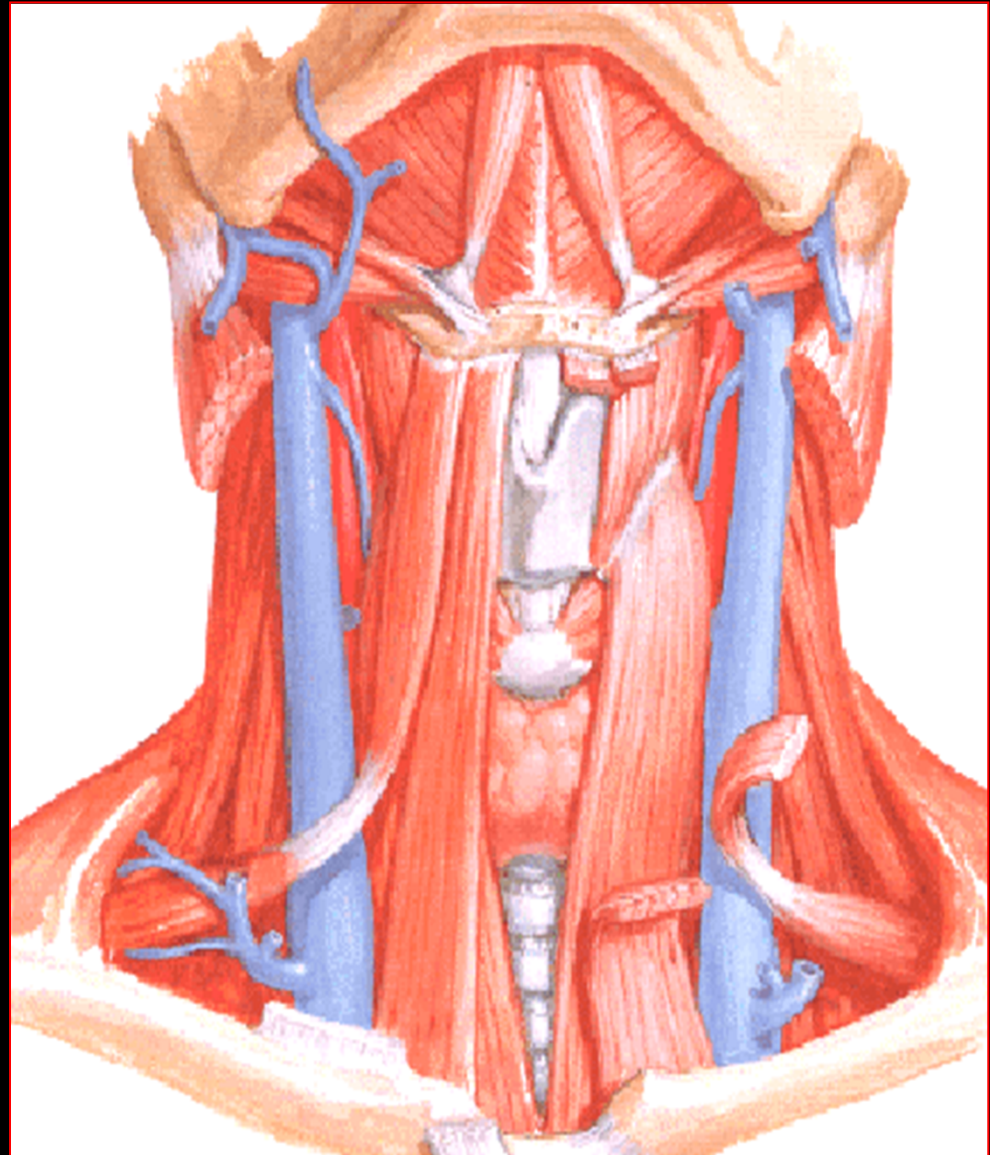


The deep layer

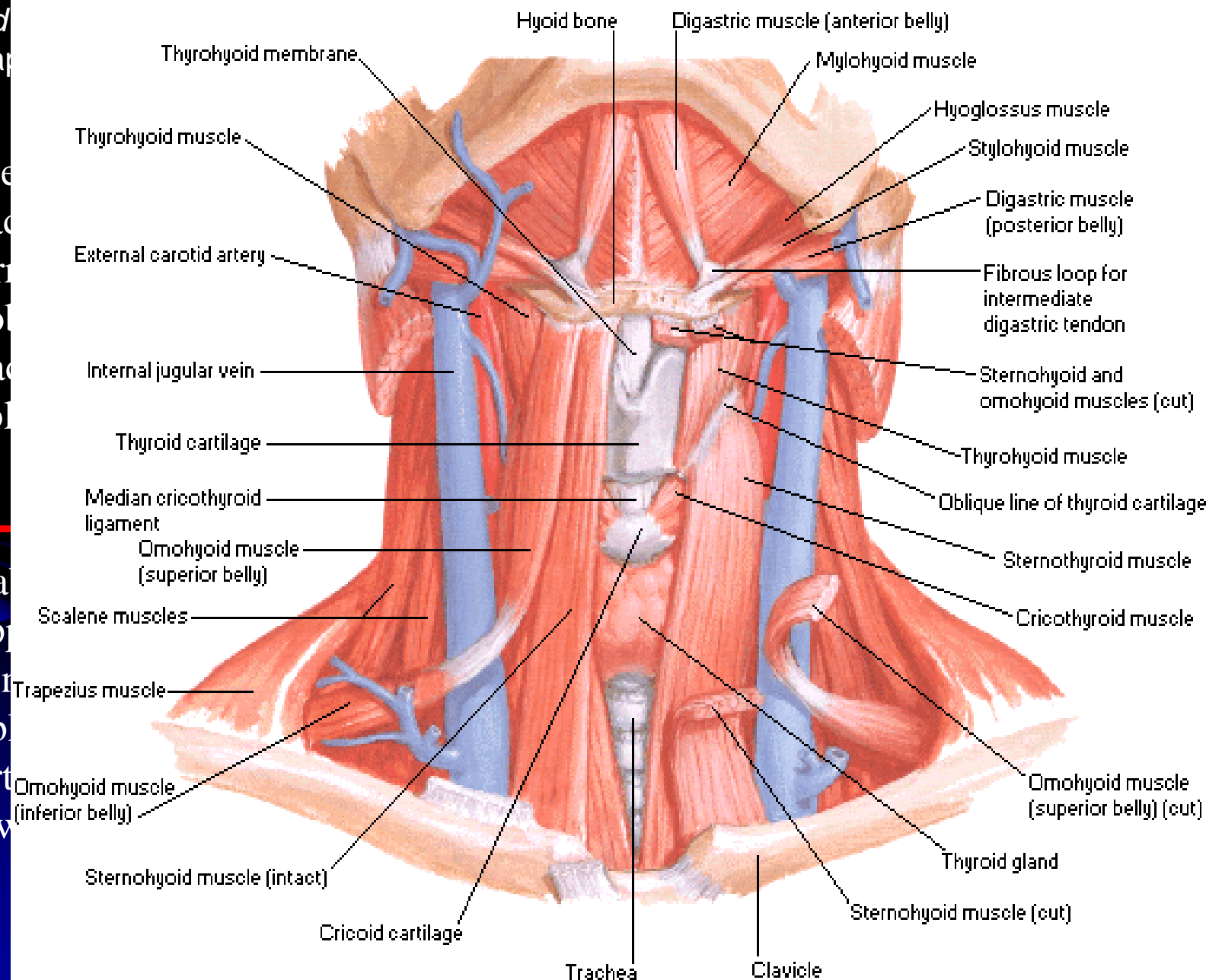
- a sheet of longitudinal muscle fibers
- extend b/w the upper part of the sternum and the lower border of the hyoid bone
- oblique line of the thyroid cartilage divides this sheet into

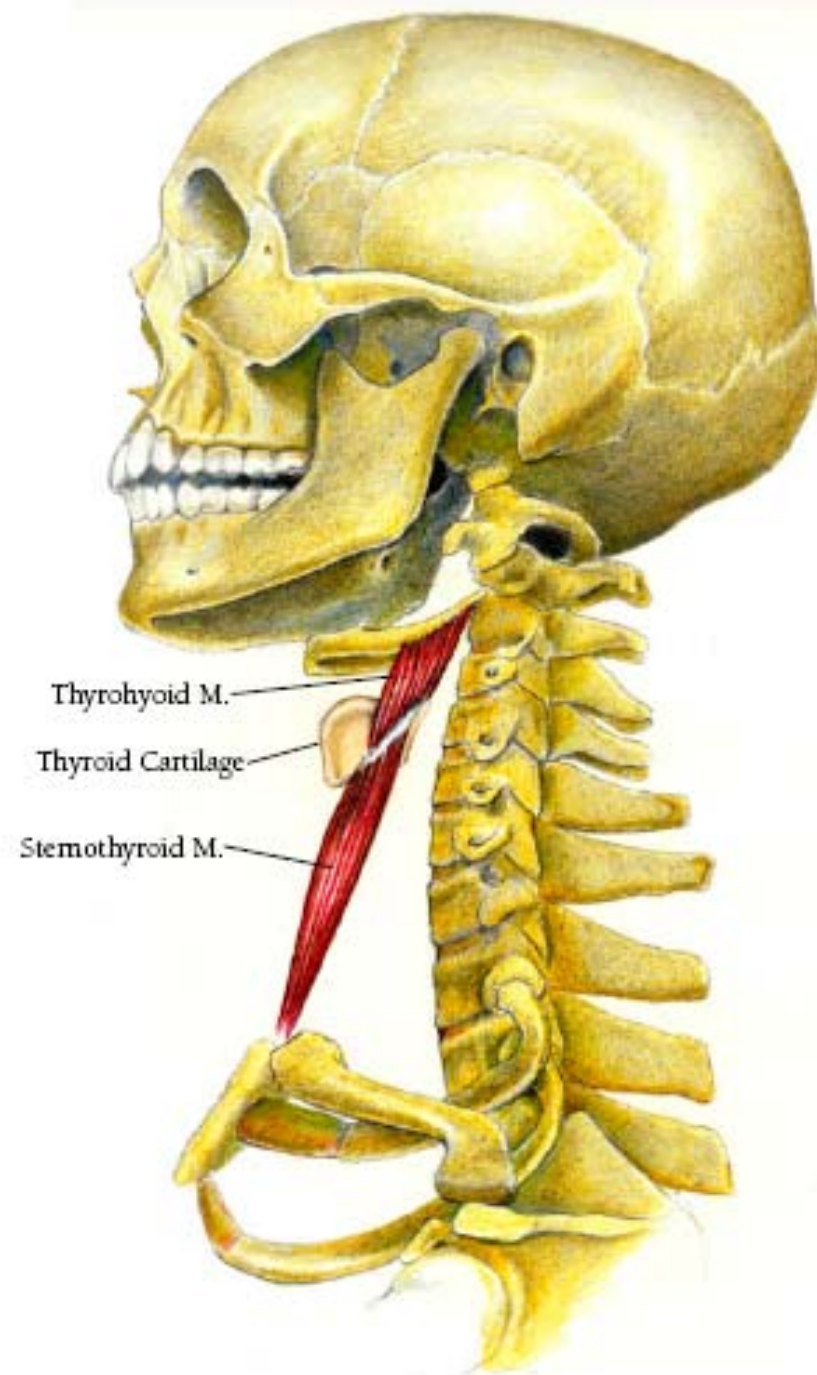
1- sternothyroid

2- thyrohyoid



Infrahyoid and Suprahyoid Muscles

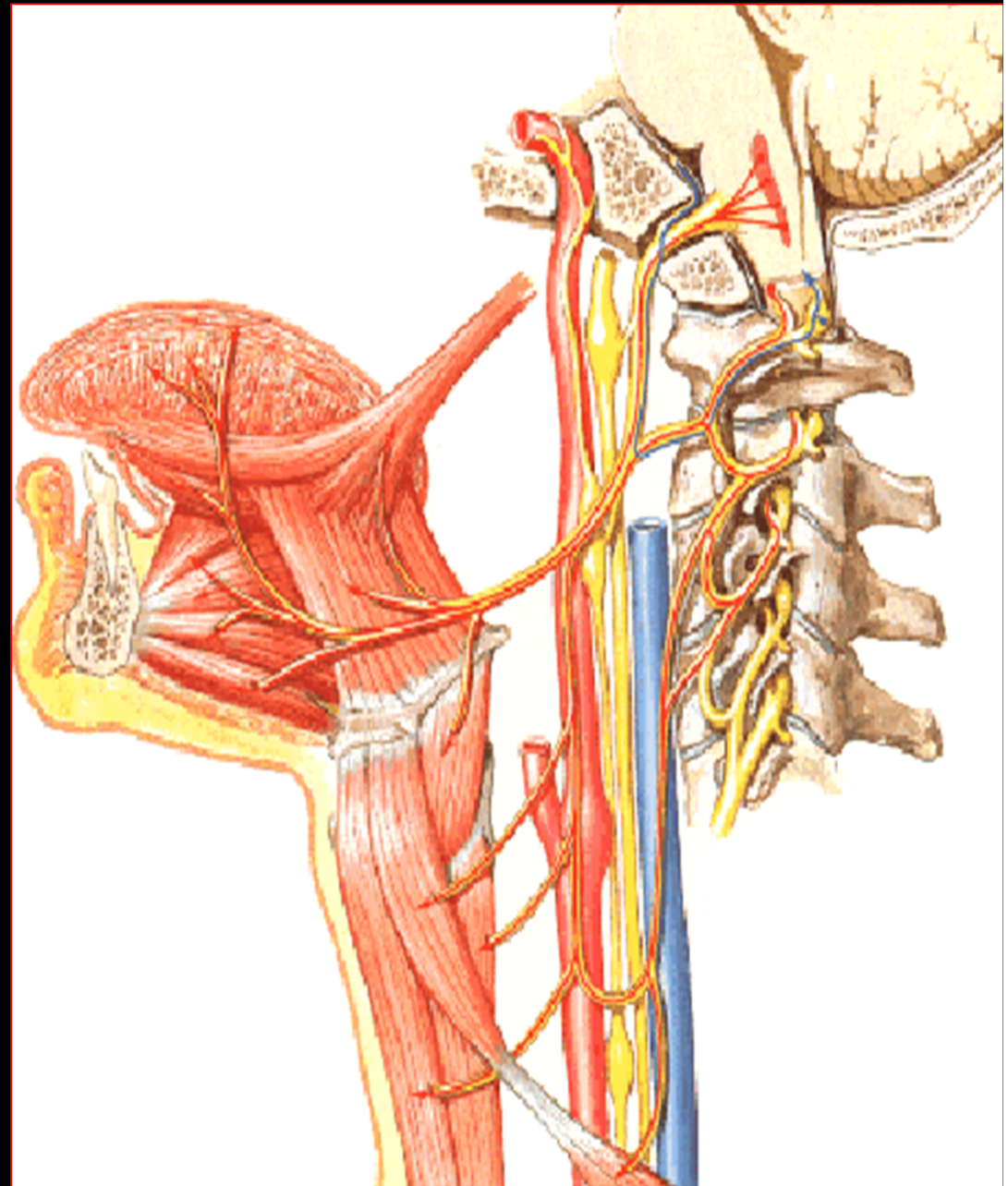




*All the infrahyoid muscles except the thyrohyoid are supplied by branches of ansa cervicalis

*Thyrohyoid m.

Thyrohyoid branch from C1
(appears to arise from CN12)



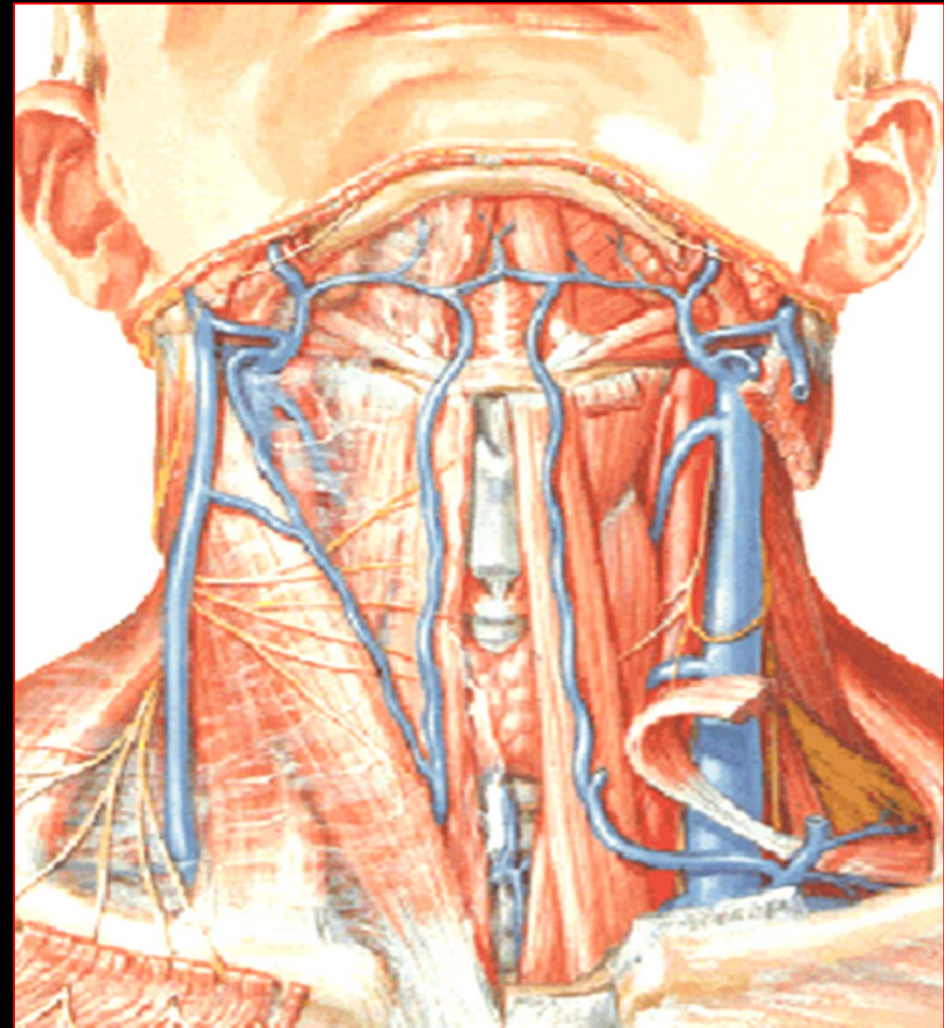
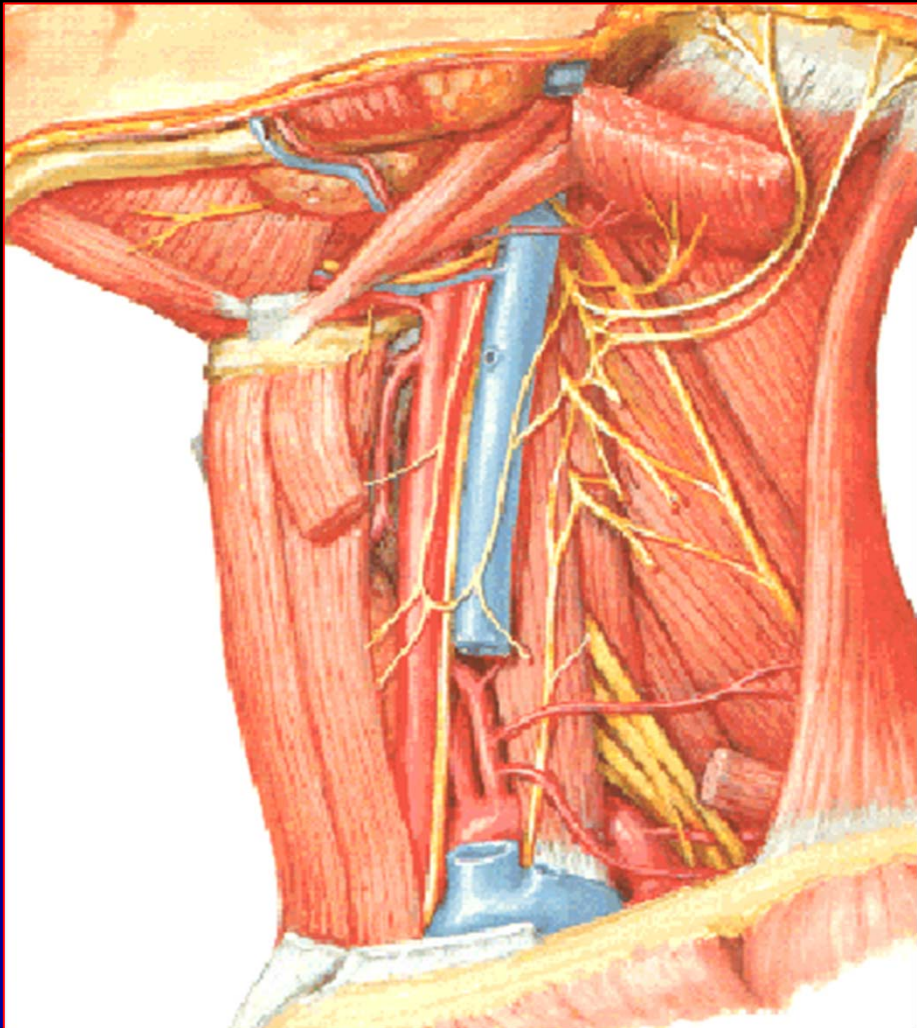
The Ansa Cervicalis (ansa= loop)

It is a loop which

a- lies in front of the carotid sheath

b- is formed by the union of 2 descending nerves

c- supplies → 3 infrahyoid muscles



1- the first descending nerve (descendens hypoglossi (superior root))

- appears to arise as a branch from the hypoglossal nerve, but comes originally from C1
- is derived from fibers from C2 or C2 and C1
- loop upward to join and travel with the hypoglossal nerve

2- the second descending nerve (descendens cervicalis (inferior root))

- arises from primary rami of C2 & C3
- is formed behind the IJV within the carotid sheath

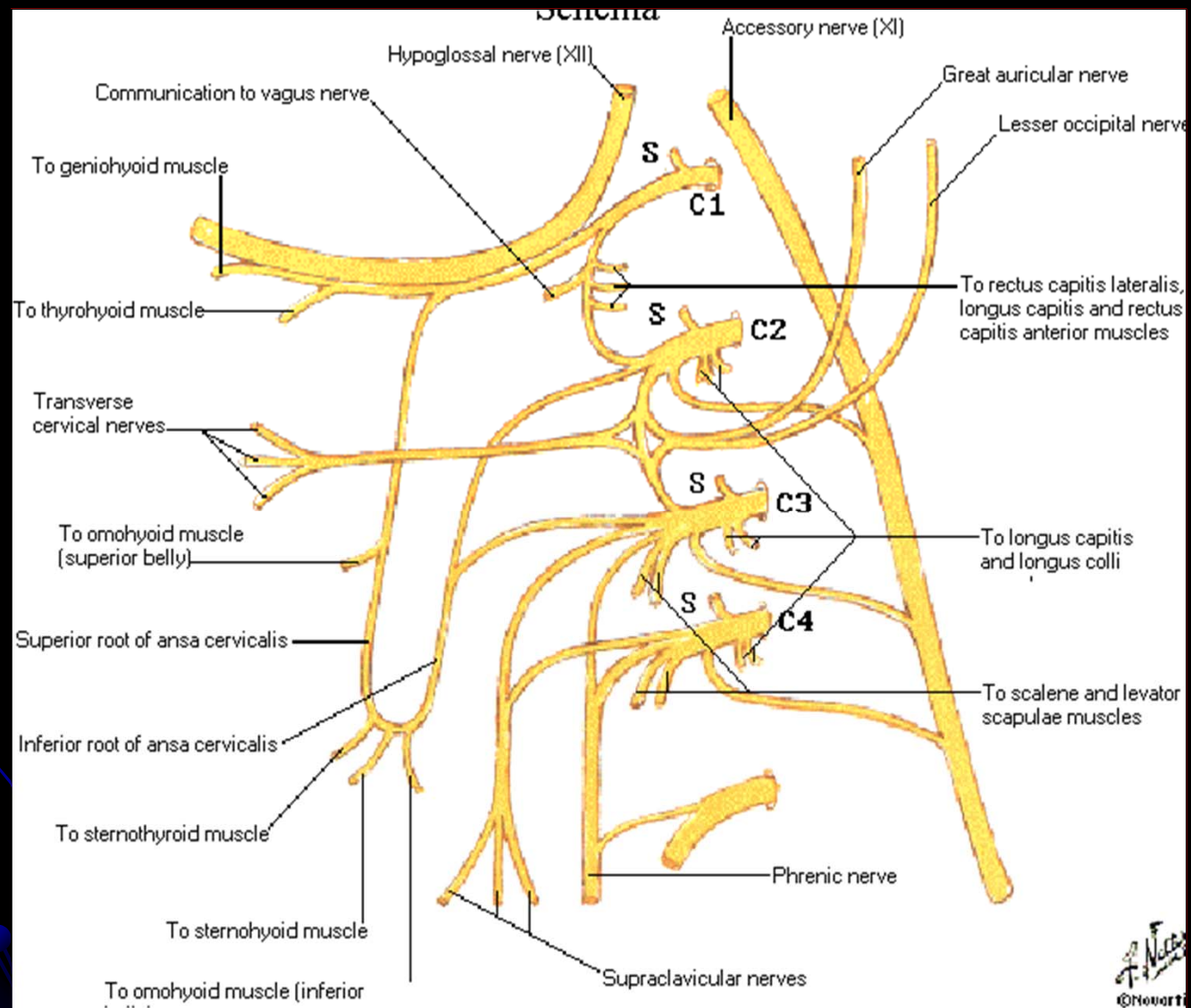
***the ansa cervicalis arises (C1, C2 & C3)**

•supplies 3 infrahyoid m.

1-omohyoid

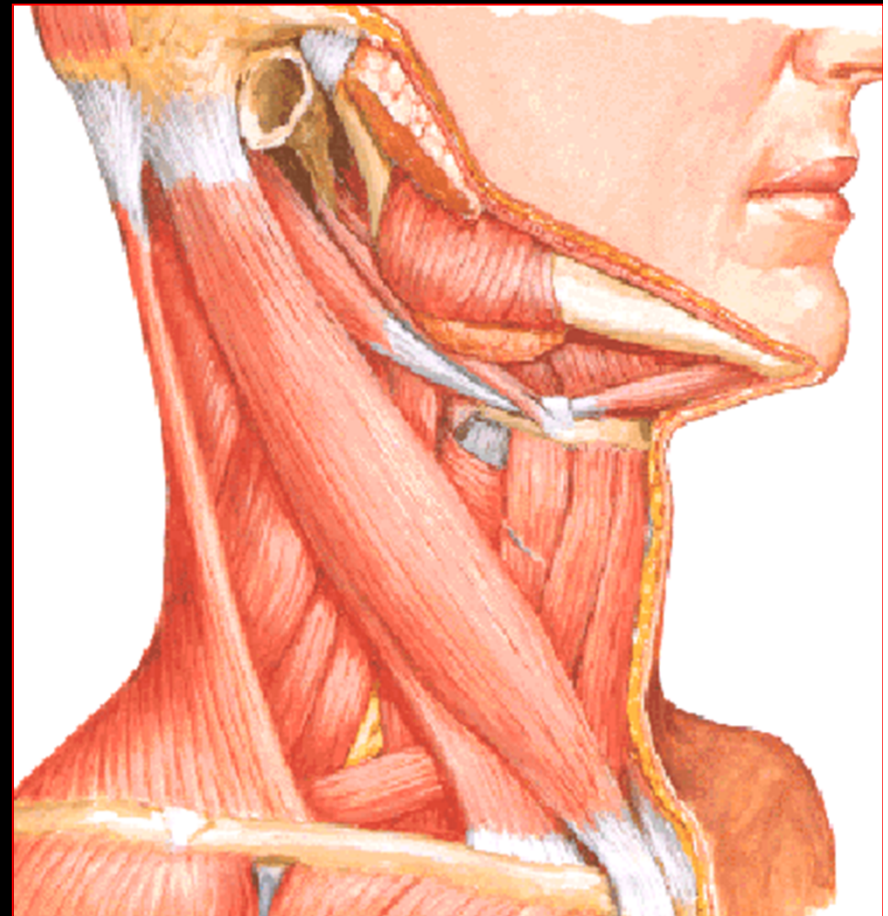
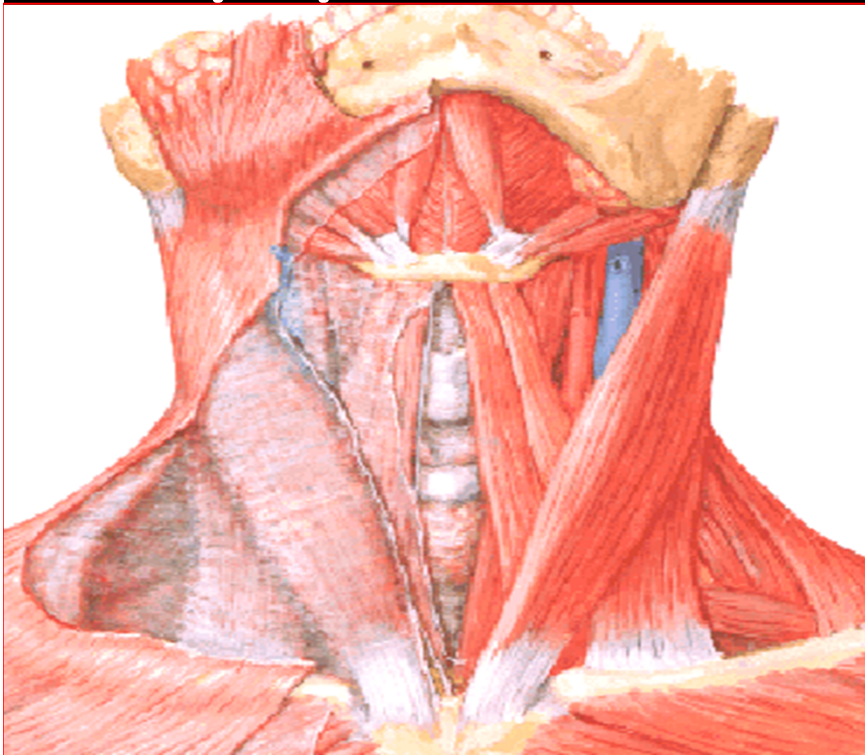
2-sternohyoid

3-sternothyroid



Carotid Triangle

- *SCM→behind
- *post.belly of the digastric m→above
- *sup. Belly of the omohyoid m→in front
- * floor→ parts of the
 - middle pharyngeal constrictor m.
 - inferior pharyngeal constrictor m.
 - thyrohyoid m.



Contents of carotid triangle

1- the carotid sheath

and most of the branches of the ext.carotid artery

2-ansa cervicalis

in front of the carotid sheath

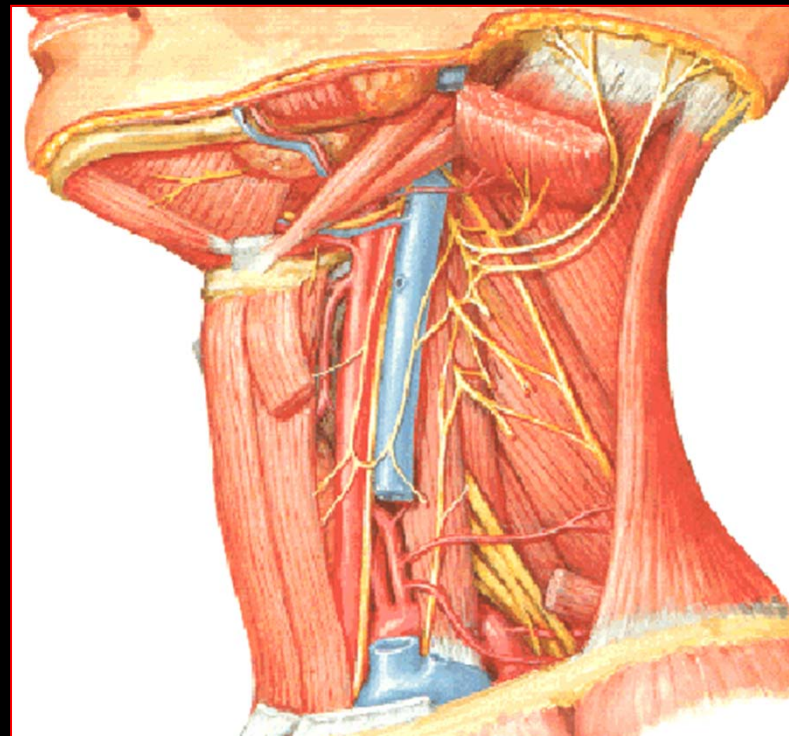
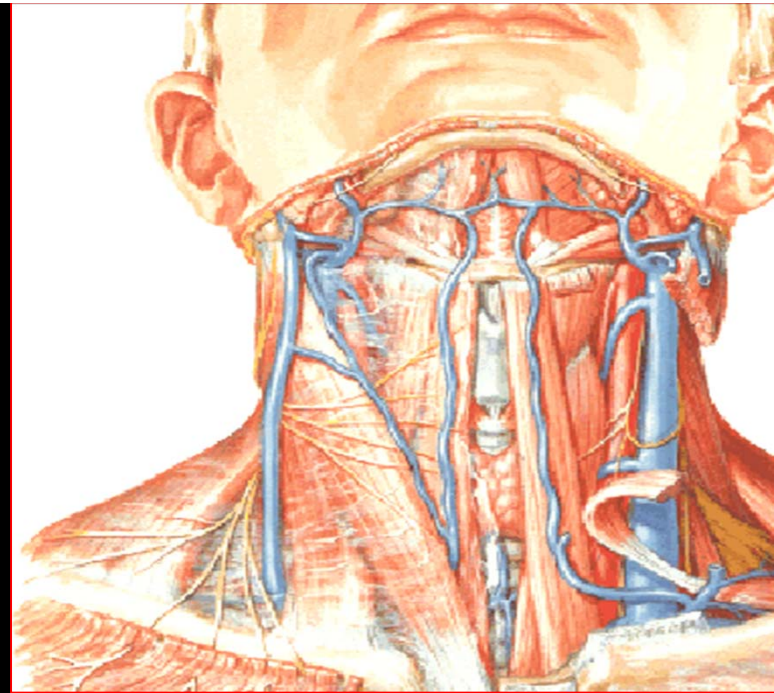
a- the descendens hypoglossi

b- the descendens cervicalis

3-sympathetic chain

embedded in its post. wall

4- vagus nerve and hypoglossal nerves



Contents

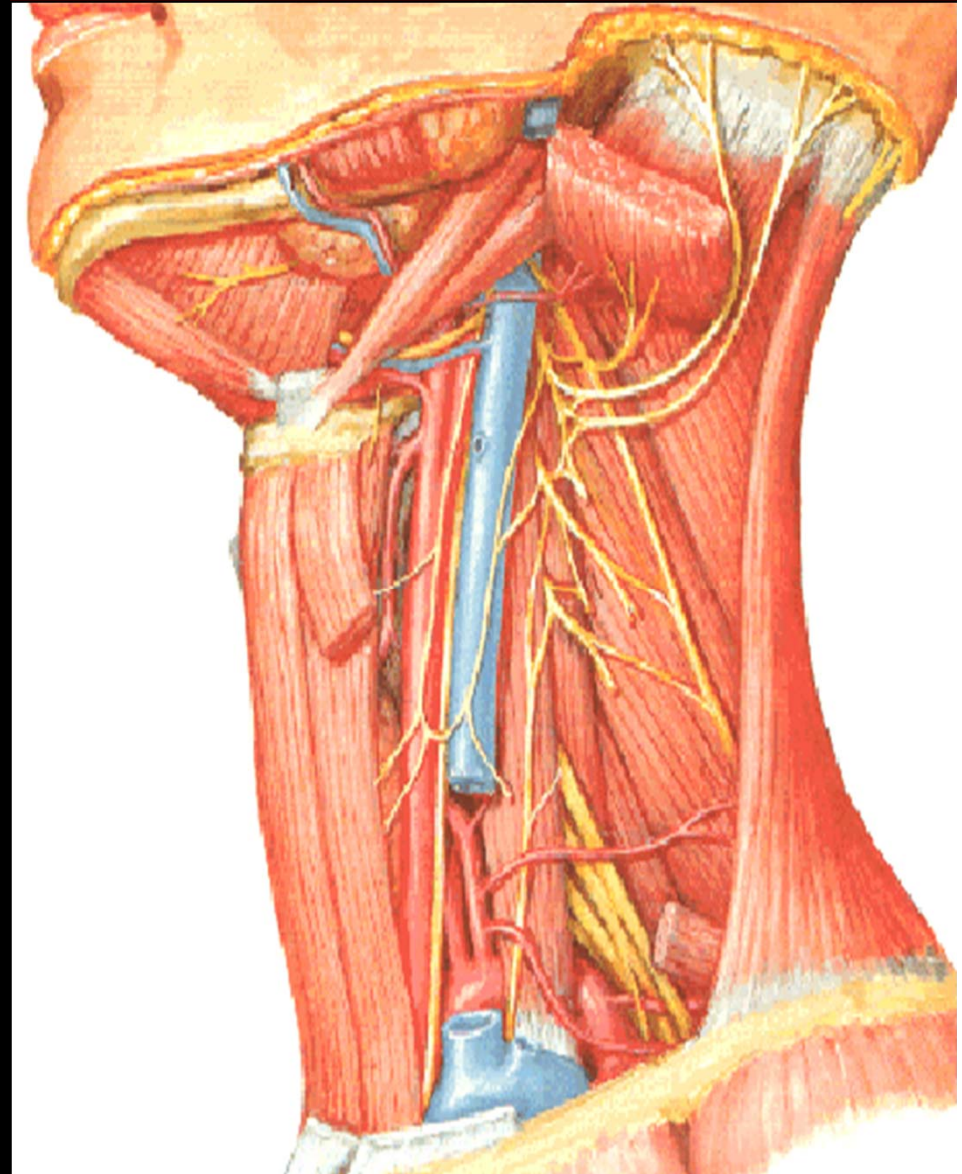
1- the carotid sheath

a tube of CT which envelopes
3 structures

a- the common carotid
artery(below) & the internal carotid
artery(above)

b- the internal jugular vein: on the
lateral side of the artery

c- the vagus nerve : b/w the artery
& vein but in posterior plane



The vessels in the carotid] triangle

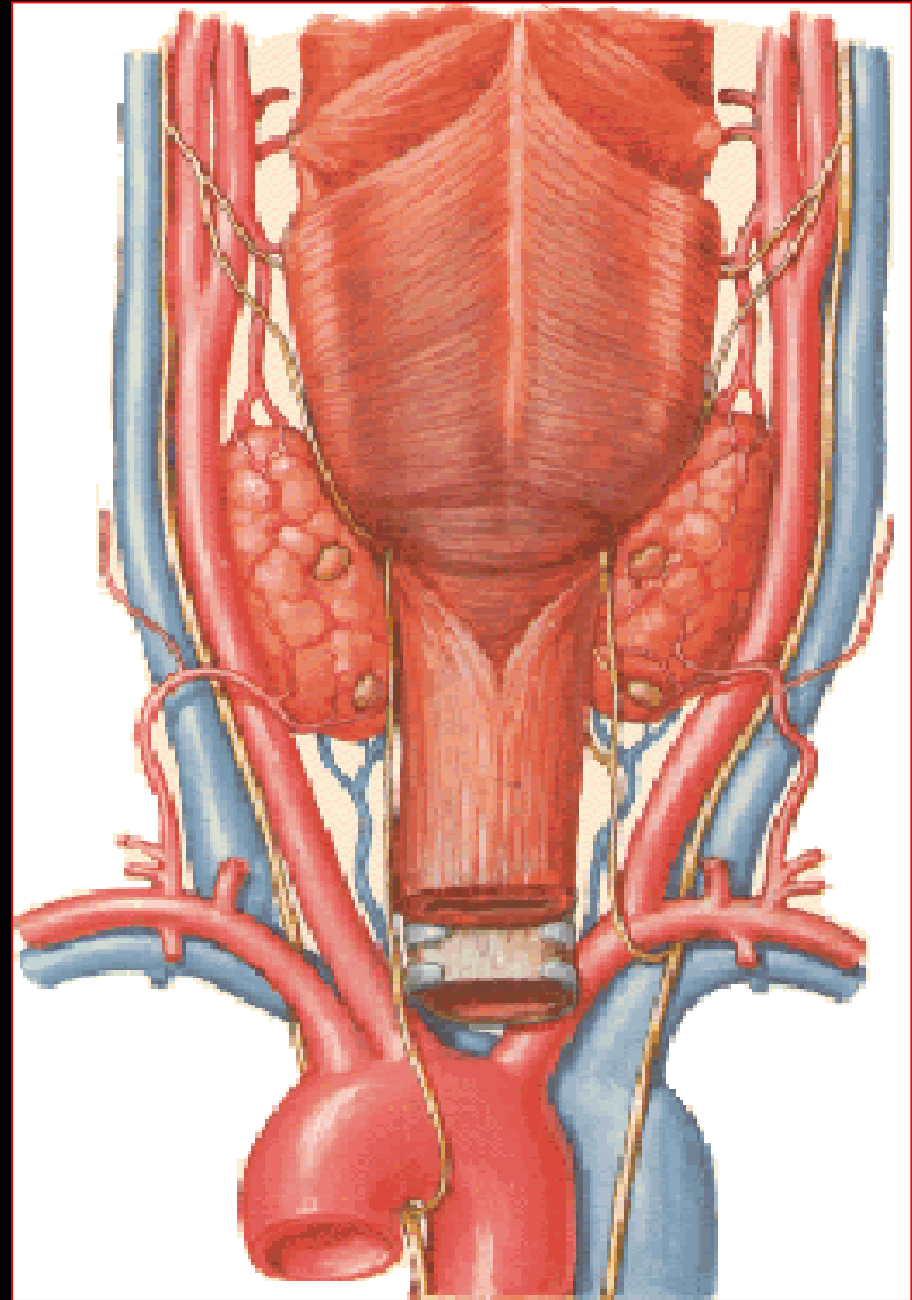
1- common carotid artery

-On the right side

It arises from the right brachiocephalic behind the right sternoclavicular joint

-On the left

arises from the arch of aorta in the superior mediastinum



In the neck

-Extends from the *sternoclavicular joint* into the upper border of the thyroid cartilage (level of C4)

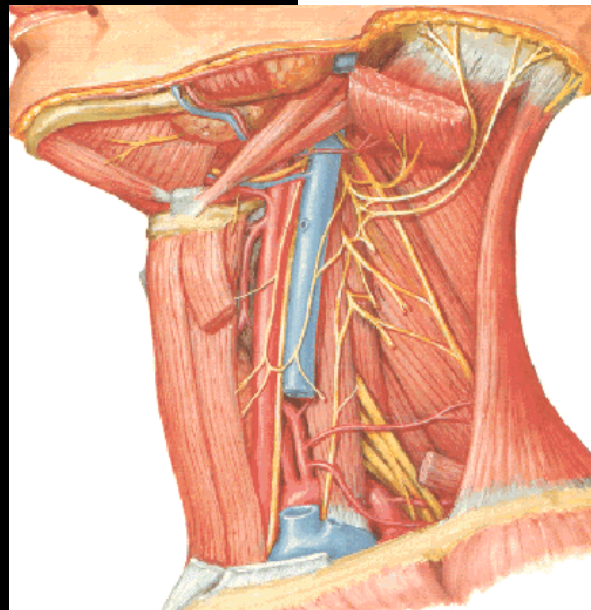
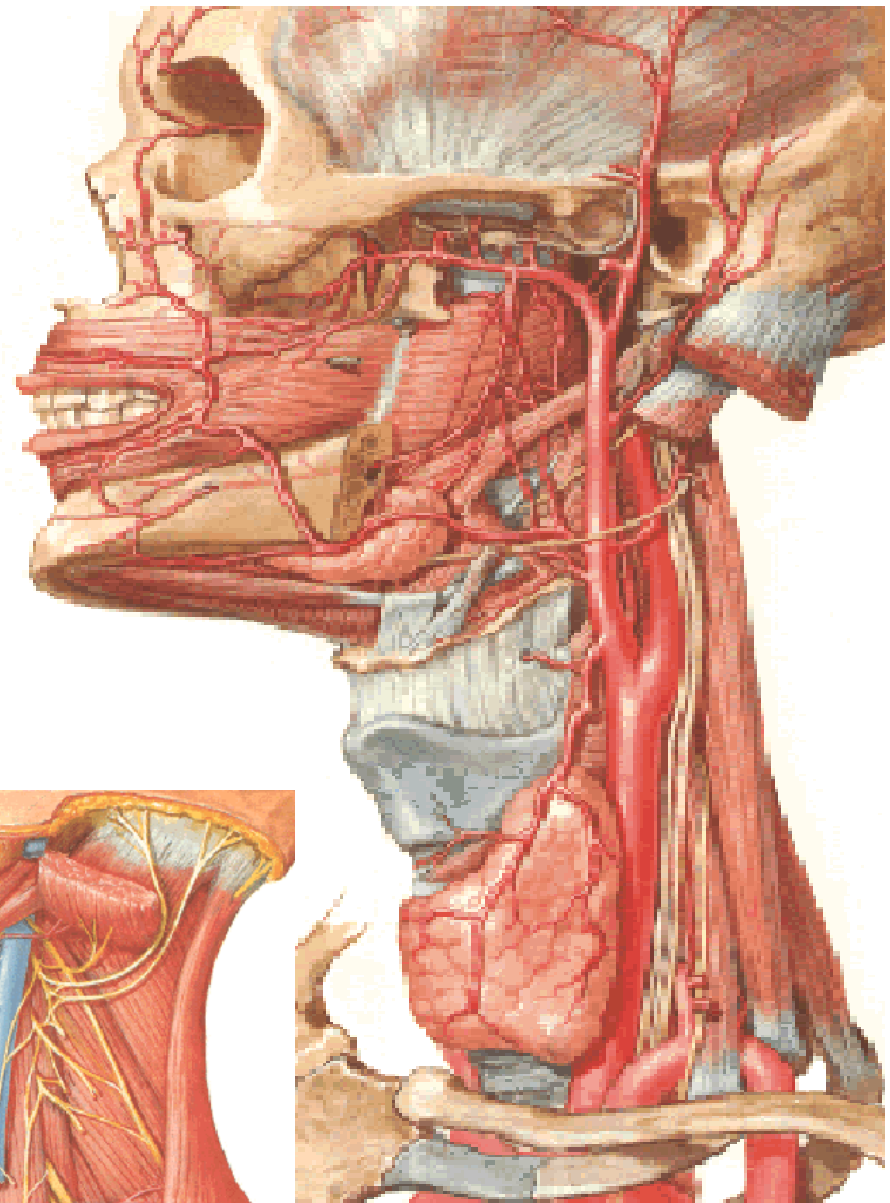
-Where it divides
into 1- internal carotid artery
2- external carotid artery

•Lies deep to the anterior border of the SCM

•Lies within the carotid sheath


Medial to the IJV

Anterior to the vagus nerve



Collateral circulation

- Superior and inferior thyroid aa
- Deep cervical and occipital aa
- Vertebral artery and ICA



Extracranial carotid aneurysm

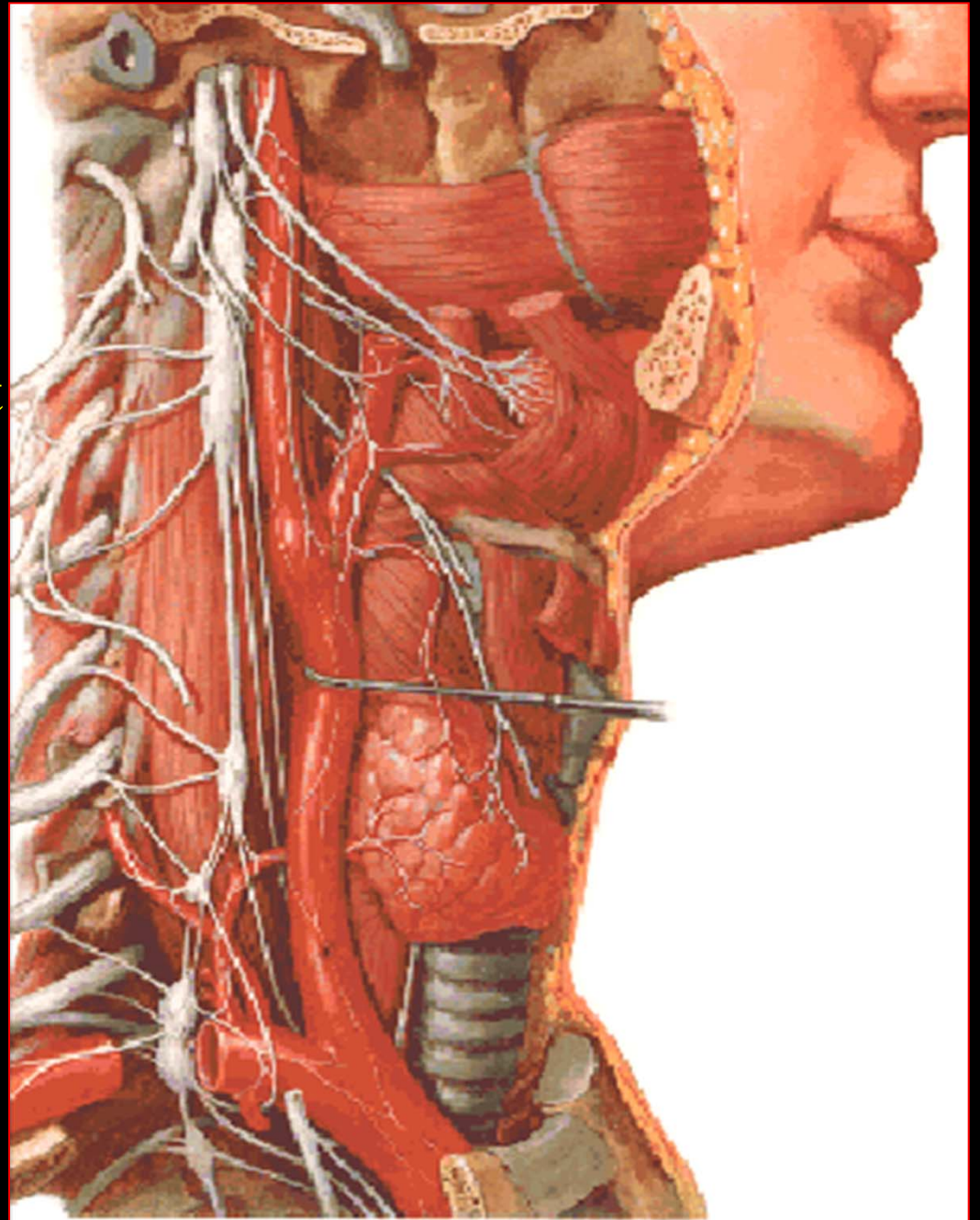
- Pulsatile swelling
- Dyspnea
- Dysphagia
- Hoarsness of voice
- Tongue weakness
- Horner syndrome

Carotid Sinus

- localized dilatation at bifurcation of CCA and first part of ICA

- **Innervated by** the nerve endings of the carotid sinus branch of glossopharyngeal n.
Function as a baroreceptor

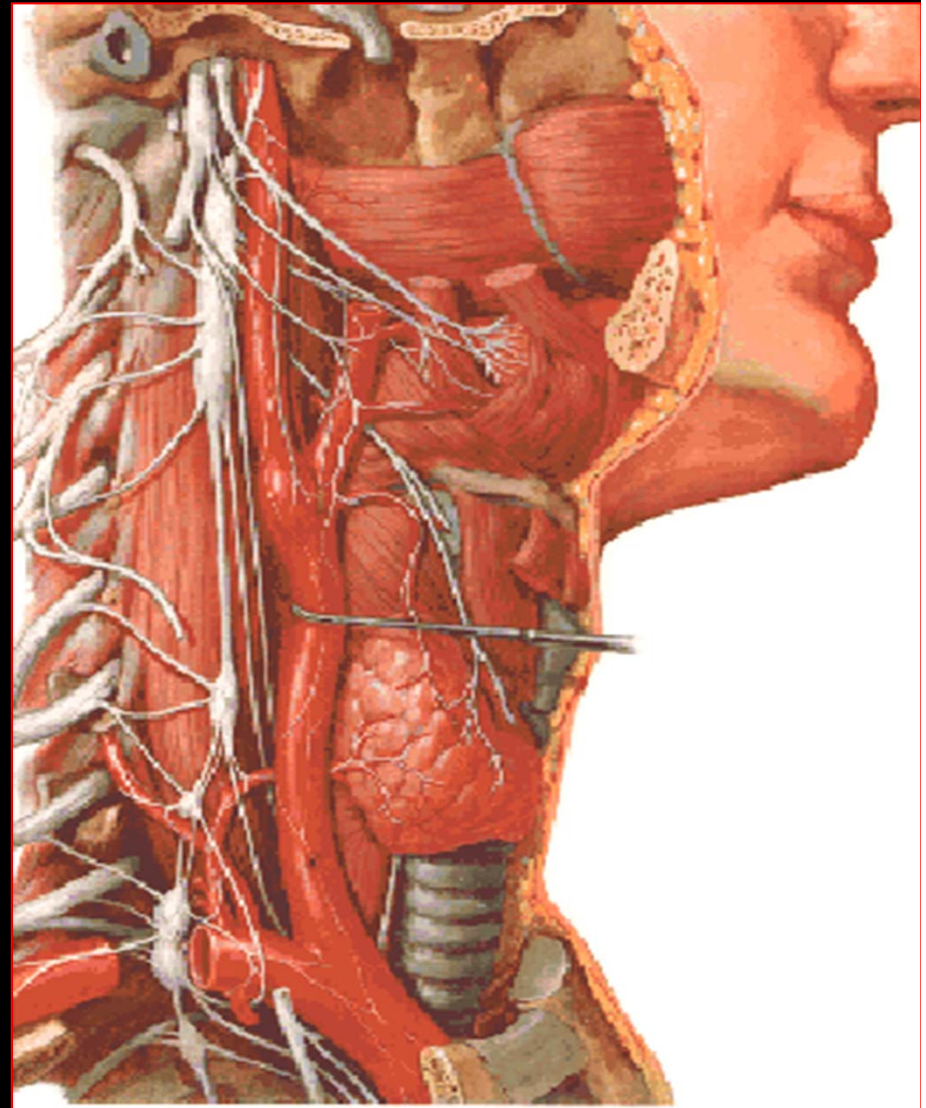
(a rise in blood pressure → a slowing of the HR
vasodilatation of the arterioles)



Carotid Body

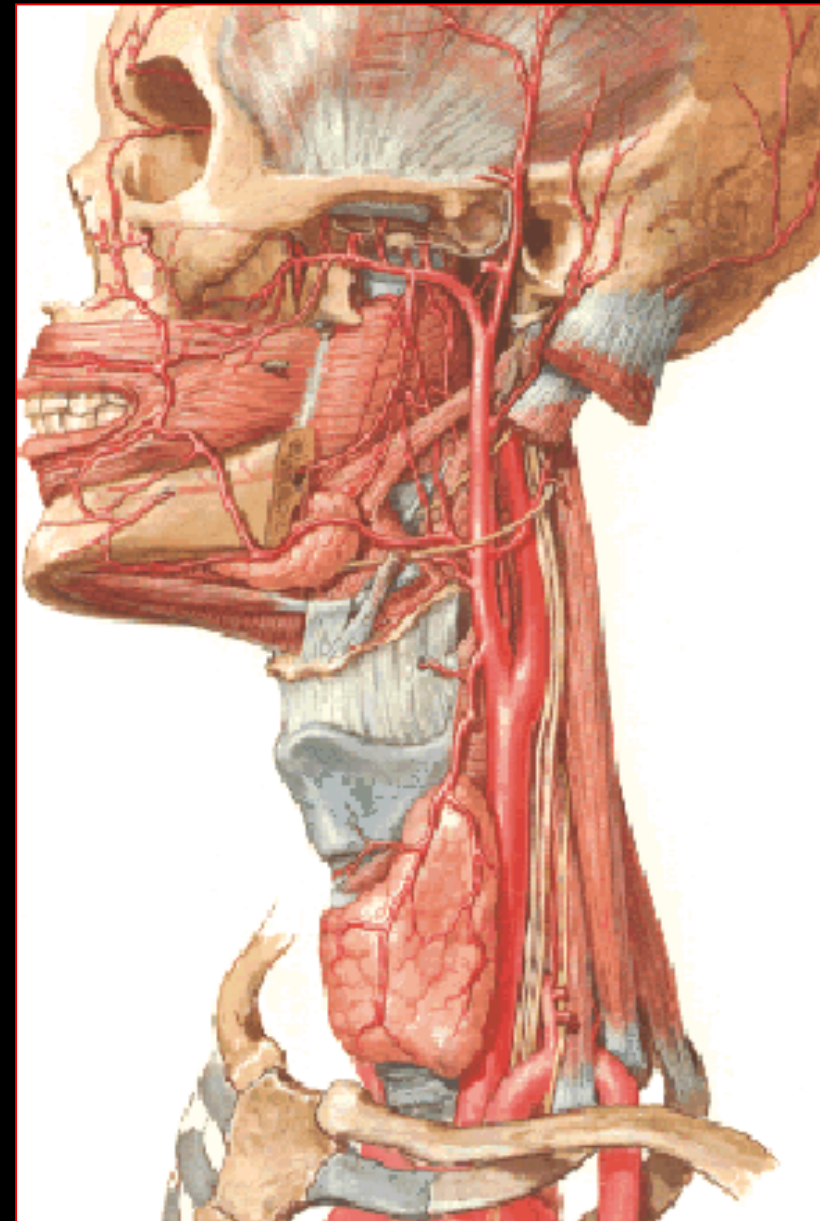
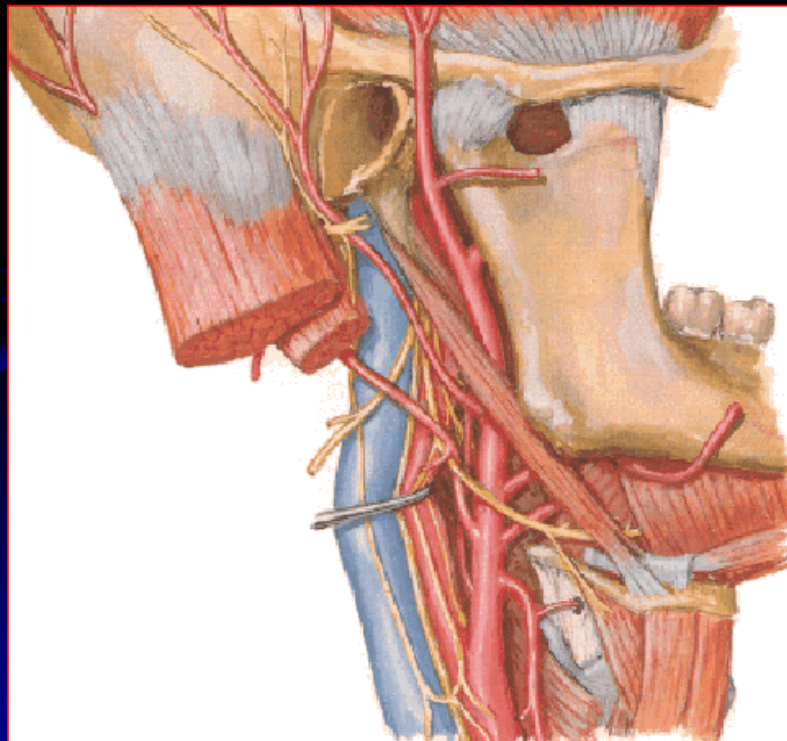
- a small structure
- lies post. to the point of bifurcation
- innervated by the carotid sinus branch of the glossopharyngeal n
- function as a chemoreceptor

(sensitive to excess CO₂ and reduced O₂ tension in the blood → rise in BP & HR and increase in RR)



External carotid artery

- terminal branches of CCA
- begins at the upper border of the thyroid cartilage
- terminates in the substance of the parotid gland behind the neck of mandible



External carotid artery

divides into

1- superficial temporal

2- maxillary arteries

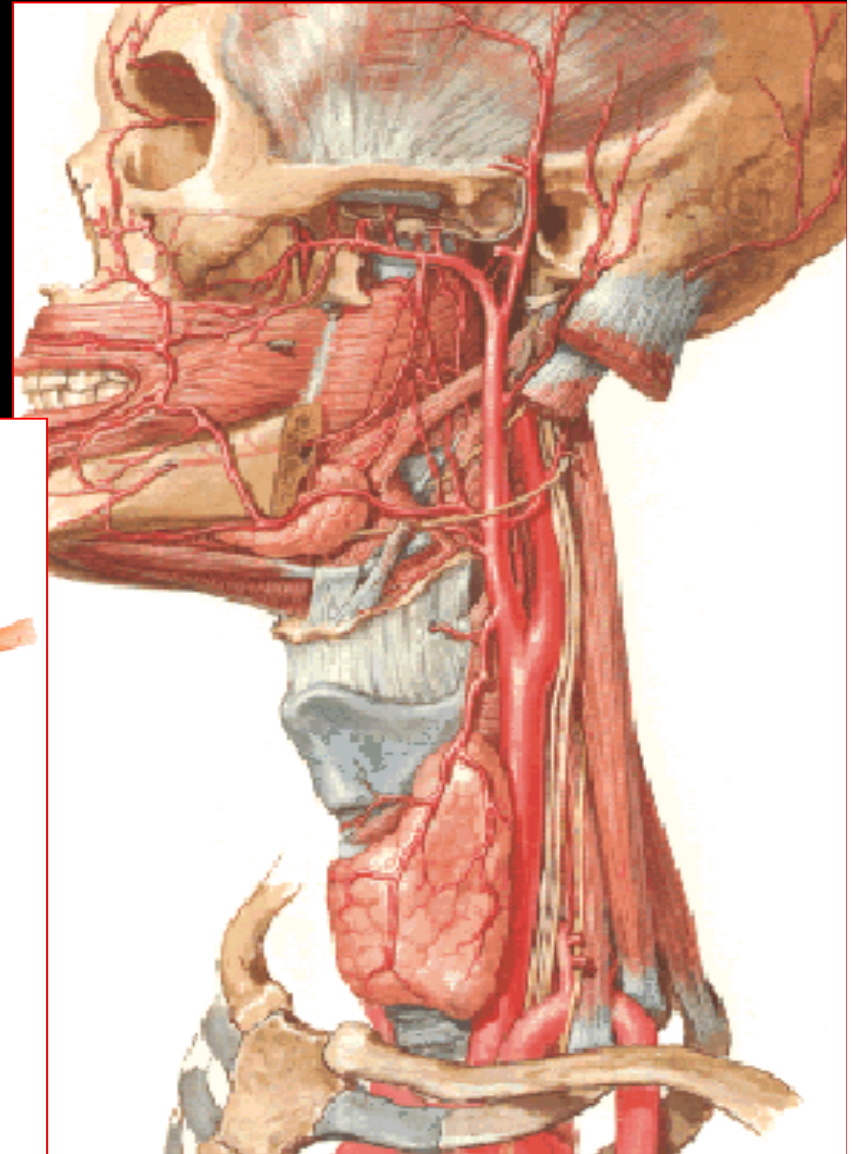
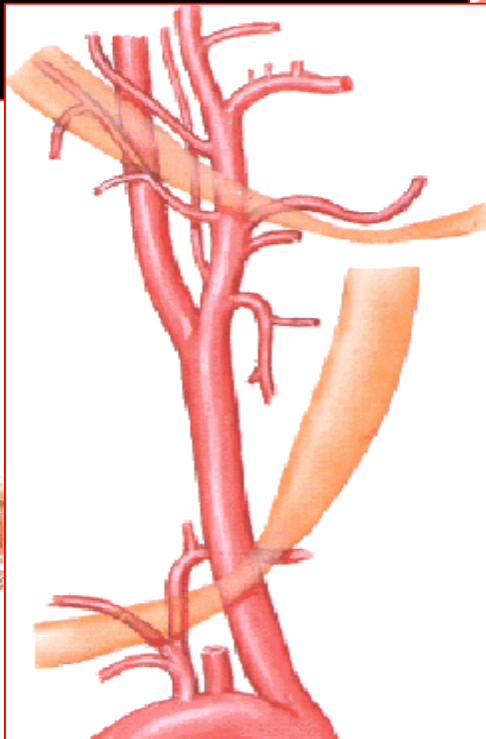
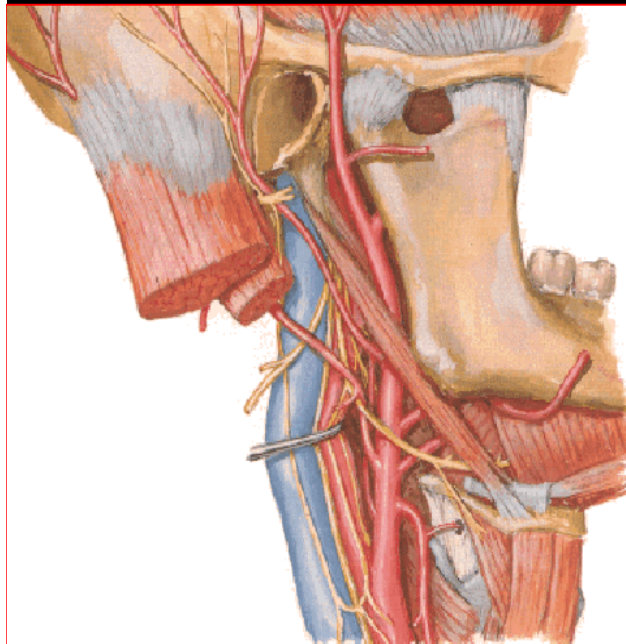
-At first it lies medial to the ICA

-then behind to it

-Is crossed by the

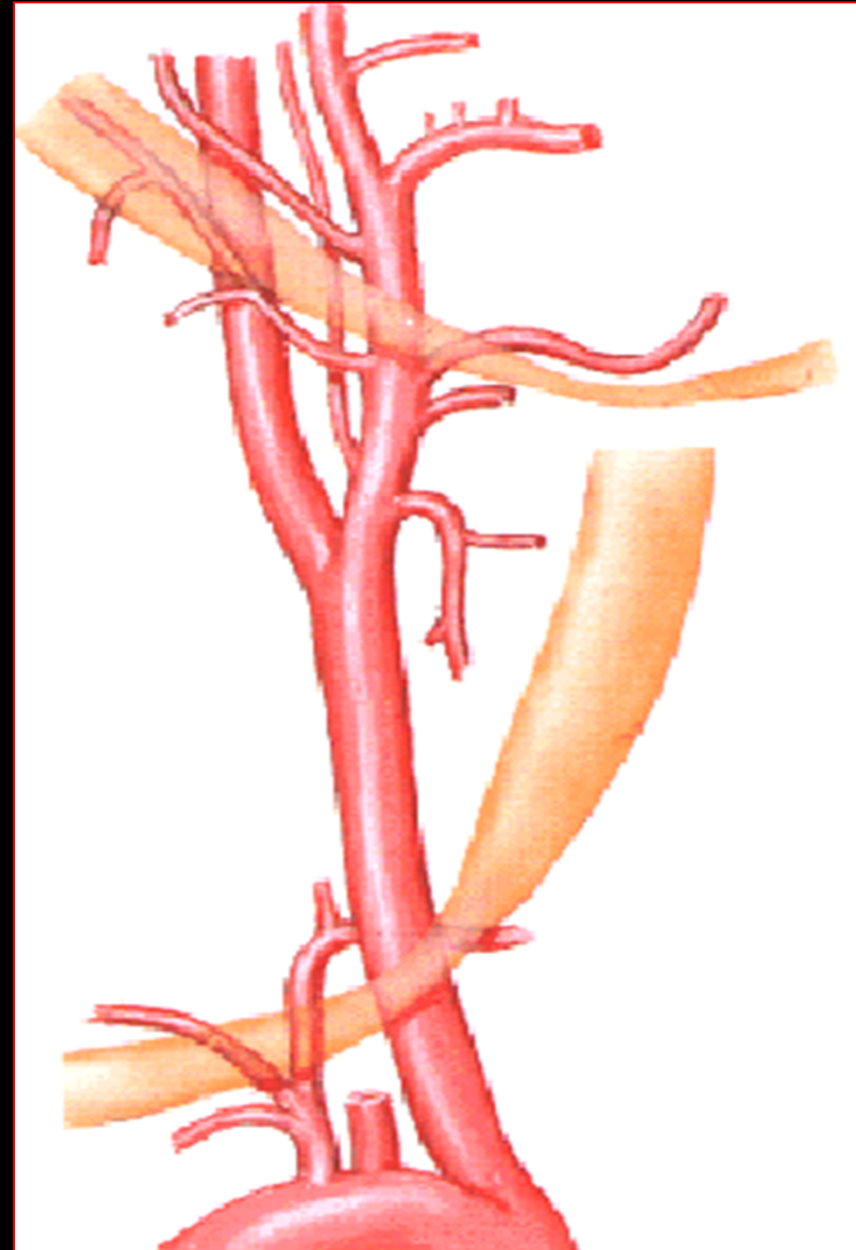
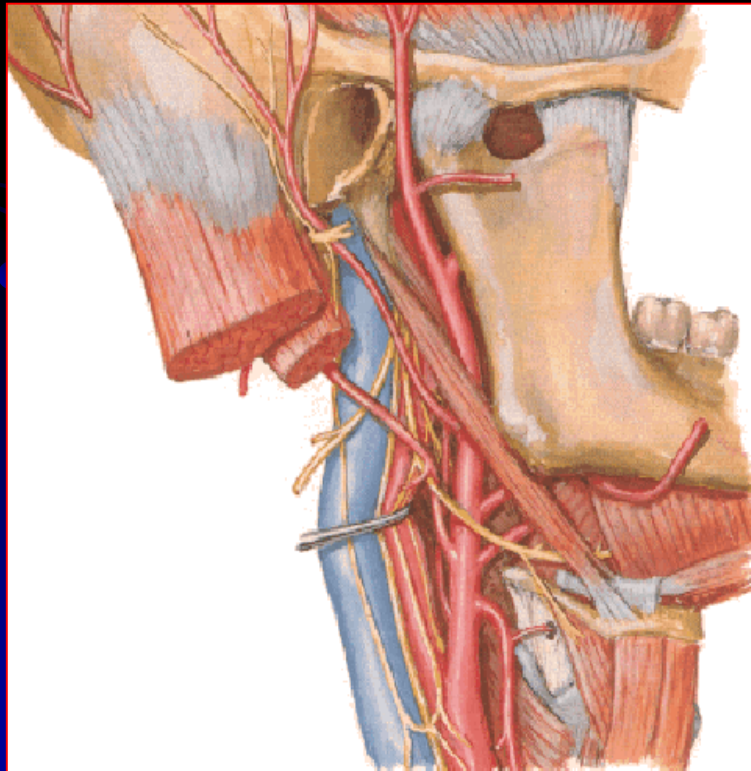
a- post. Belly of the digastric

b- stylohyoid m.



Branches of external carotid a.

- 1- superior thyroid artery
- 2- ascending pharyngeal artery
- 3- lingual artery
- 4- facial artery
- 5- occipital artery
- 6- posterior auricular artery
- 7- superficial temporal artery
- 8- maxillary a.

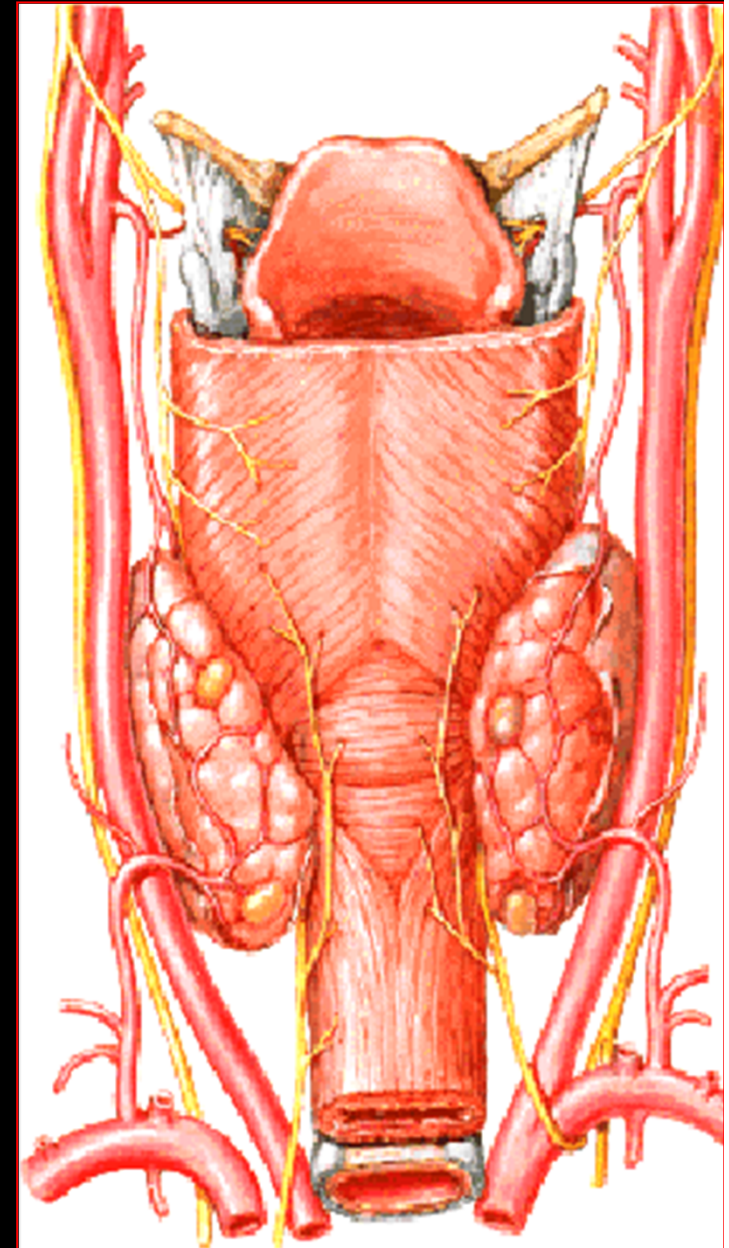
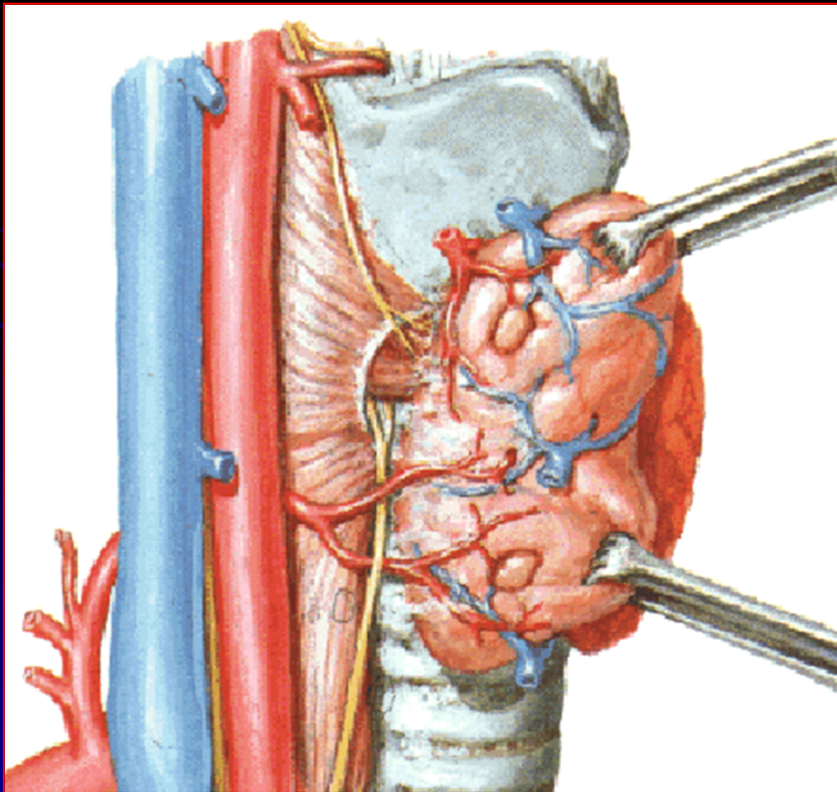


1- superior thyroid artery

- arises near origin of ECC
- upper pole of the thyroid gland
- accompanies the external laryngeal nerve

branche

- superior laryngeal artery
 - pierces the thyrohyoid membrane
 - with the superior laryngeal nerve
- Supplies → larynx, infrahyoid m, and thyroid g

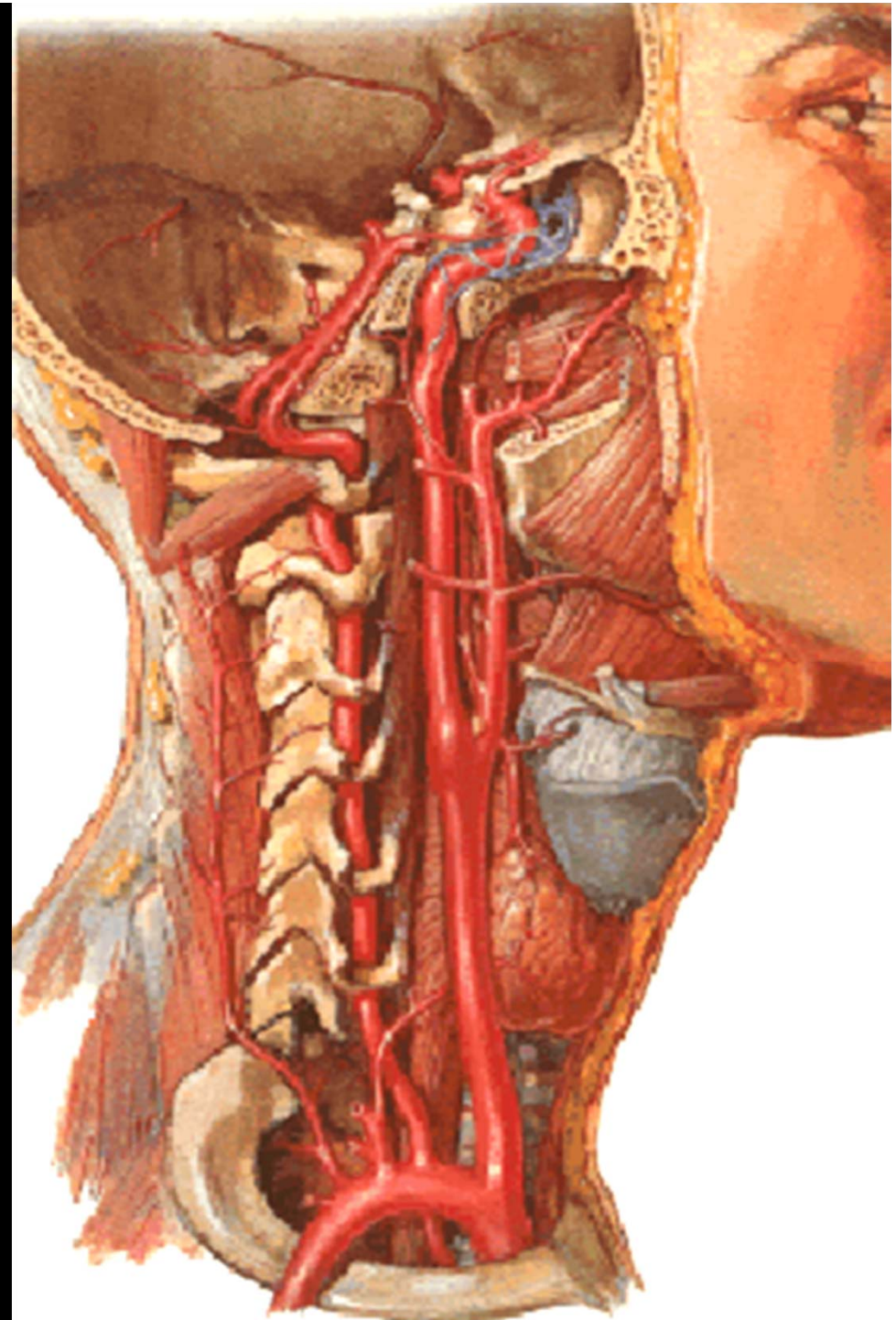


2- Ascending pharyngeal a

- supplies the pharynx
- arising from the medial surface of the origin of the ECA
- Ascends b/w the ICA and the wall of pharynx

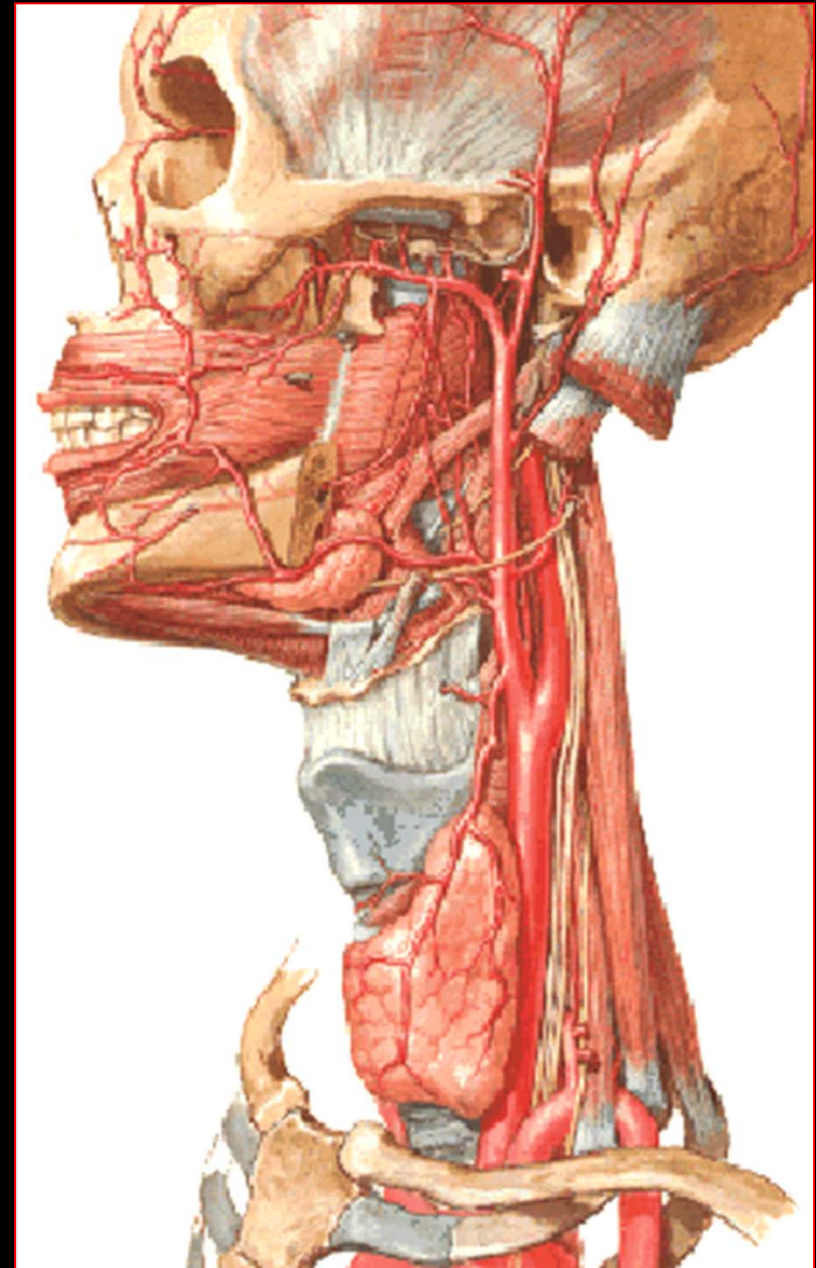
branches

- a- pharyngeal**
- b- meningeal**
- c- palatine tonsil**
- d-inferior tympanic artery**



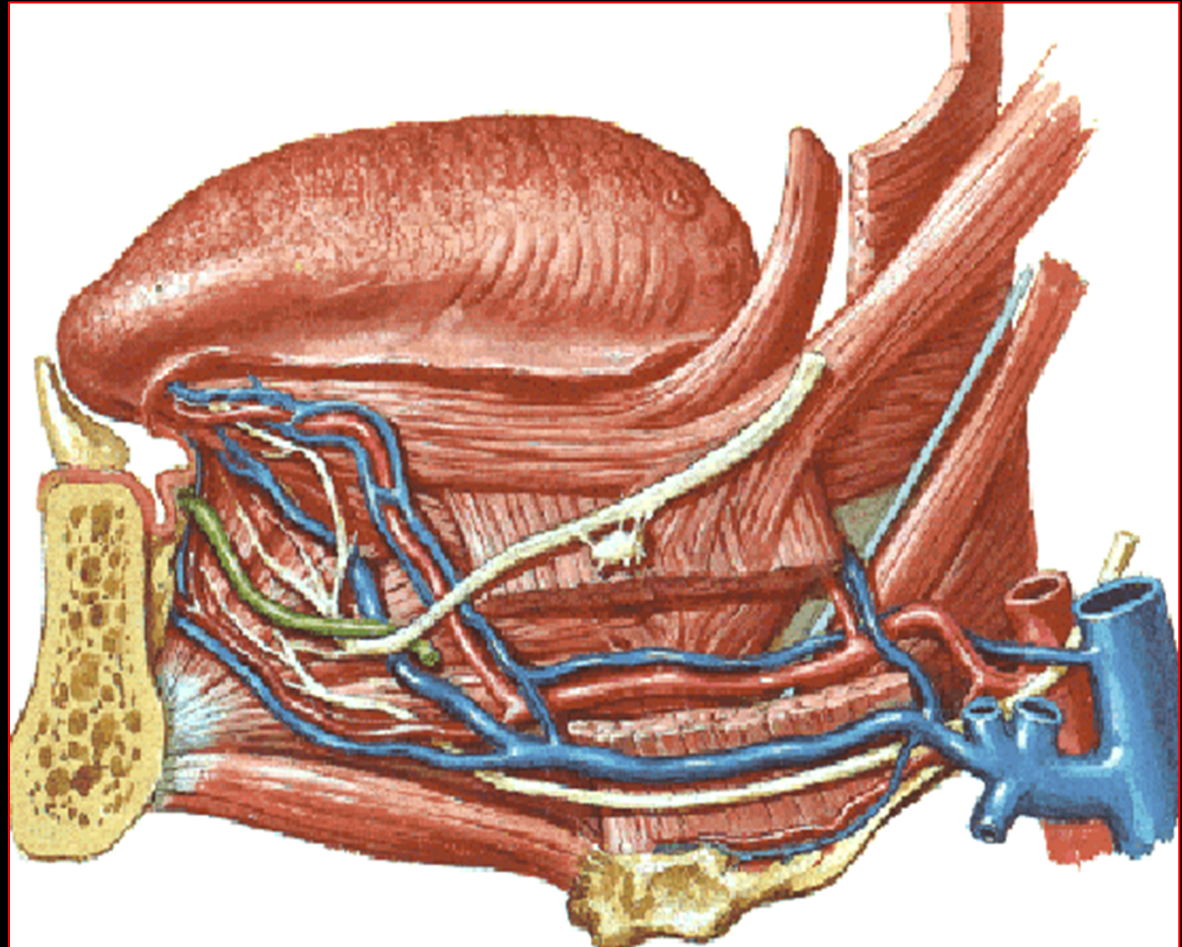
3- lingual artery

- opposite the tip of the greater cornu of the hyoid bone
- deep to hyoglossus muscle to reach the tongue
- accompanies by the deep inguinal vein
- near its origin is crossed superficially by the hypoglossal n



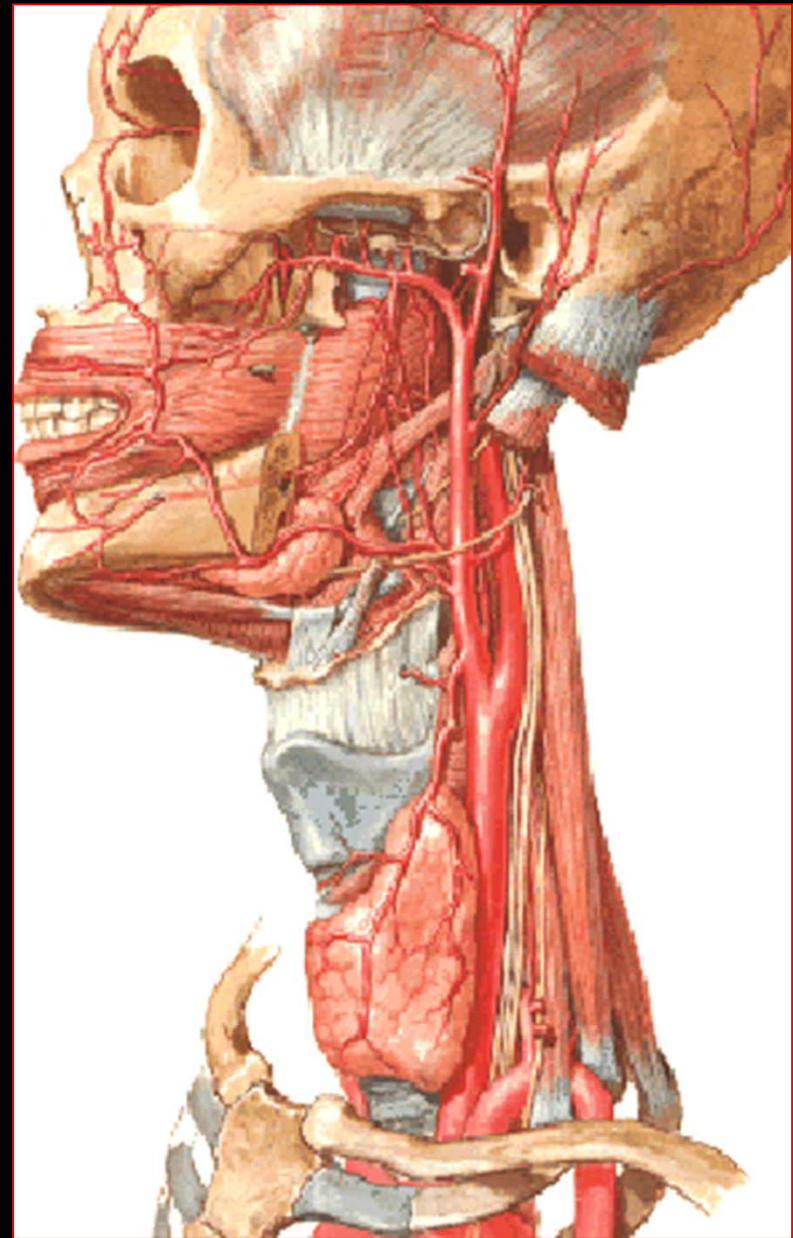
Branches

- 1-Suprahyoid
- 2-Dorsal lingual artery
- 3-Deep lingual
- 4-Sublingual artery



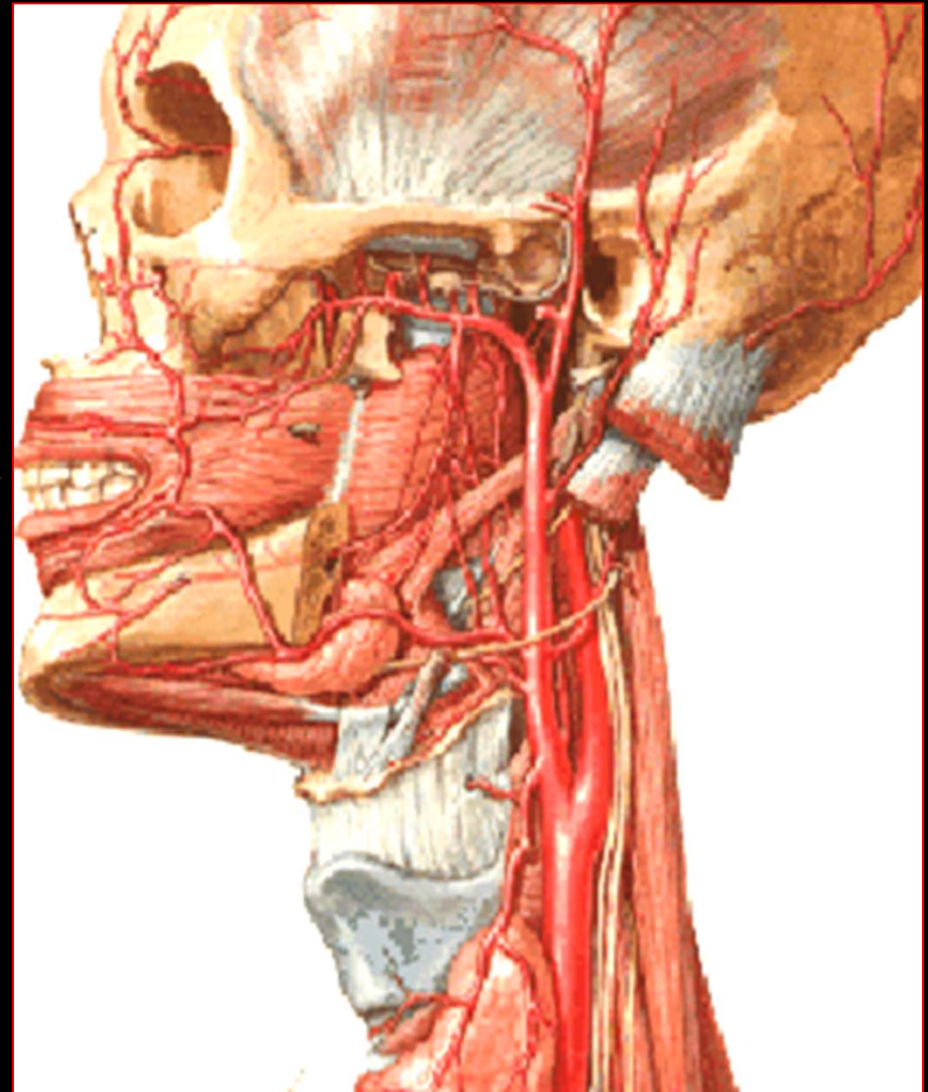
4- facial artery

- arises just distal to the lingual artery
- deep to post. Belly of dig m and stylohyoid m
- winds around the lower border of the mandible
- to enter the face at the anterior margin of masseter muscle
- passes upward and medially to end at medial angle of the eye



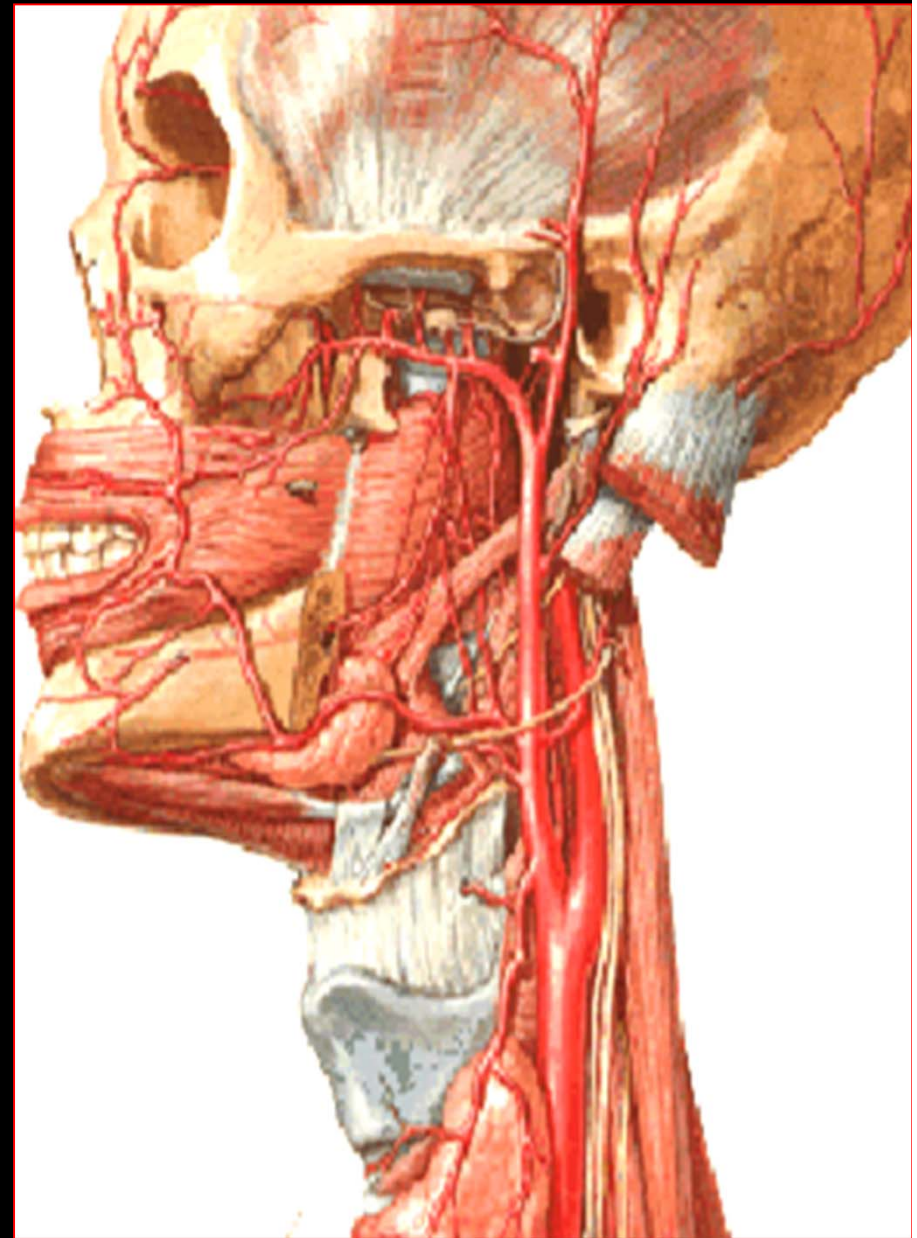
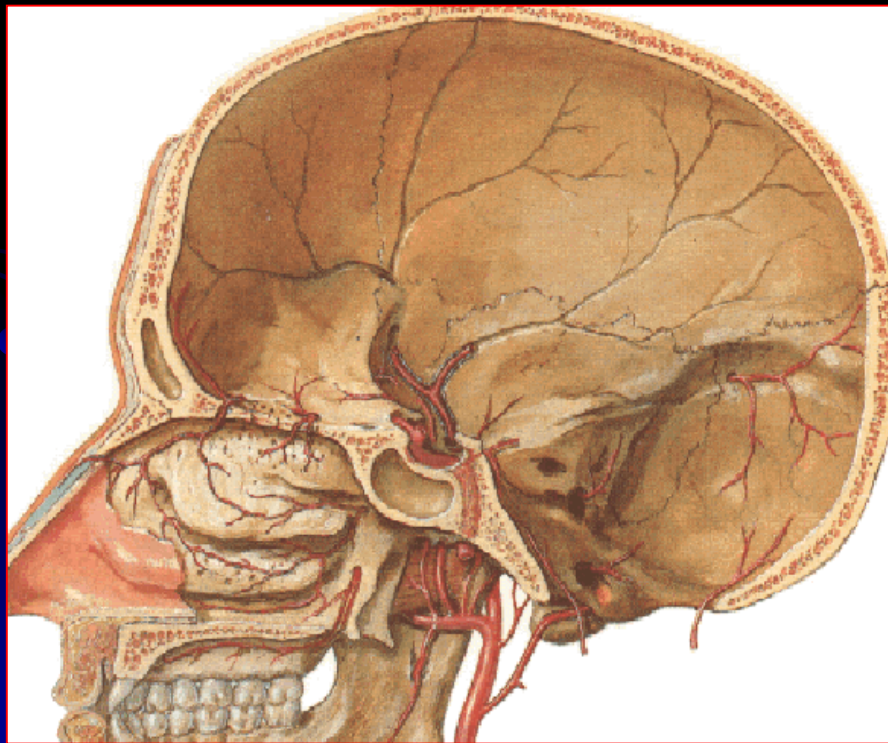
Branches

- 1- ascending palatine artery
- 2- **tonsillar artery**
superficial to the styloglossus m
pierces the sup.const.m
supplies the palatine tonsil
- 3- glandular branches
- 4- submental artery



5- occipital artery

- opposite the facial artery, back of the scalp
- passes posteriorly and superiorly
- Crosses lateral to the ICA, IJV, CN X, XI, and XII
- Grooves the temporal bone medial to the mastoid process



Branches

1-Sternomastoid branch

2-Meningeal branch

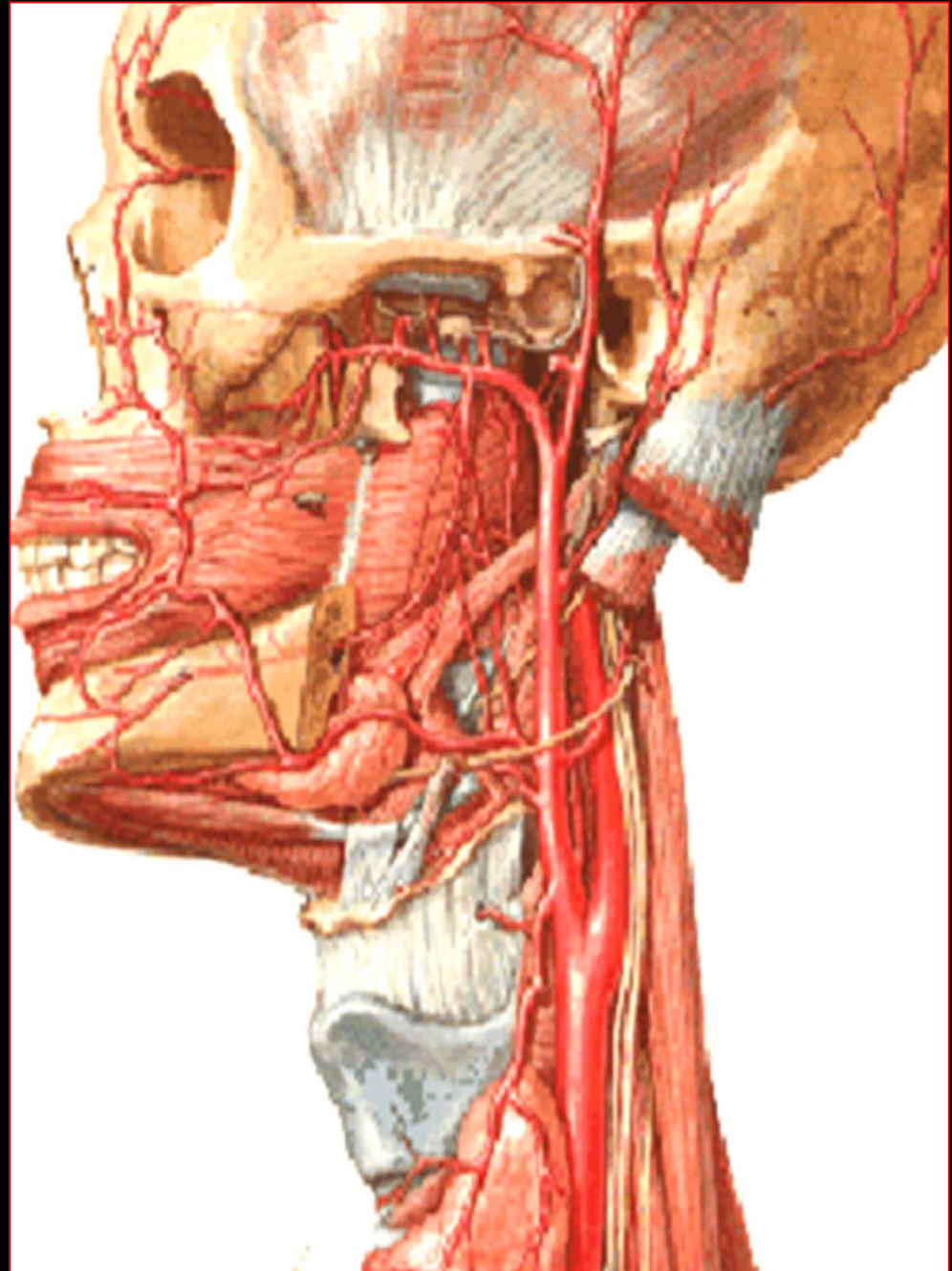
3-Descending branch

provides important
collateral circulation with
the

- a- deep cervical artery

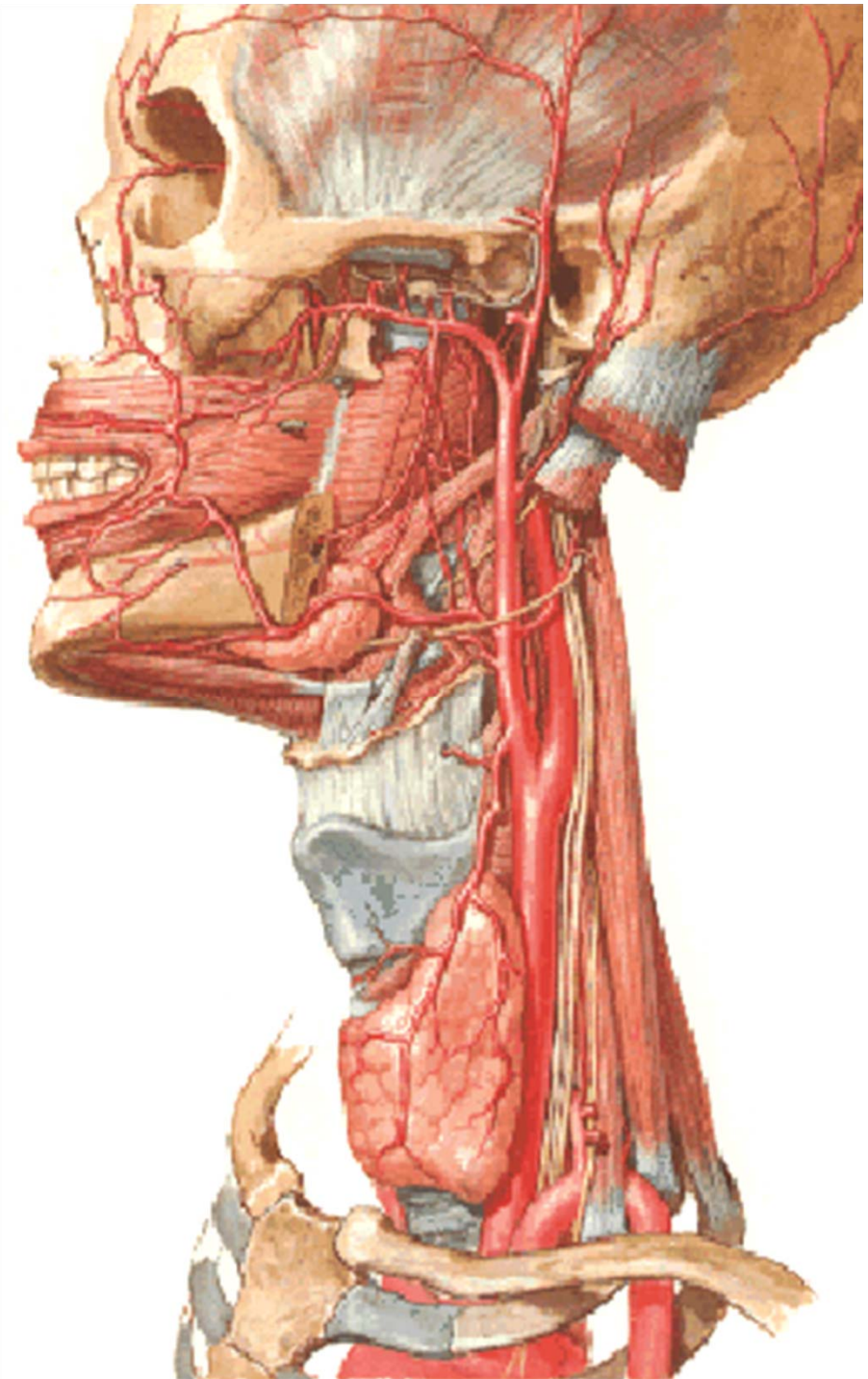
- b- superficial branch of
the transverse artery

4-Occipital branch



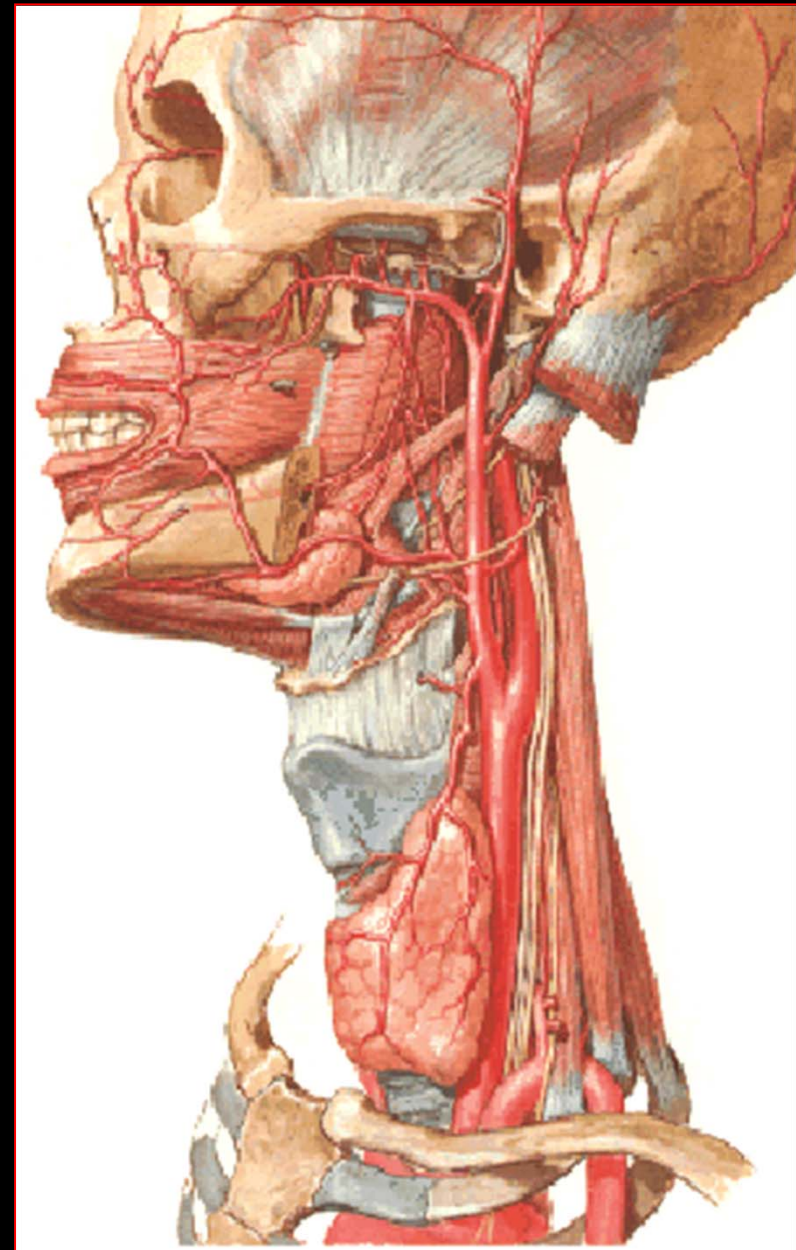6- posterior auricular a

- arises at the level of the upper border of the post. Belly the digastric
- Deep to the parotid gland and
- lateral to the styloid process
- ends post. To the external acoustic meatus on the
- superficial surface of the mastoid process



branches_

- 1- auricular branches
 - 2- occipital branches
 - 3- stylomastoid branch
- enter the stylomastoid foramen
supplies the
- a-facial nerve**
 - b- stapedius muscle**

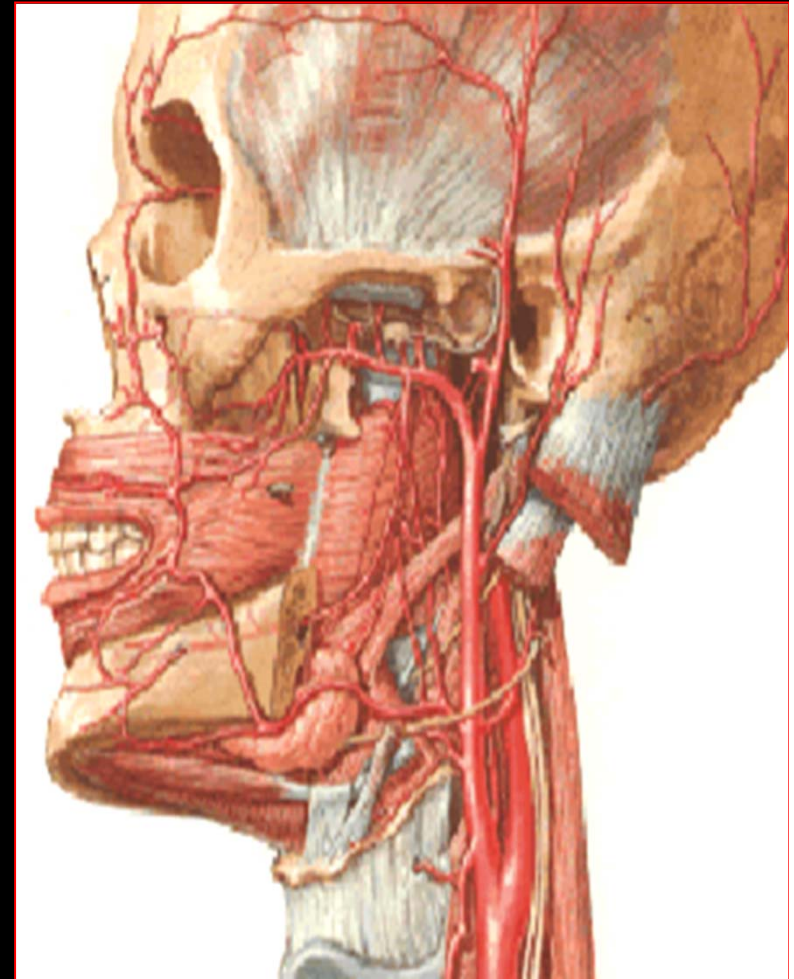


7- superficial temporal artery

- Is the smaller of the 2 terminal branches of the ECA
- Arises **deep to the neck of the mandible** in the substance of the parotid gland
- Ascends behind the TMJ
- anterior to the auricle

Supplies the

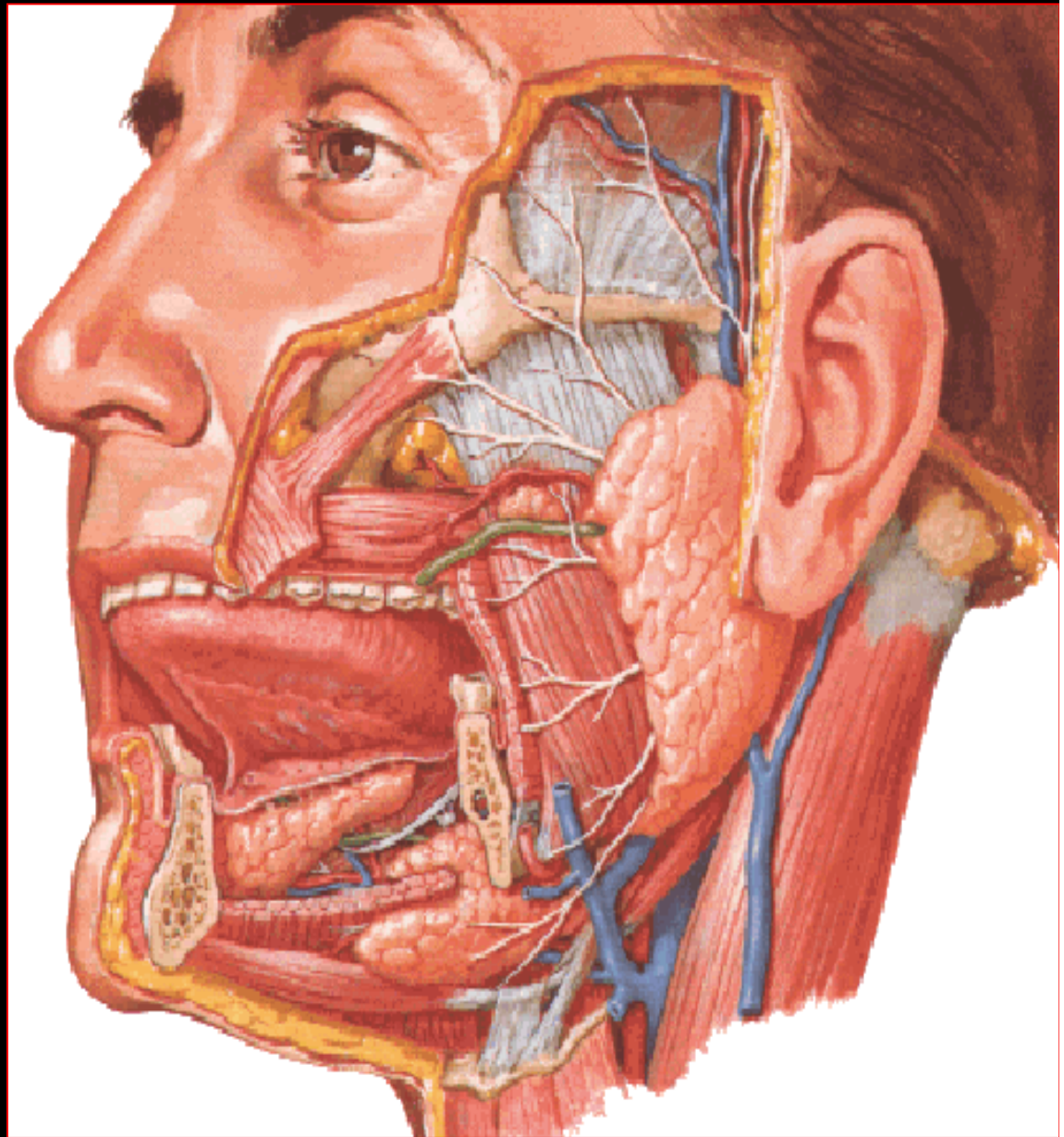
- a-face in front of the ear
- b- the scalp of the temporal region
- c- parotid gland
- Is accompanied by the
 - 1-auriculotemporal nerve**
 - 2-superficial temporal vein**



Branches

Transverse facial artery

Passes across the face b/w
-zygomatic arch and
-parotid duct

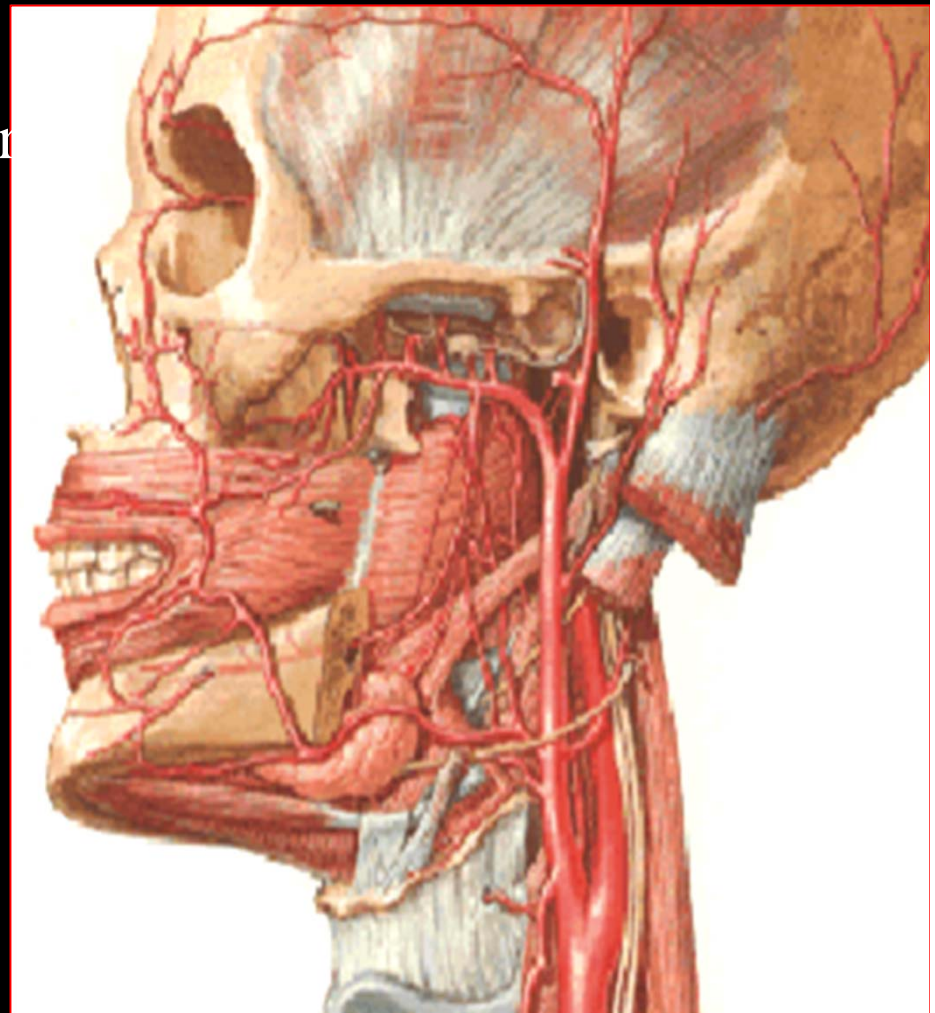


8- maxillary artery

- arises as a terminal branch of the ECA
- Deep to the neck of the mandible
- Within the substances of the parotid gland
- Traverses the infratemporal fossa and enters the pterigopalatine fossa
- through the pteriogomaxillary fissure

Supplies

- 1-the muscle of the mastication
- 2-the upper and lower jaws
- 3-The nasal cavity
- 4-The palate
- 5-The dura
- 6- the face

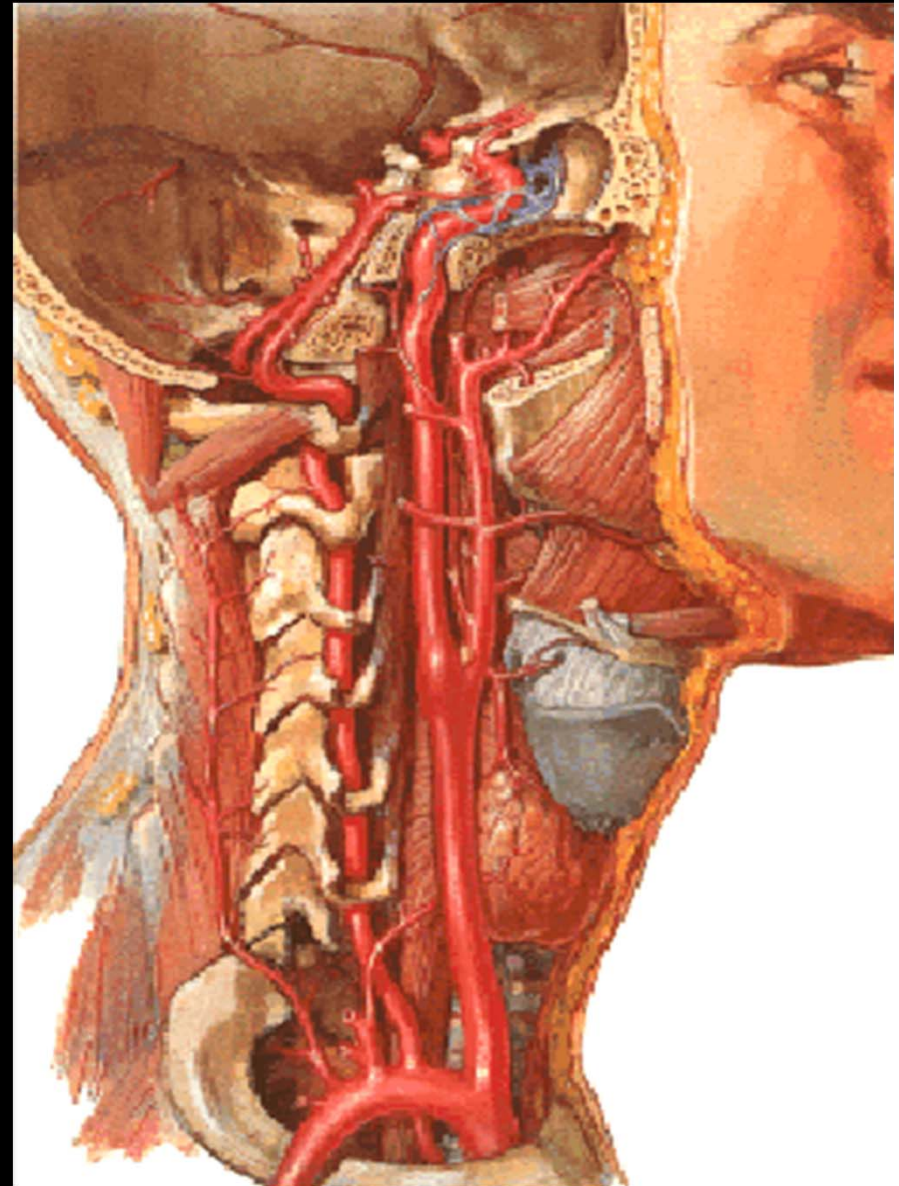


Internal Carotid A

- one of the terminal branches of the CCA
- enters the cranial cavity through the carotid canal
- ascends **deep to the parotid gland**
- gives off **NO branches** in the neck

supplies the

- 1-brain,
- 2-the eyes,
- 3-the forehead,
- 4-and part of the nose



Relations

Anterolaterally

- below the digastric m
skin, fascia, SCM and hypoglossal nerve
- above the digastric m
stylohyoid m , stylopharyngeus m ,
glossophary.n
pharyngeal branch of the vagus nerve,
the parotid g and the ECA

Posteriorly

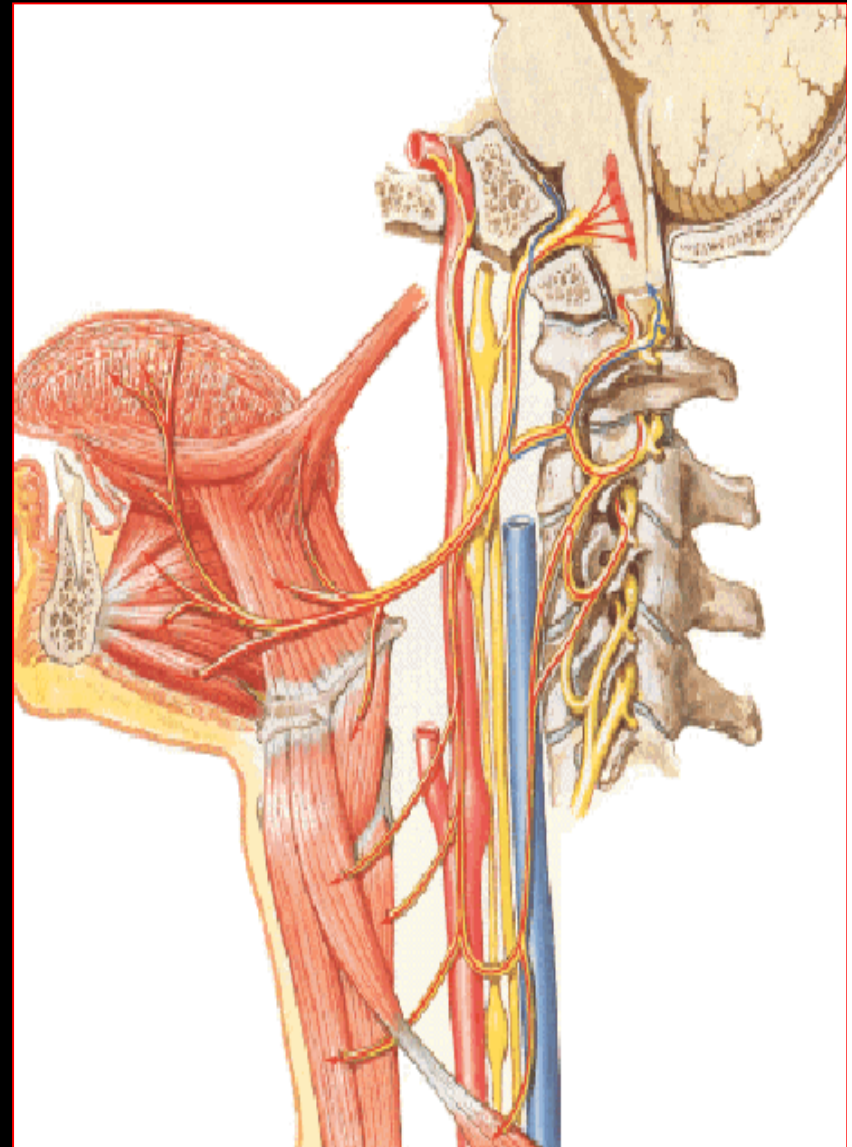
the sympathetic trunk, the longus capitis m,
transverse process of the upper 3 cervical
vertebrae

Medially

pharyngeal wall and the superior laryngeal nerve


Laterally

the internal jugular vein and the vagus nerve



Collateral circulation

- External carotid branches across the midline
- External carotid branches to the face and scalp and the extracranial branches of the ICA



- Bony landmarks and Surface Anatomy:

- I.Mastoid process

- II.Mandible

- A.Mental protuberance

- B.Angle

- III.Hyoid bone

- IV.Thyroid cartilage, laryngeal prominence

- V.Cricoid cartilage

- VI.Trachea

- VII.Jugular notch

- Cervical triangles:

- I.Anterior - Sternocleidomastoid, trapezius, mandible and midline

- A.Muscular - hyoid, sup. belly omohyoid, sternocleidomastoid

- B.Carotid - post. belly digastric, sup. belly omohyoid, sternocleidomastoid

- C.Submandibular - ant. and post. bellies of digastric, body of mandible

- D.Submental - ant. belly digastrics, hyoid bone

- II.Posterior - Trapezius, sternocleidomastoid, clavicle

- A.Subclavian (Omoclavicular) - inf. belly omohyoid, clavicle, sternocleidomast.

- B.Occipital - trapezius, sternocleidomastoid, inf. belly omohyoid

- Organization of fascial layers:

- I.Superficial - subcutaneous tissue - contains platysma muscle and cutaneous veins and nerves

- II.Deep cervical fascia:

- A.Superficial (investing) layer of deep cervical fascia - encloses trapezius and sternocleidomastoid.

- B.Infrahyoid (muscular) fascia - deep to sup. layer of deep, encloses infrahyoid (strap) muscles

- C.Carotid sheath - encloses carotid arteries, int. jugular v. and vagus n.

- D.Visceral fascia - encloses trachea, esophagus & thyroid

- Pretracheal - anterior, encloses thyroid and parathyroids

- Buccopharyngeal - back of pharynx

- E.Retropharyngeal space - interfascial plane between visceral and prevertebral

- F.Prevertebral fascia - encloses vertebral column and associated. m. (scalenes, etc.) roots of brachial and cervical plexi, sympathetic trunk.

- Muscles:

- I.Platysma: subcutaneous, muscle of facial expression

- II.Sternocleidomastoid and trapezius muscles

- III.Infrahyoid (strap): act on larynx and pharynx

- A.Omohyoid (superior & inferior bellies)

- B.Sternohyoid

- C.Sternothyroid

- D.Thyrohyoid

- IV.Cricothyroid (laryngeal muscle)

- Nerves:

- I.Cervical plexus:

- A.Sensory (cutaneous): all emerge from posterior border of sternocleidomastoid m.

- Lesser occipital
 - Great auricular
 - Transverse cervical
 - Supraclavicular

- B.Motor branches

- Ansa cervicalis
 - Phrenic

- II.Cervical branch of facial n. (CN VII) to platysma

- III.Vagus nerve (X) branches

- A.External branch of superior laryngeal n. to cricothyroid

- B.Internal branch of superior laryngeal n. goes to interior of larynx

- IV.Hypoglossal nerve (XII) - motor to tongue

- Vessels:

- I.Superficial veins

- A.External jugular

- B.Anterior jugular

- C.Communicating

- D.Jugular venous arch

- II.Deep veins

- A.Internal jugular v. - in carotid sheath

- III.Common & external carotid arteries

- A.Superior thyroid a.

- IV.Inferior thyroid a. - to thyroid gland, branch of thyrocervical trunk

- Thyroid gland: endocrine glands control general metabolism, secrete thyroxin

- I.Right and left lobes

- II.Isthmus - connection between lobes

- III.Pyramidal lobe

- Parathyroid glands - endocrine glands, spatially related to thyroid gland (NOT functionally)

- Clinical Terms:

- I.Goiter - enlargement of thyroid gland

- II.Tracheostomy - creation of an airway in the trachea, usually an elective procedure


- III.Cricothyrotomy - creation of an emergency airway between thyroid and cricoid cartilages

- IV.Thyroidectomy - removal of thyroid

- V.Thyroglossal duct cyst - a cyst along the tract of descent of the thyroid gland

- VI.Torticollis - torsion or twisting of the neck and elevation of the chin due to shortening of sternocleidomastoid m.

veins of the neck



Internal jugular vein

- Receives blood from

 - 1-brain

 - 2- face

 - 3-neck

- Begins at jugular foramen

As a continuation of the sigmoid venous sinus

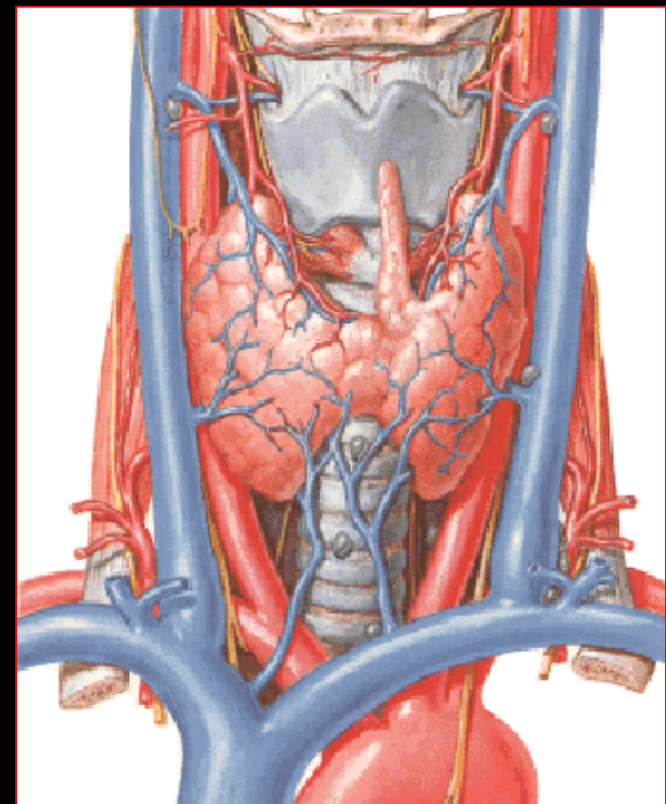
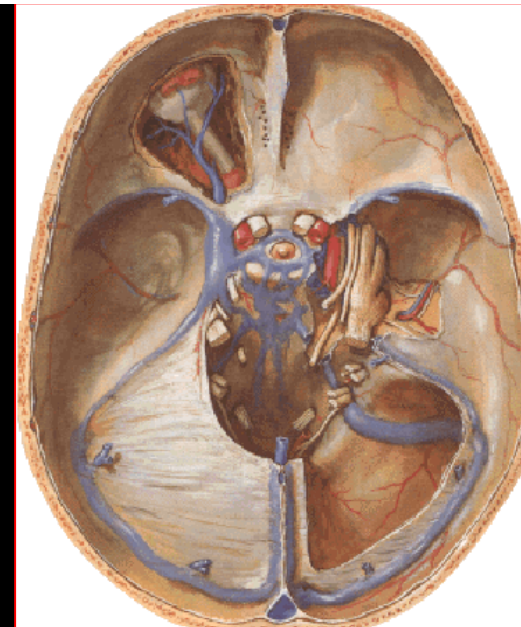
- Descends within the carotid sheath

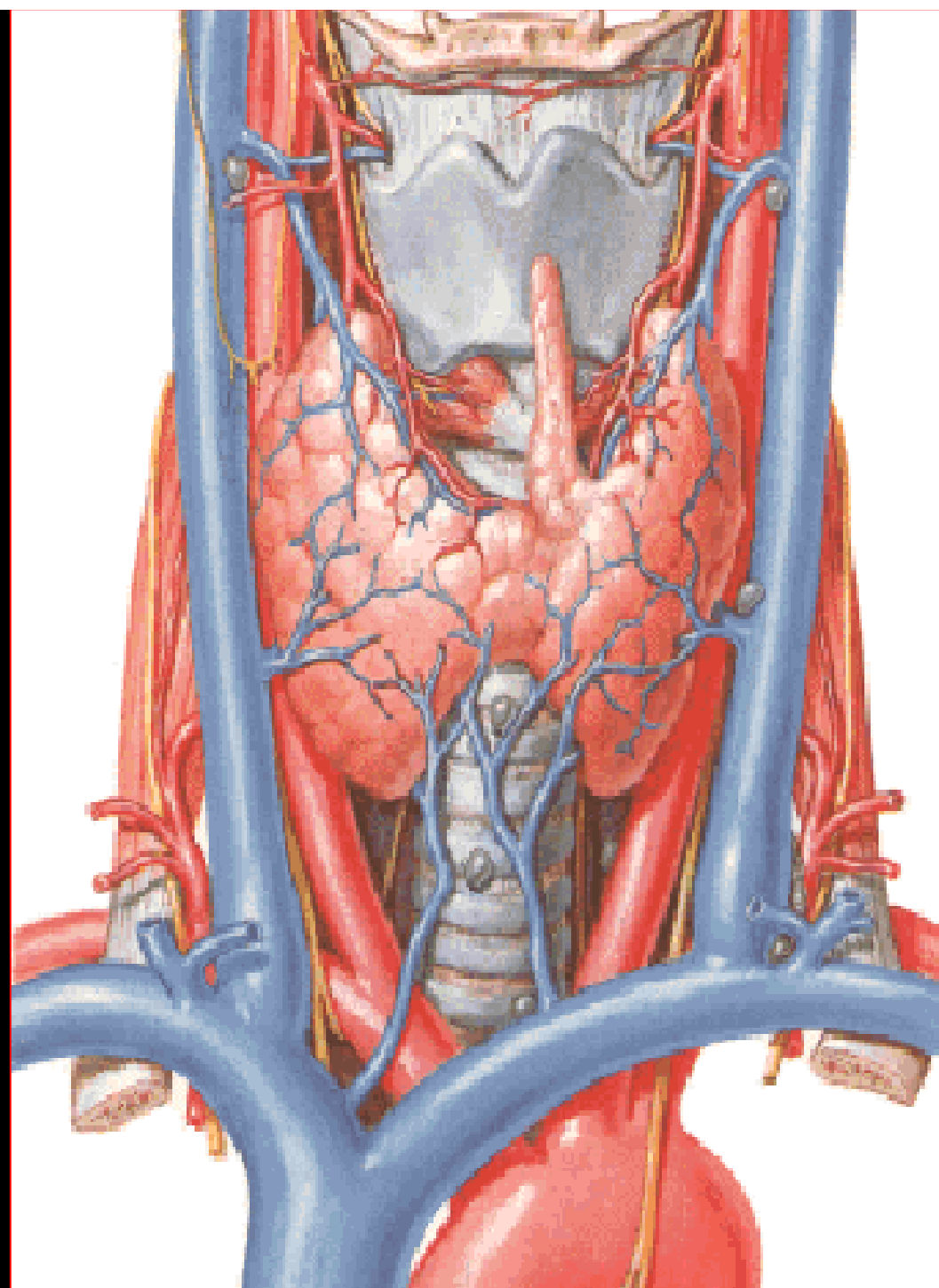
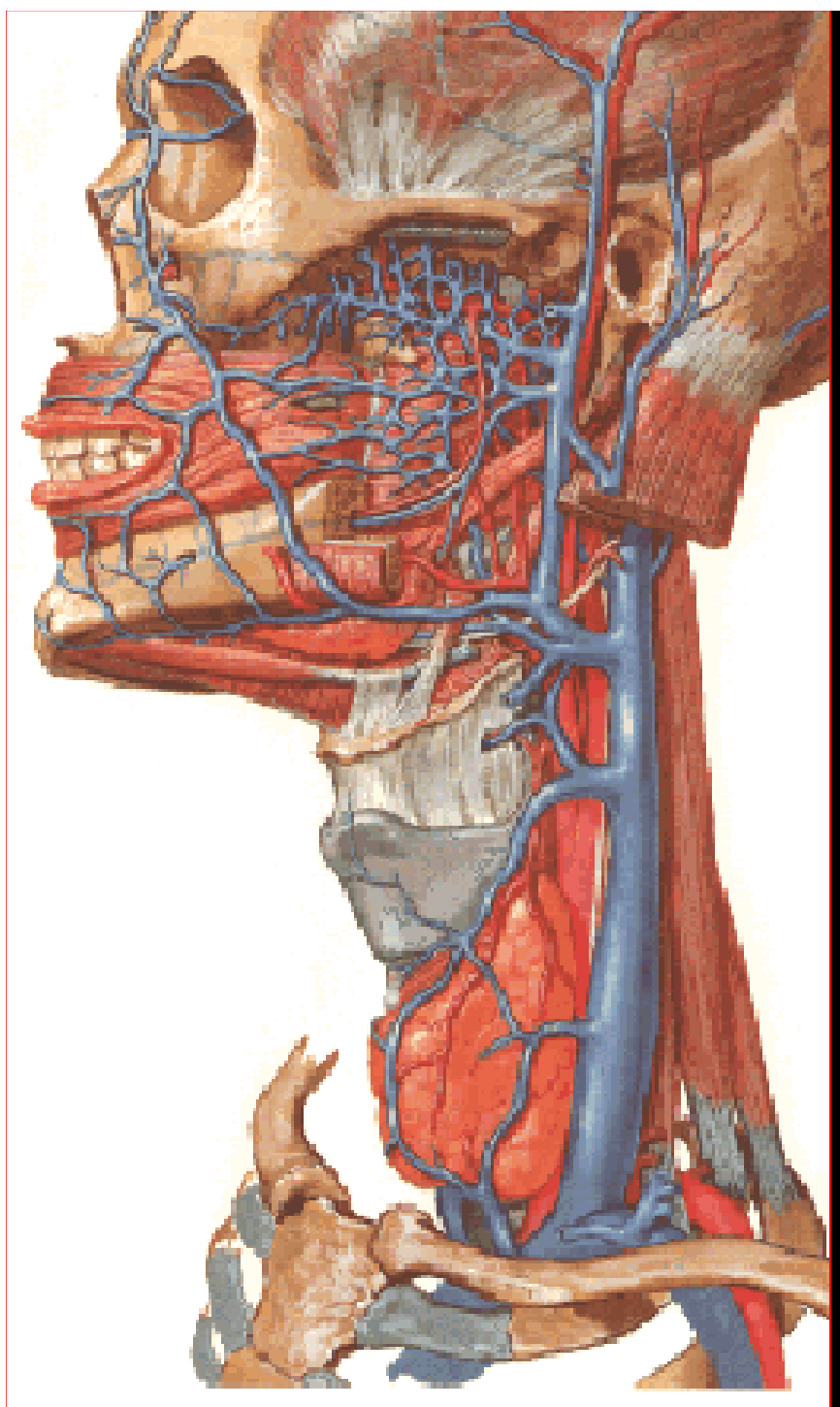
Lateral to the ICA and CCA

- Ends behind the medial end of the clavicle
by joining the subclavian vein

to form the brachiocephalic vein

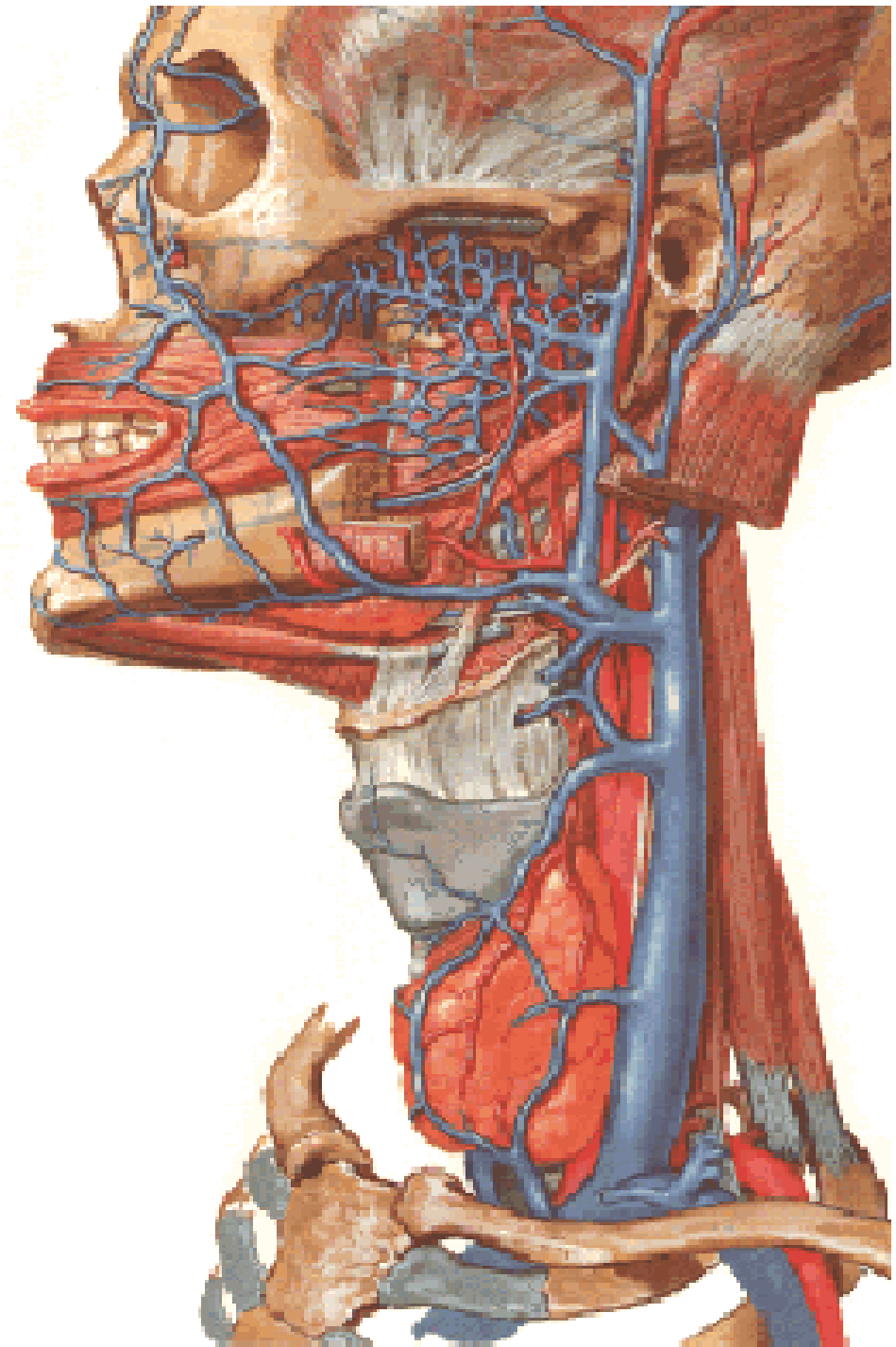
- Usually has a single valve
located just above the inferior bulb





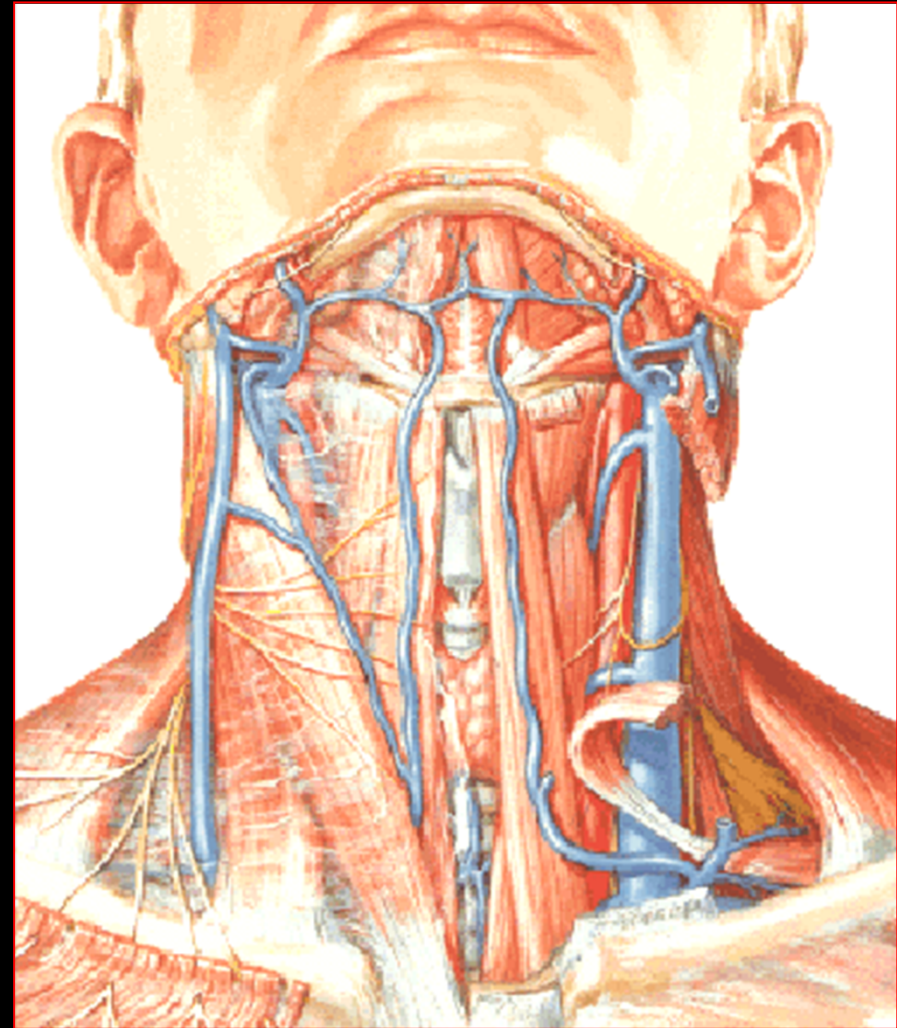
Tributaries

- 1) **Inferior petrosal sinus**
drains the cavernous sinus
- 2) **Facial vein**
- 3) **pharyngeal vein**
drain the pharyngeal
plexus
- 4) **Lingual vein**
- 5) **Superior thyroid vein**
- 6) **Middle thyroid vein**
- 7) **Occipital vein**



Anterior jugular vein

- Begins in the submandibular region
- Ends in the EJV
- Just above the jugular notch of the sternum may be connected to the opposite vein by a jugular venous arch



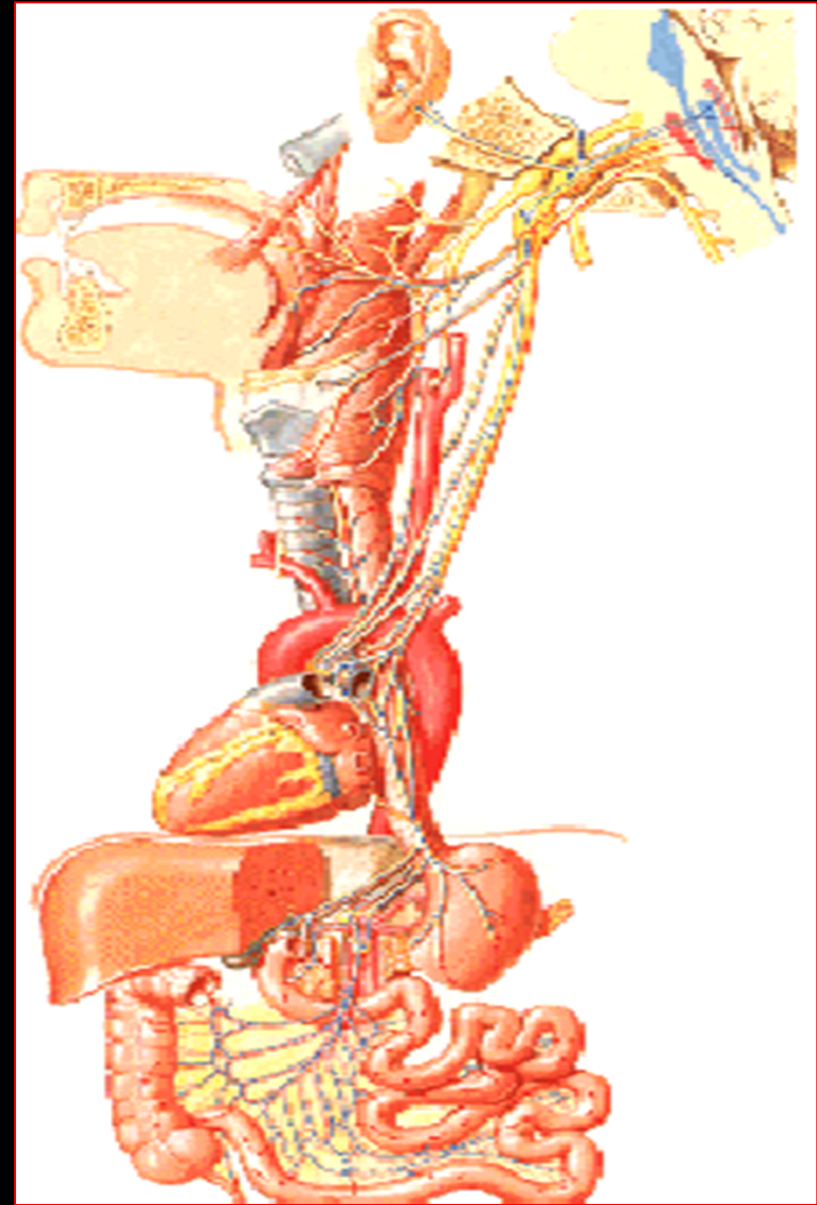
Cranial Nerves of the neck

Vagus nerve CN 10

Hypoglossal

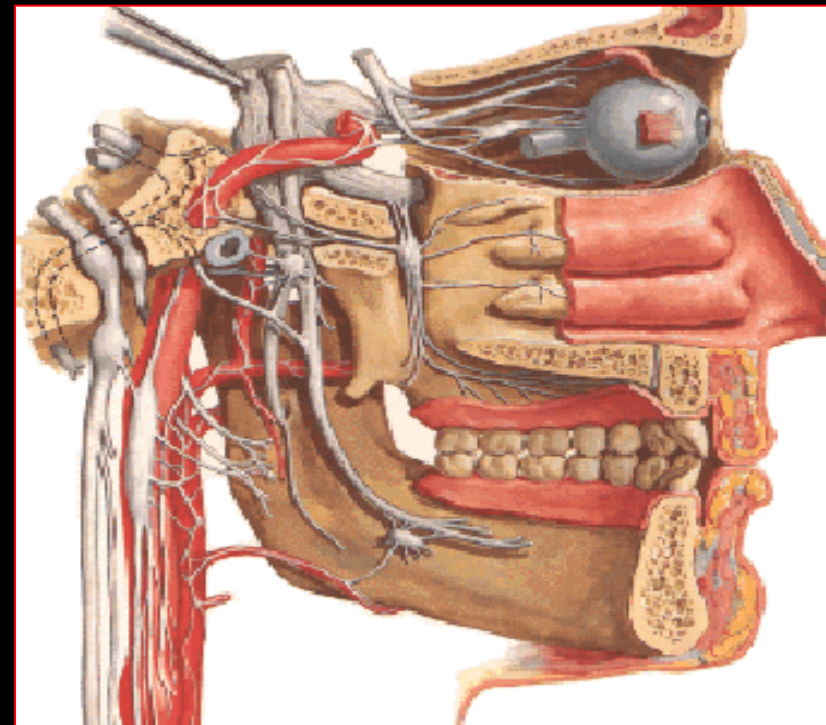
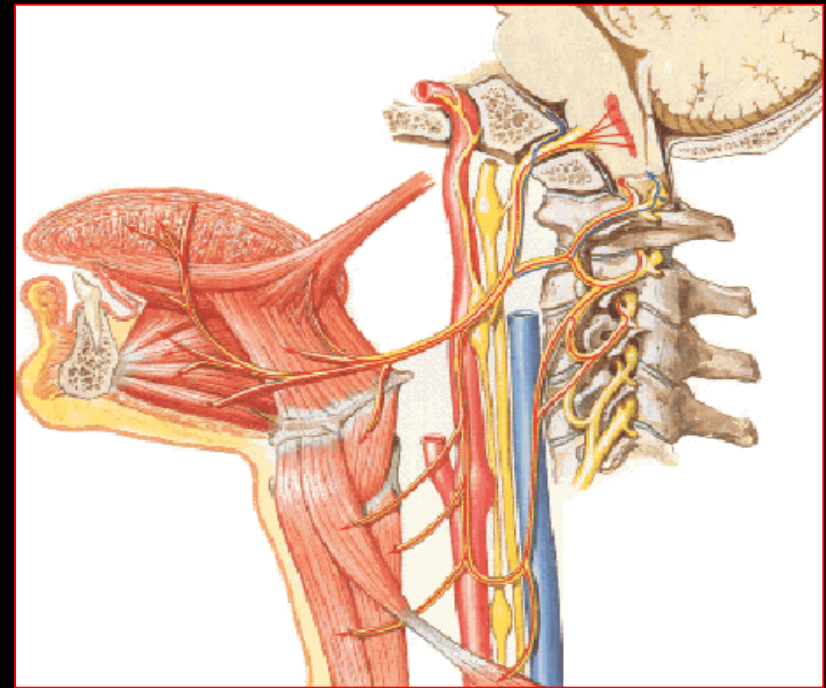
Glossopharyngeal

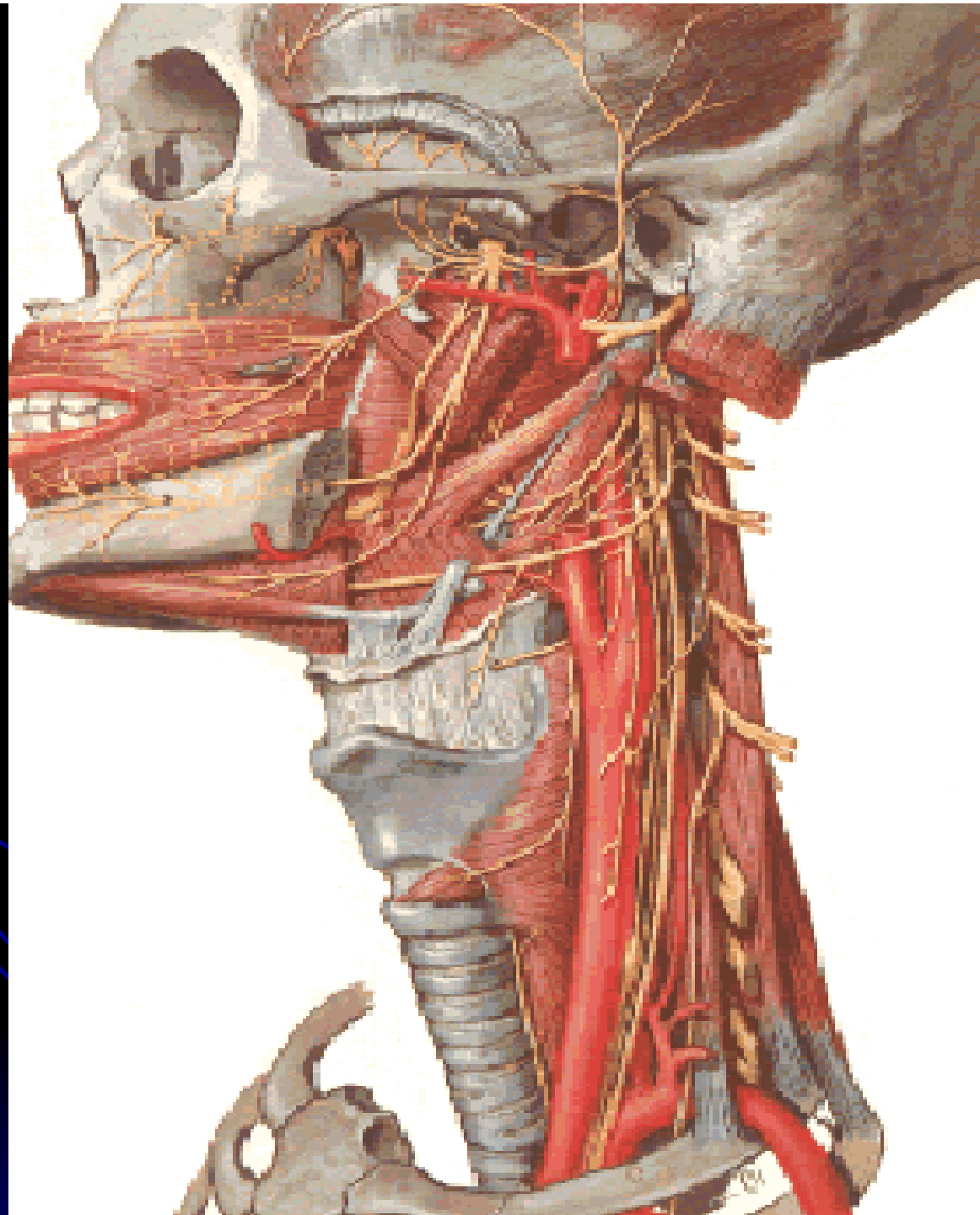
Spinal accessory



Vagus nerve

- mixed nerve
- medulla oblongata → jugular foramen → sup. And inf. ganglion (sensory)
- is joined below the inf. Ganglion by the cranial root of the XI
- descends vertically in the neck
- within the carotid sheath
- lies posterior b/w IJV and ICA then b/w IJV and CCA
- then ant. To the 1st part of the subclavian artery





branches

1-meningeal branch

2-auricular branch

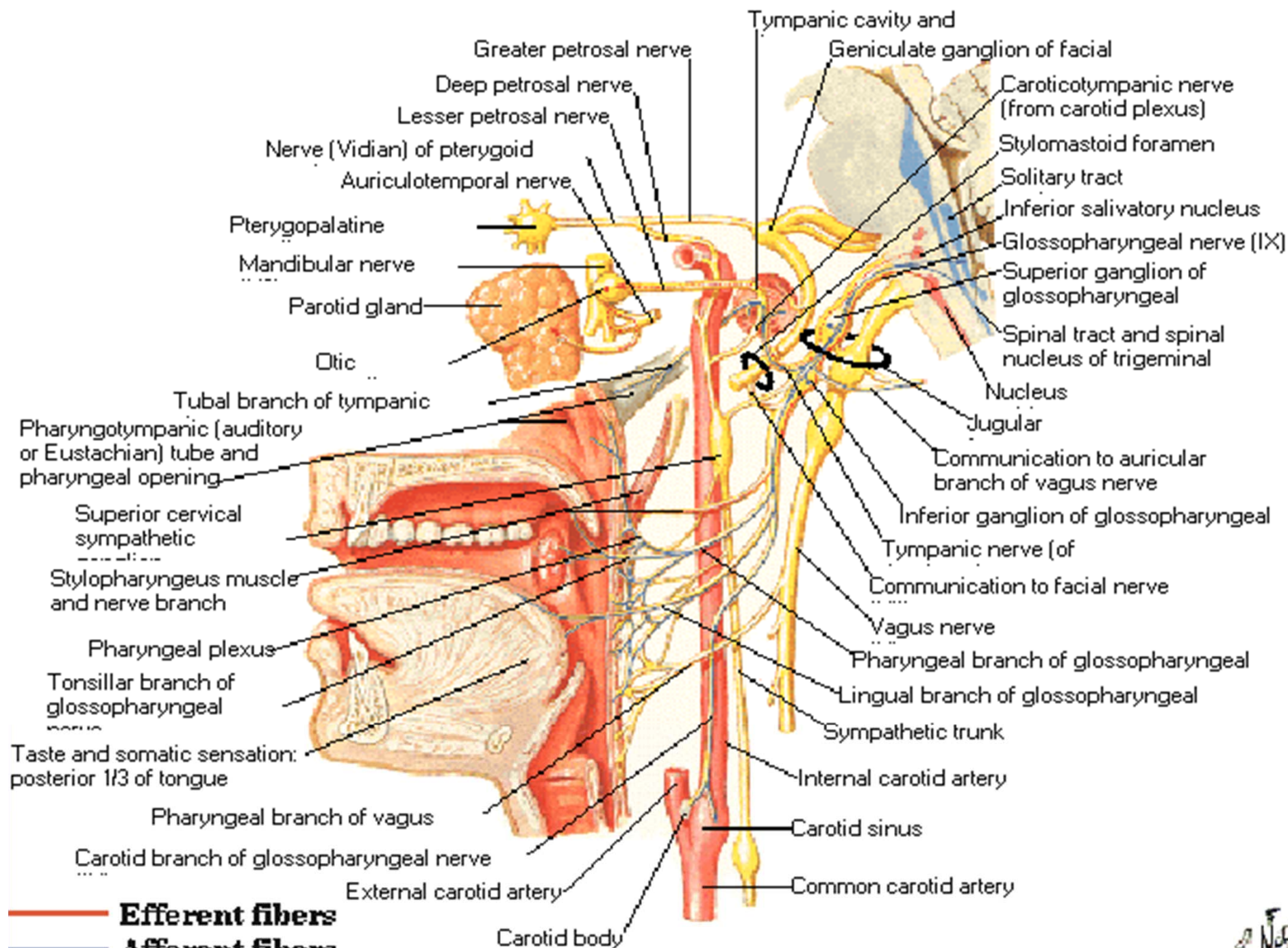
GSA innervation of the external ear and the tympanic membrane

3- pharyngeal branch

contains motor fibers from cranial part of the accessory nerve. It joins the branches from the glossopharyngeal nerve & sympathetic to form the pharyngeal plexus

- all the muscle of the pharynx except the stylopharyngeus (CN9)

- all the muscles of the soft palate except tensor veli palatini (V3)



4- superior laryngeal nerve:

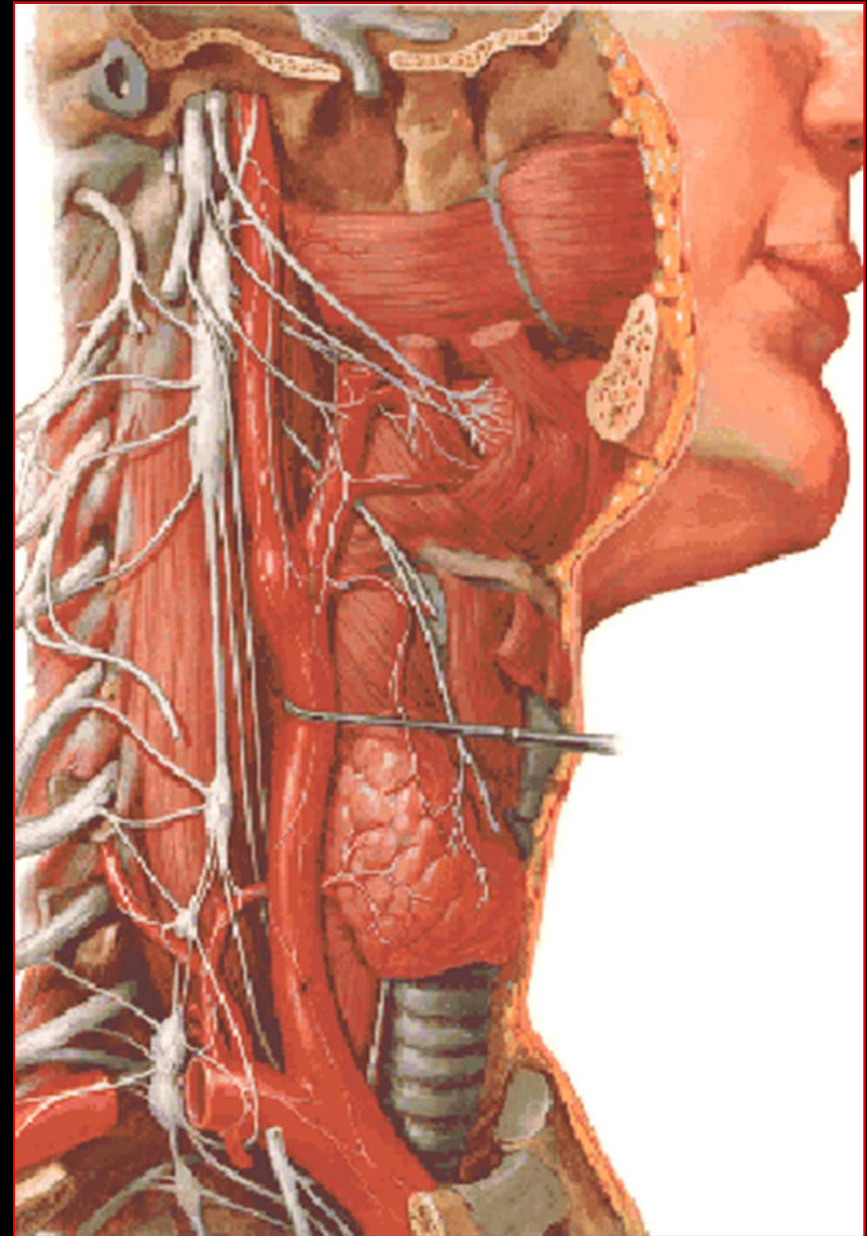
A- internal laryngeal nerve

(sensory)pierces the
thyrohyoid membrane,
along with the
superior laryngeal artery

B-External laryngeal nerve:(motor)

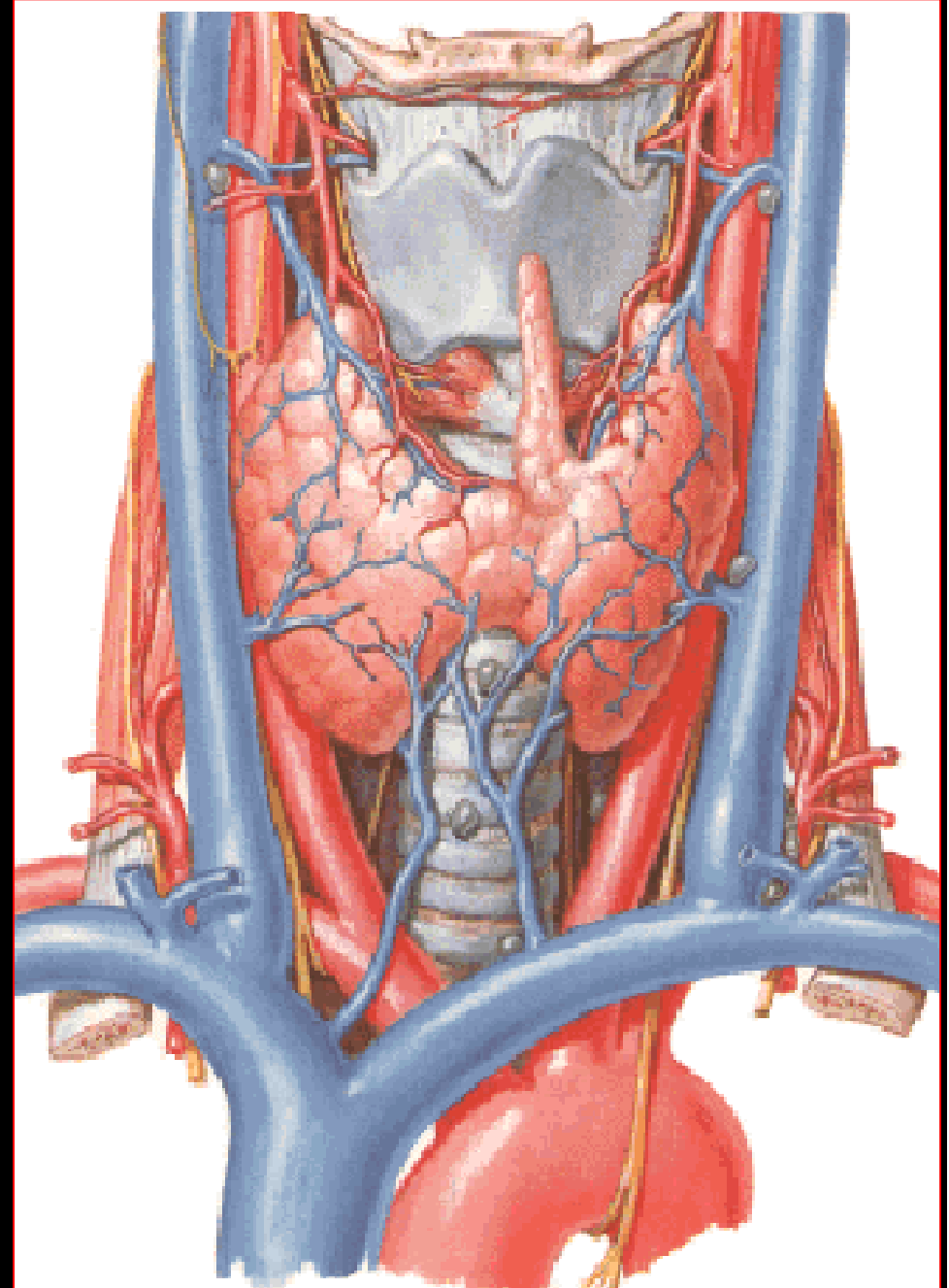
cricothyroid muscle
runs along the
superior thyroid artery

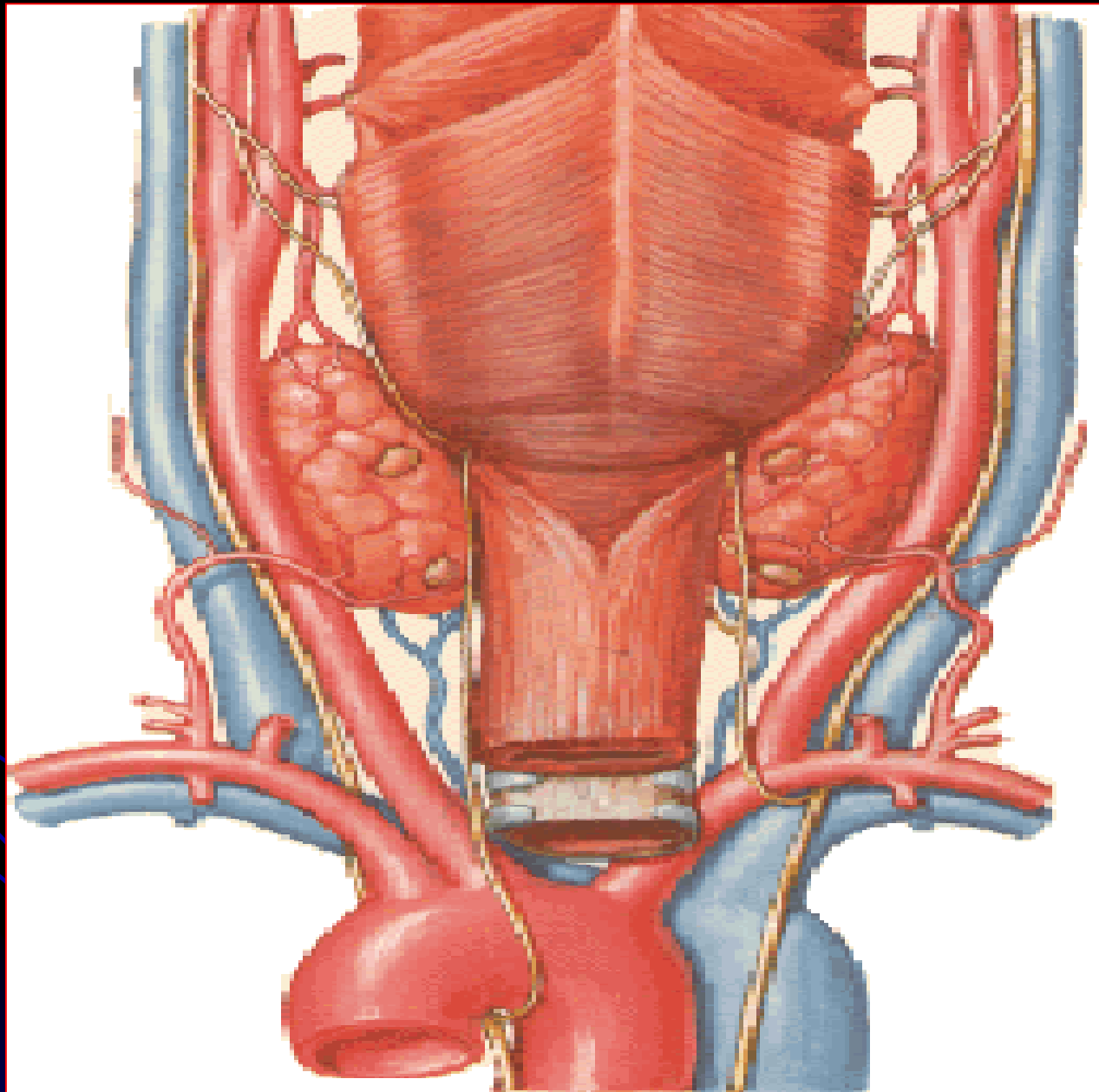
5- 2or3 cardiac branches: cardiac plexus



6- Recurrent laryngeal N

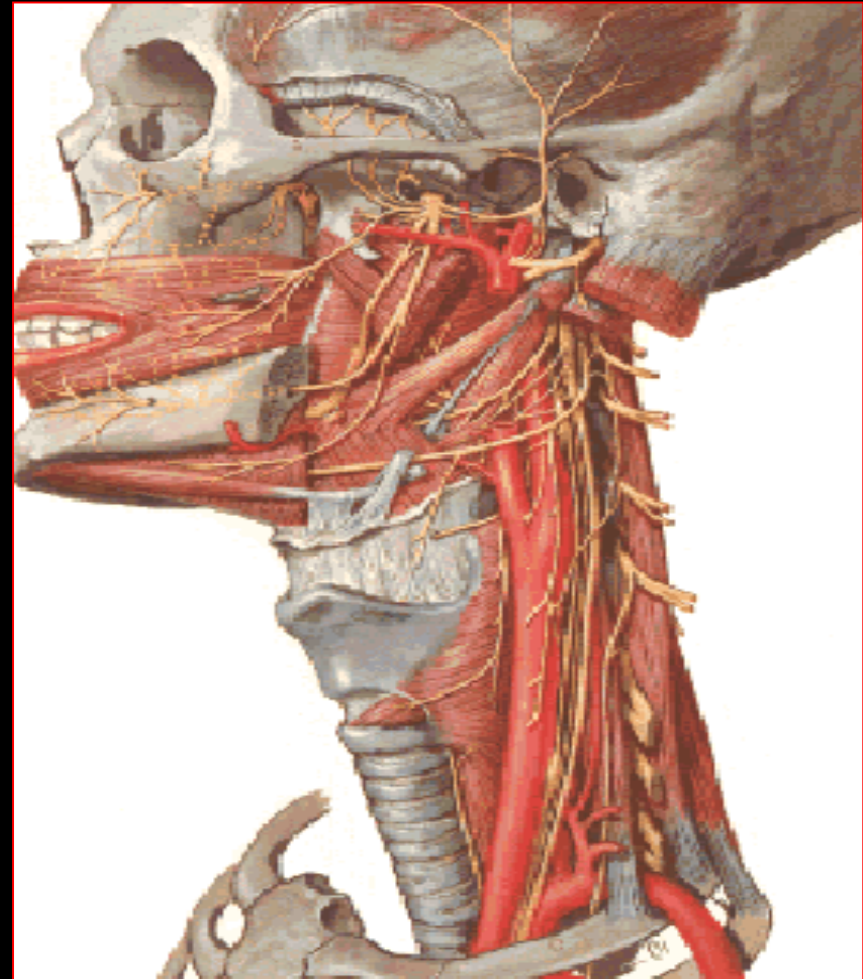
- hooks behind the
 - a- subclavian artery (Rt vagus)
 - b-of the aorta (Lt vagus)
- ascends in groove b/w
 - 1-the trachea
 - 2-the esophagus
- deep to the lobe of the thyroid
- close to the inf.thyroid artery

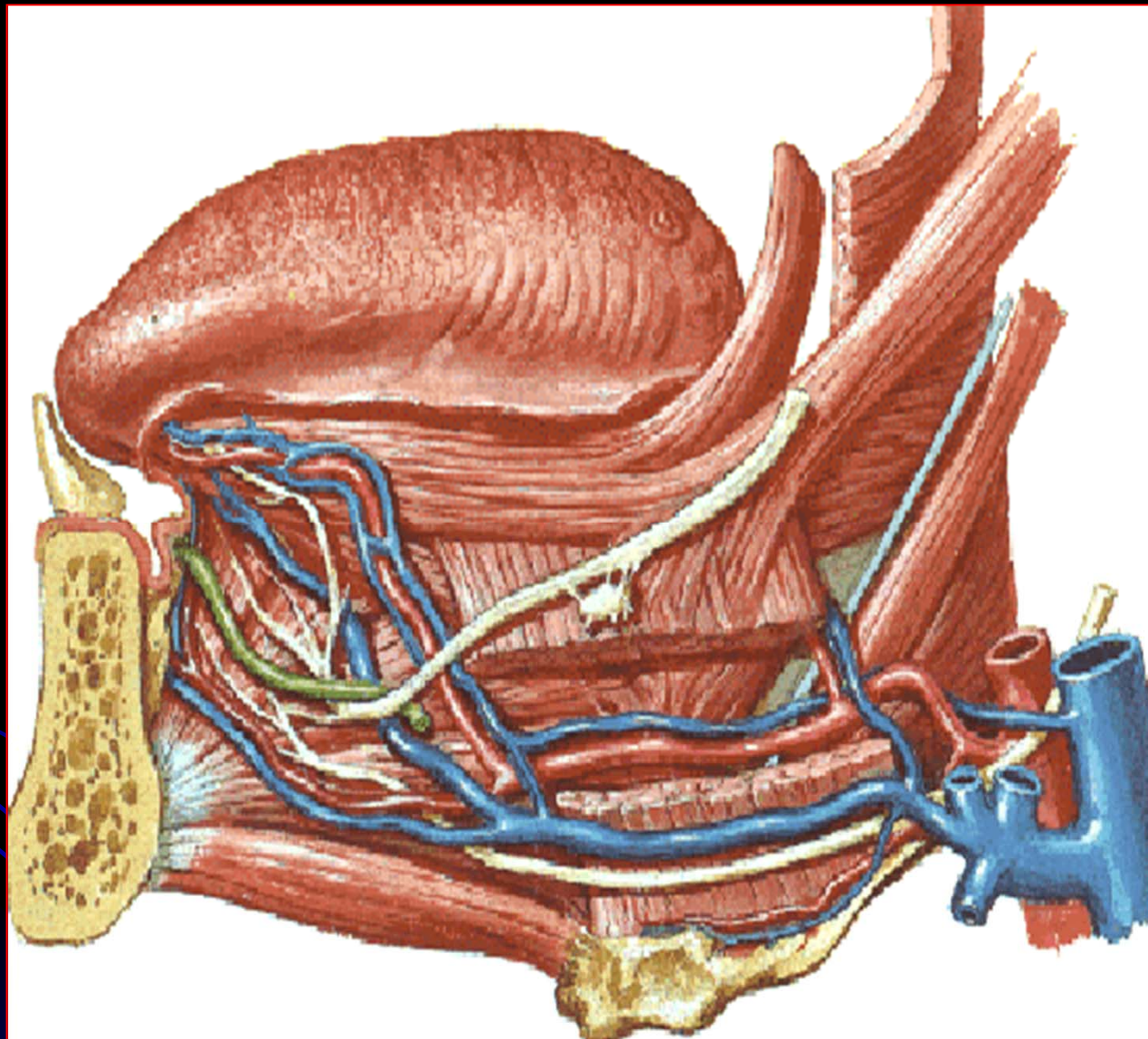





Hypoglossa nerve

- Passes below post belly of dig m
- Enters tongue between hyoglossus and mylohyoid
- Supplies muscles of the tongue except palatoglossus





Lymph drainage of the head and neck



-Directly or indirectly to the deep cervical group of nodes

-Some of which form a circular collar at the junction of the head and neck

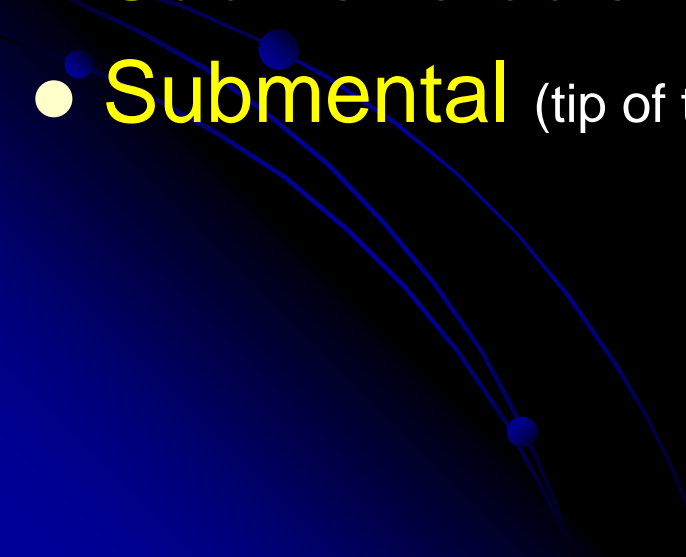
-Is collected by the jugular lymph trunk

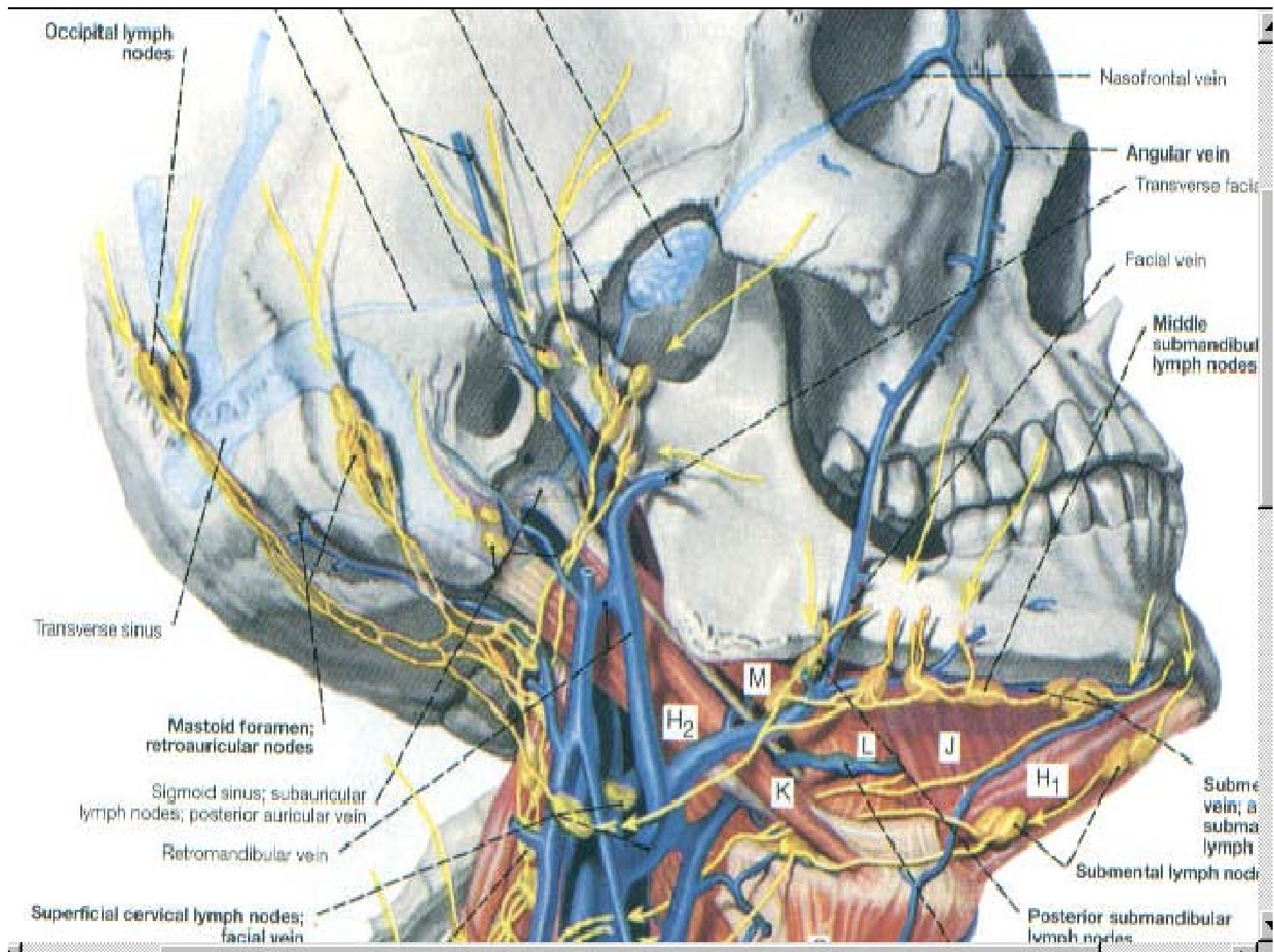
a- on the left side usually joins the thoracic duct

b- on the right side either joins the right lymphatic

duct or empties independently at the junction of the IJV and subclavian vein

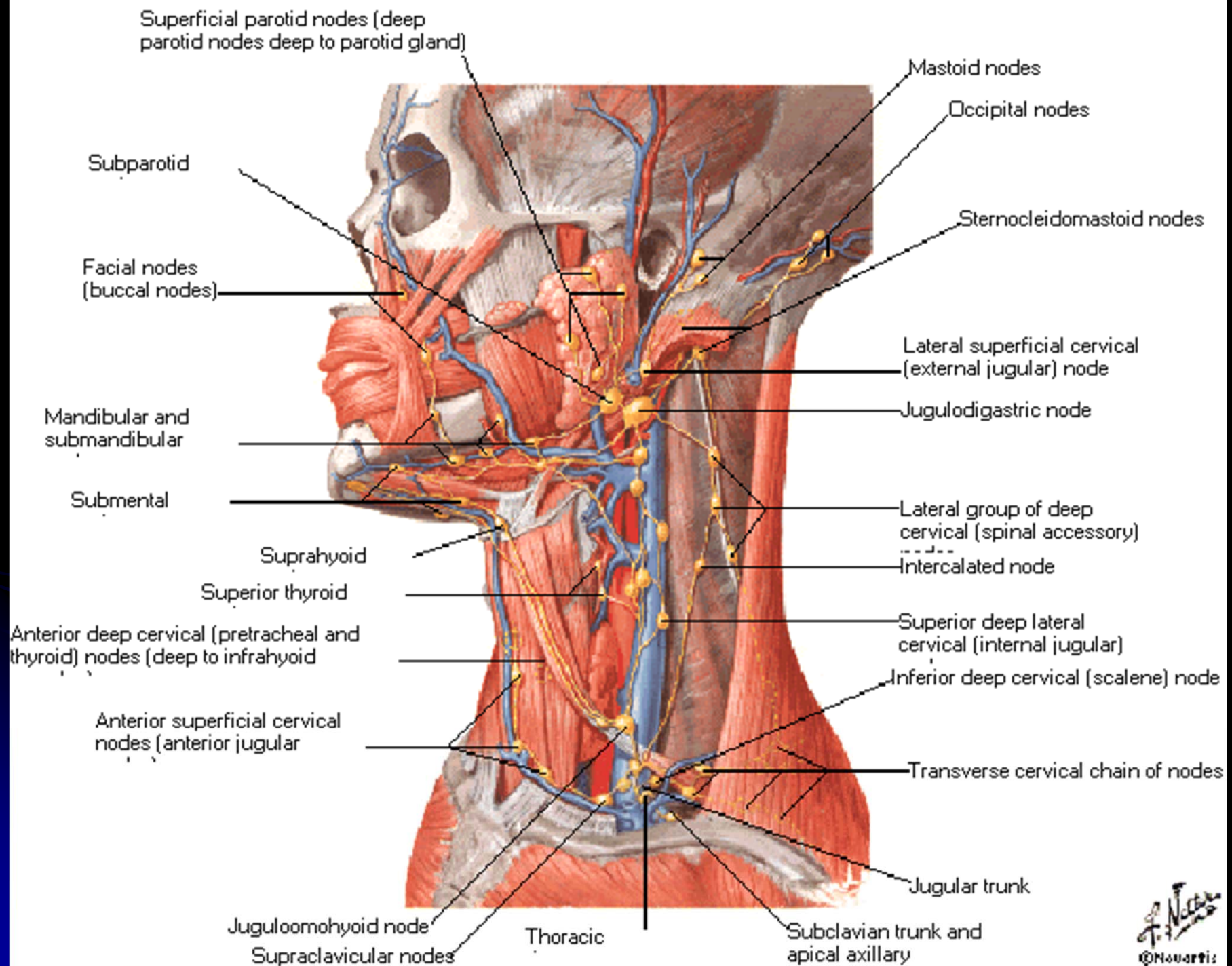
Horizontal group

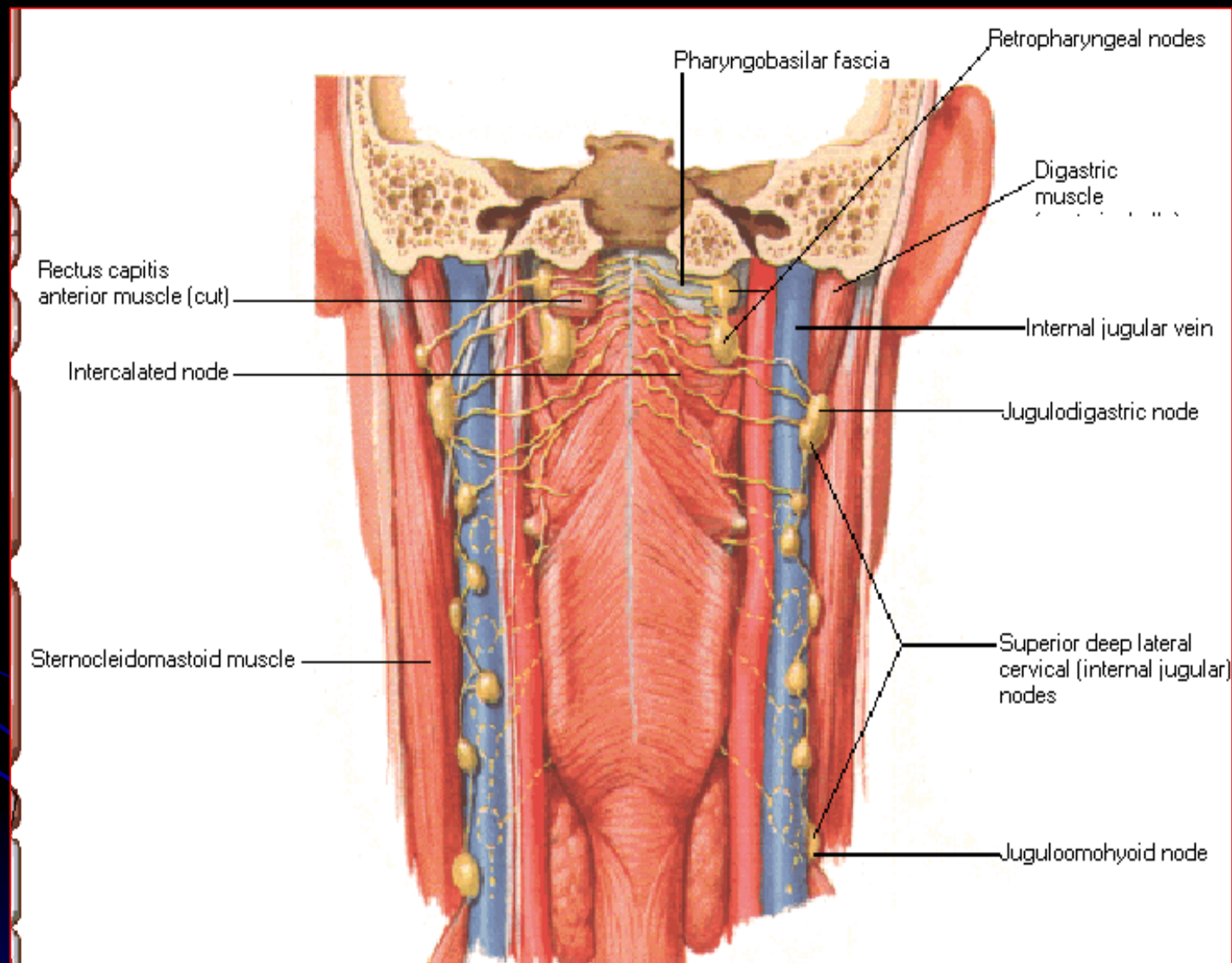
- **Suboccipital** (back of scalp and neck)
 - **Mastoid** (post scalp, auricle, and ext aud meatus)
 - **Parotid** (ant scalp, ext and middle ear, and parotid g)
 - **Submandibular** (scalp, face, and tongue)
 - **Submental** (tip of the tongue, floor of the mouth, lower lip, and chin)
- 

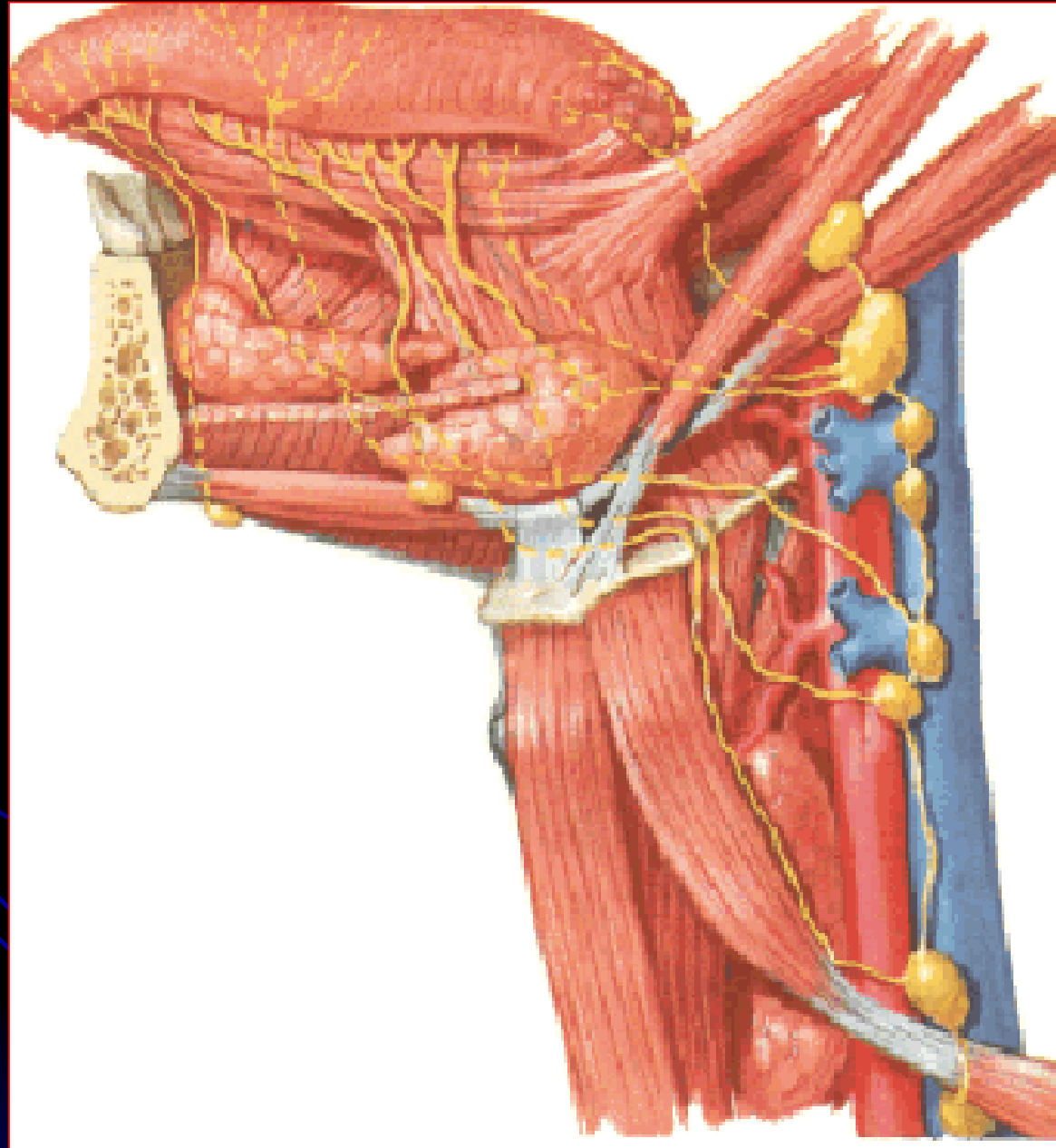


Vertical group

- **Tracheal** (trachea, larynx, thyroid, and superficial neck, below hyoid)
- **Retropharyngeal** (nasopharynx, auditory tube, and middle ear)
- **Superficial cervical** (along the EJV, lower parotid, auricle, mastoid, and angle of mandible)
- **Deep cervical** (along the IJV, entire head and neck, either directly or through regional LN)
 - **Superior group with jugulodigastric node**
(palatine tonsil and posterior 1/3 of the tongue, larynx, pharynx)
 - **Inferior group with jugulomohyoid node**
(ant 2/3 of tongue, larynx, thyroid g)







Jugulodigastric node

Is a large and constant member of the sup.group
of the deep cervical nodes

Lies at the point where the posterior belly
of the digastric m crosses the IJV

Drains the posterior third of the
tongue and the palatine tonsil

juguloomohyoid nodes

Is a large and constant member of the inferior group
of the deep cervical nodes

Lies above the intermediate tendon of the omohyoid m.
as it crosses the IJV

Drains the anterior 2/3 of the tongue