

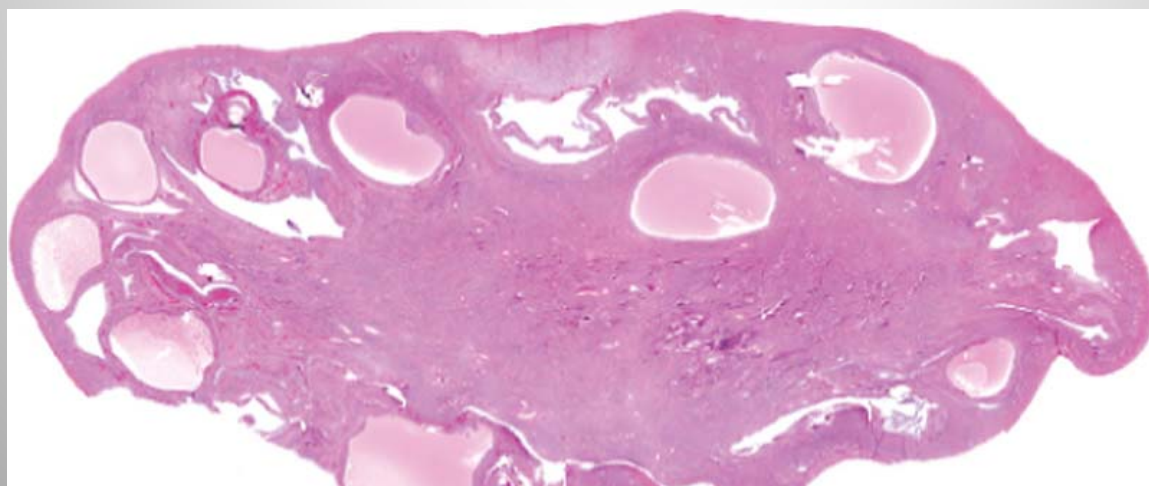
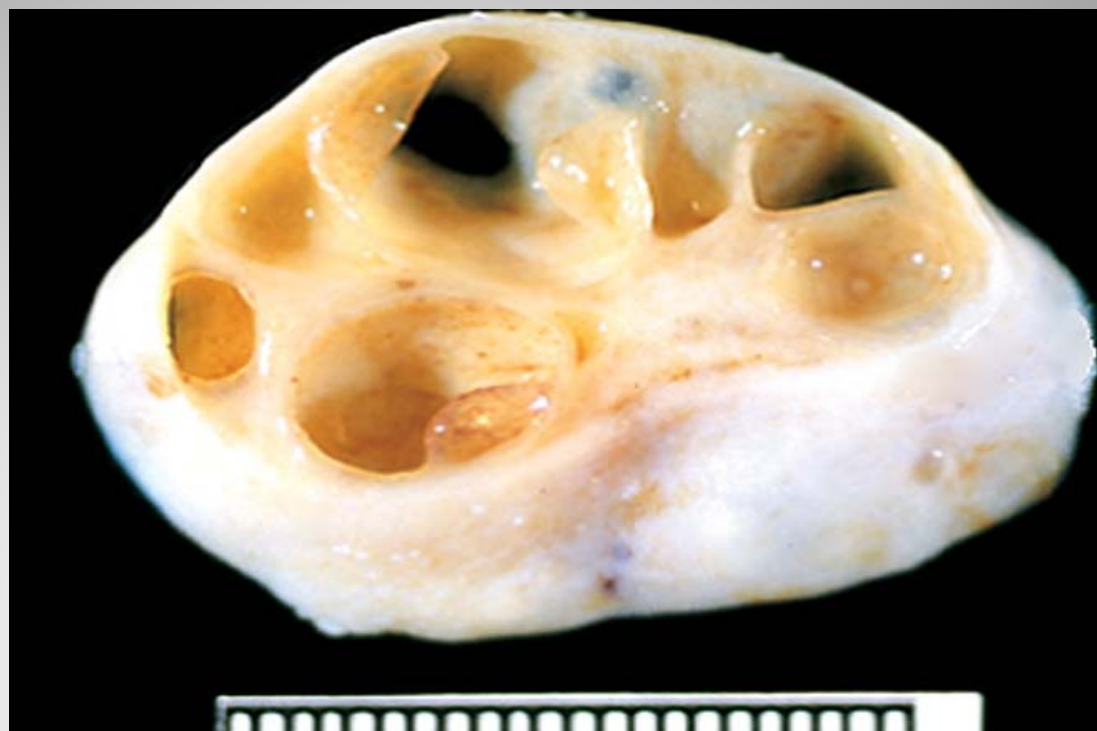DISEASES OF OVARY

HISTOLOGY

- The ovary has three main histologic compartments :
 - surface müllerian epithelium
 - germ cells
 - sex cord–stromal cells
- Each compartment gives rise to distinct non-neoplastic and neoplastic entities.

NON-NEOPLASTIC CYSTS

- ***Follicular cysts:*** They originate in unruptured graafian follicles or in follicles that have ruptured and immediately sealed.
- ***Granulosa luteal cysts (corpora lutea):*** are normally present in the ovary. These cysts are lined by a rim of bright yellow tissue containing luteinized granulosa cells.
- ***Polycystic ovarian disease:*** central pathologic abnormality is numerous cystic follicles or follicle cysts, often associated with oligomenorrhea. Women with PCOD have persistent anovulation, obesity, hirsutism and virilism.



OVARIAN TUMORS

- About 80% are benign
- Benign and borderline tumors occur at 20-45 years of age.
- Malignant tumors are more common in older women, between the ages of 45 and 65 years.
- Most ovarian cancers are detected when they have spread beyond the ovary, they account for a disproportionate number of deaths from cancer of the female genital tract.

Clinical features

- Abdominal pain, distention, vaginal bleeding, urinary and gastrointestinal tract symptoms due to compression by the tumor or cancer invasion are the most common symptoms.
- Most are nonfunctional, some may be hormonally active.

CLASSIFICATION

- According to the most probable tissue of origin.
- It is now believed that tumors of the ovary arise ultimately from one of three ovarian components.

WHO Classification of Ovarian Neoplasms

SURFACE EPITHELIAL-STROMAL TUMORS

- Serous tumors
 - Benign (cystadenoma)
 - Borderline tumors (serous borderline tumor)
 - Malignant (serous adenocarcinoma)

- Mucinous tumors, endocervical-like and intestinal type
 - Benign (cystadenoma)
 - Borderline tumors (mucinous borderline tumor)
 - Malignant (mucinous adenocarcinoma)
- Endometrioid tumors
 - Benign (cystadenoma)
 - Borderline tumors (endometrioid borderline tumor)
 - Malignant (endometrioid adenocarcinoma)

- Clear cell tumors
 - Benign
 - Borderline tumors
 - Malignant (clear cell adenocarcinoma)
- Transitional cell tumors
 - Brenner tumor
 - Brenner tumor of borderline malignancy
 - Malignant Brenner tumor
 - Transitional cell carcinoma (non-Brenner type)
- Epithelial-stromal
 - Adenosarcoma and Malignant mixed müllerian tumor

SEX CORD-STROMAL TUMORS

- Granulosa tumors
- Fibromas - Thecomas
- Sertoli cell tumors
- Leydig cell tumors
- Sex cord tumor with annular tubules
- Gynandroblastoma
- Steroid (lipid) cell tumors

GERM CELL TUMORS

- Teratoma
 - Immature
 - Mature
 - Solid
 - Cystic (dermoid cyst)
 - Monodermal (e.g., struma ovarii, carcinoid)
- Dysgerminoma
- Yolk sac tumor (endodermal sinus tumor)
- Mixed germ cell tumors

MALIGNANT, NOT OTHERWISE SPECIFIED

METASTATIC CANCER FROM NON-OVARIAN PRIMARY

- Colonic, Appendiceal, Gastric, Breast

SURFACE EPITHELIAL TUMORS

SURFACE EPITHELIAL TUMORS

- The classification of epithelial tumors of the ovary is based on both differentiation and extent of proliferation of the epithelium.
- There are three major histologic types based on the differentiation of the neoplastic epithelium: serous, mucinous, and endometrioid tumors.
- The extent of epithelial proliferation is associated with the biologic behavior of the tumor and is classified as
 - benign (minimal epithelial proliferation),
 - borderline (moderate epithelial proliferation), and
 - malignant (marked epithelial proliferation with stromal invasion).

Serous Tumors

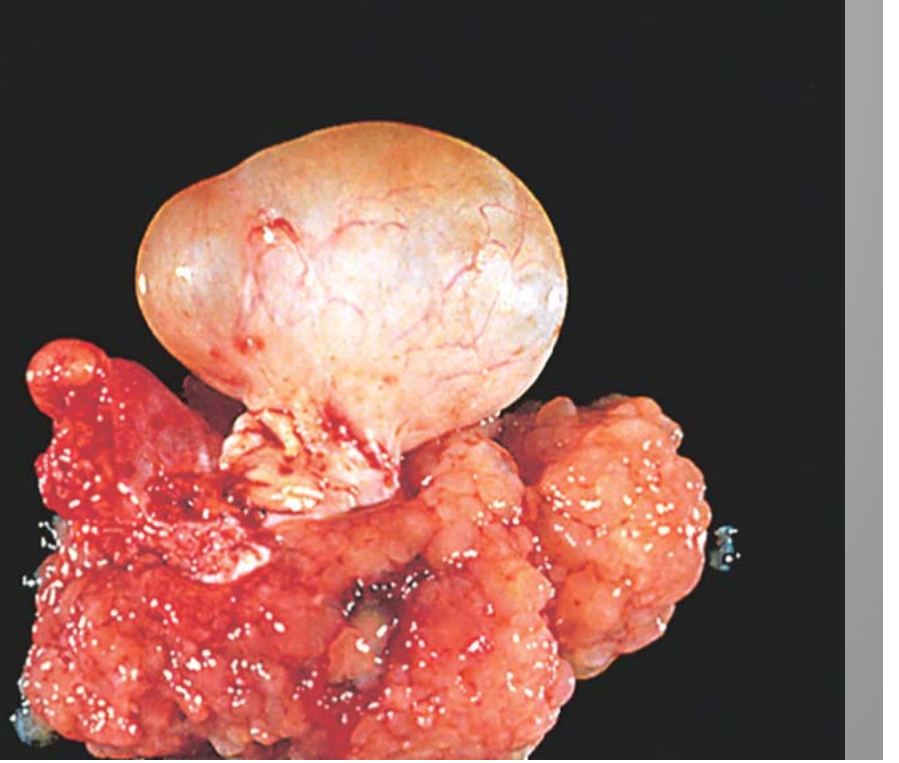
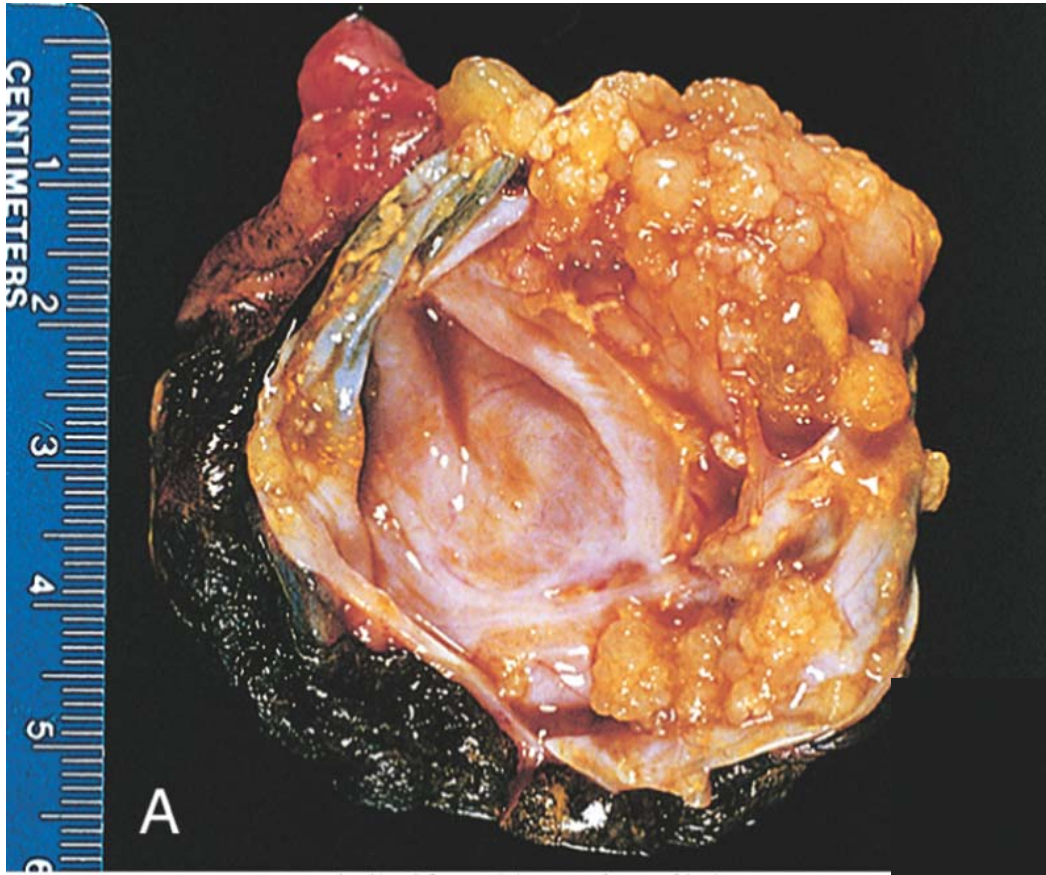
- These common cystic neoplasms are lined by tall, columnar, ciliated and nonciliated epithelial cells and are filled with clear serous fluid.
- Serous carcinomas account for approximately 40% of all cancers of the ovary and are the most common malignant ovarian tumors.
- Benign and borderline tumors are most common between the ages of 20 and 45 years. Serous carcinomas occur later in life on average.

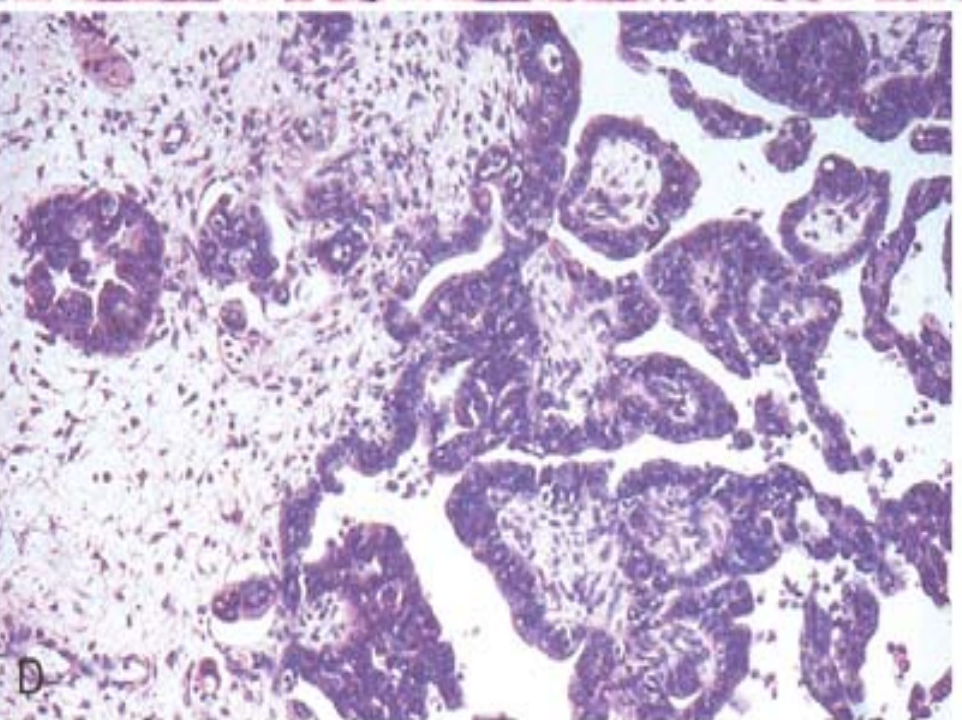
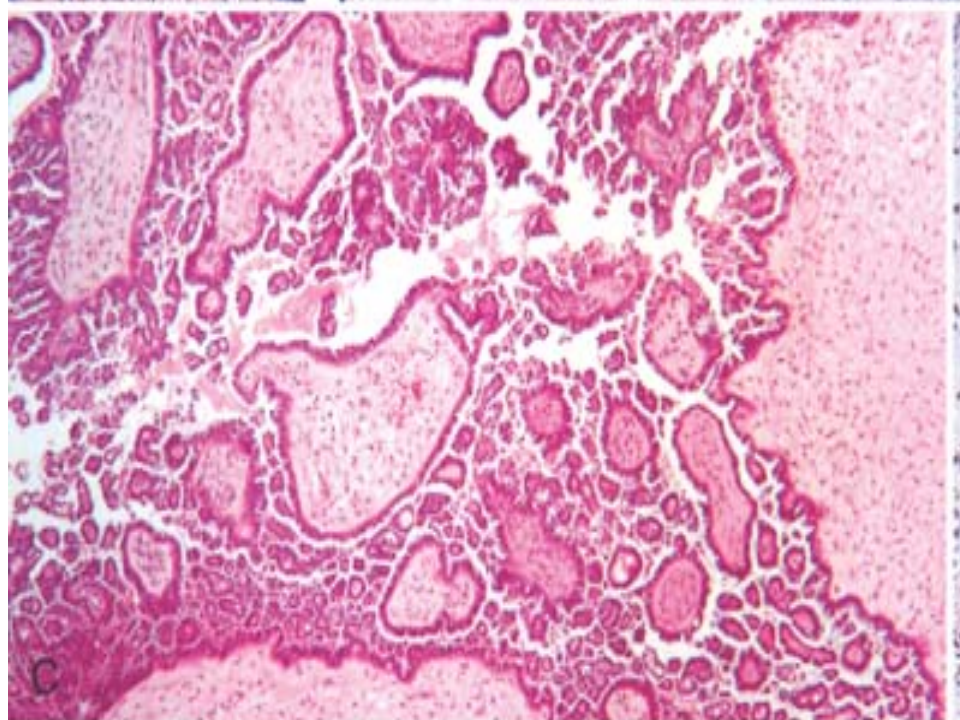
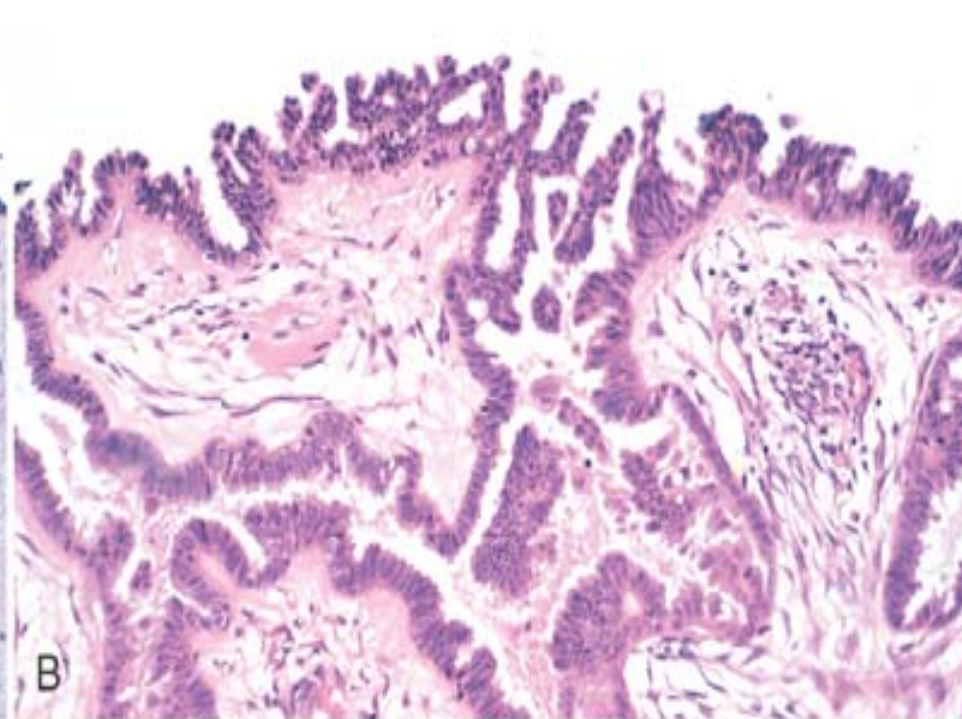
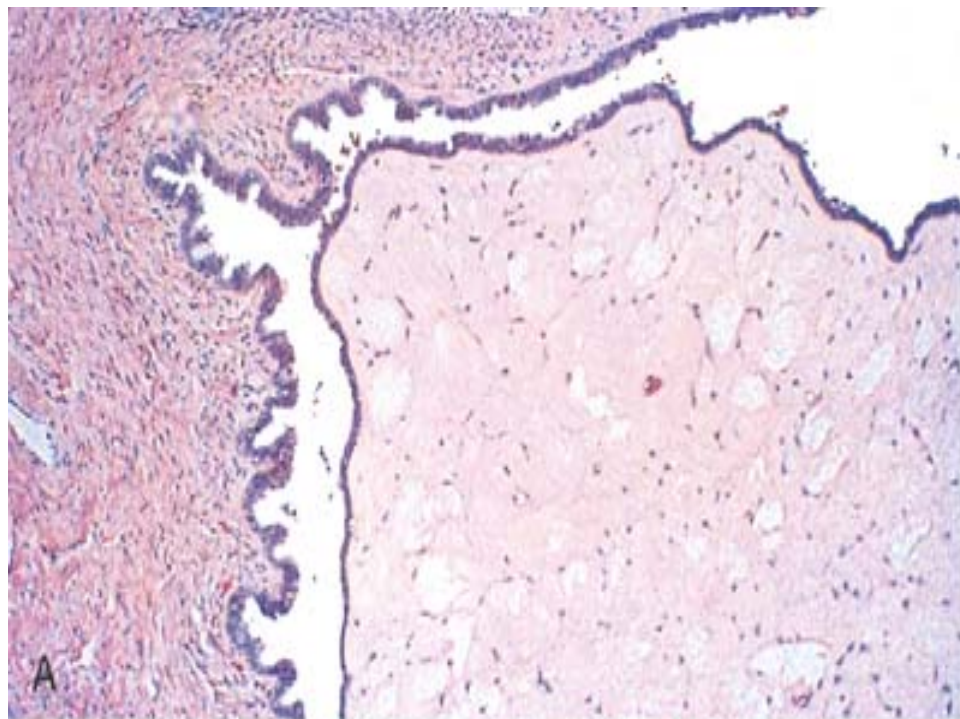
- Mutations in both BRCA1 and BRCA2 increase susceptibility to ovarian cancer.
- The low-grade tumors arising in serous borderline tumors have mutations in the KRAS or BRAF oncogenes, with only rare mutations in p53.
- In contrast, the high-grade tumors have a high frequency of mutations in the p53 gene but lack mutations in either KRAS or BRAF.

Pathology

- Grossly, benign tumors typically present with a smooth glistening cyst wall with no epithelial thickening or with small papillary projections. Borderline tumors contain an increased number of papillary projections .
- On histologic examination, the cysts are lined by columnar epithelium, which has abundant cilia in benign tumors. Microscopic papillae may be found.
- Serous borderline tumors exhibit increased complexity of the stromal papillae, stratification of the epithelium and mild nuclear atypia, but destructive infiltrative growth into the stroma is not seen
- This epithelial proliferation often grows in a delicate, papillary pattern referred to as “micropapillary carcinoma” and is thought to be the precursor to low-grade serous carcinoma

- Larger amounts of solid or papillary tumor mass, irregularity in the tumor mass, and fixation or nodularity of the capsule are important indicators of probable malignancy.
- Microscopically, malignant serous tumors exhibit even more complex growth patterns and infiltration of the underlying stroma.
- Tumor cells display marked nuclear atypia, pleomorphism, atypical mitotic figures and multinucleation.
- Concentric calcifications (psammoma bodies) characterize serous tumors.
- The extent of the spread outside the ovary determines the stage of the disease.



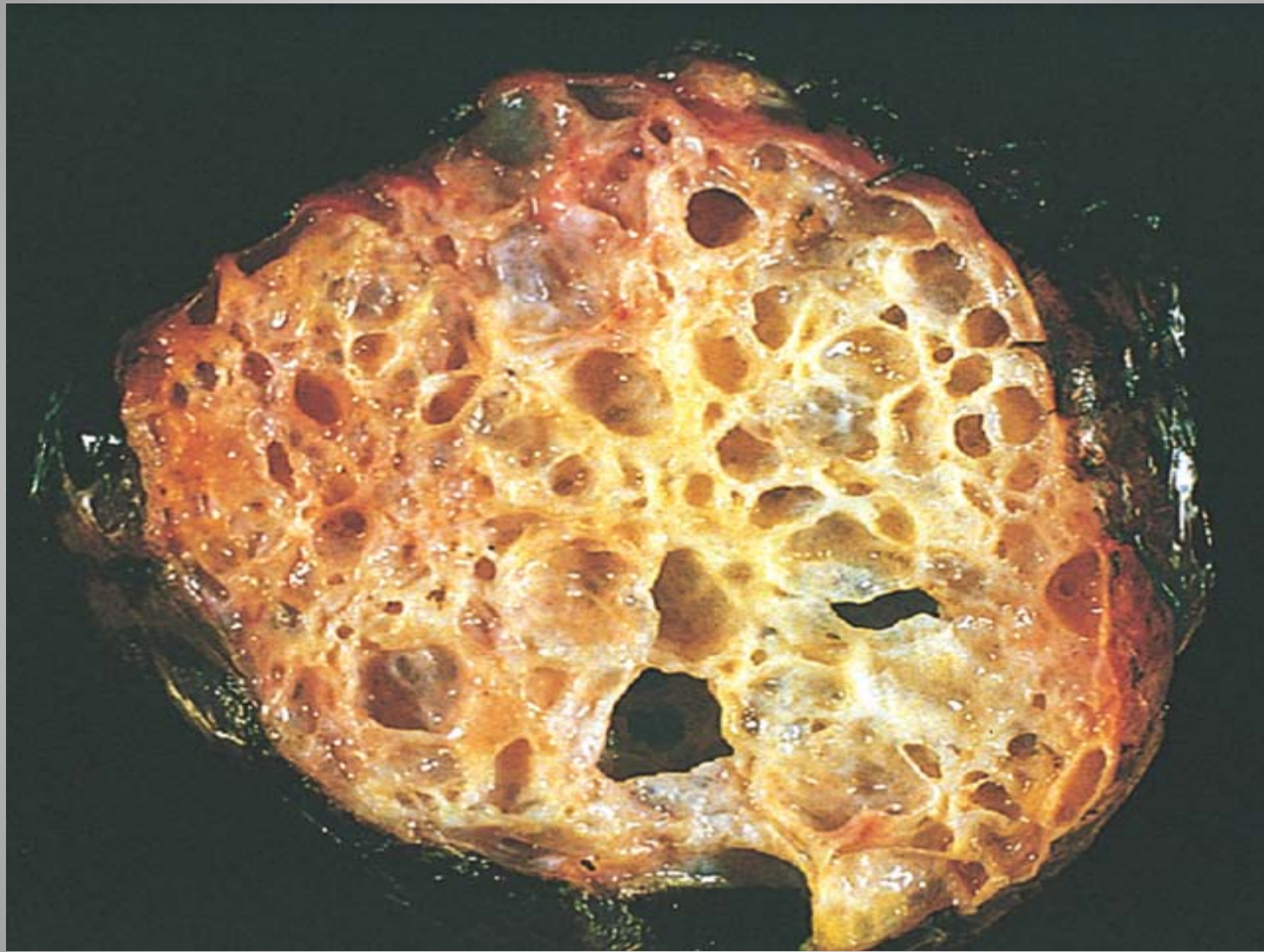


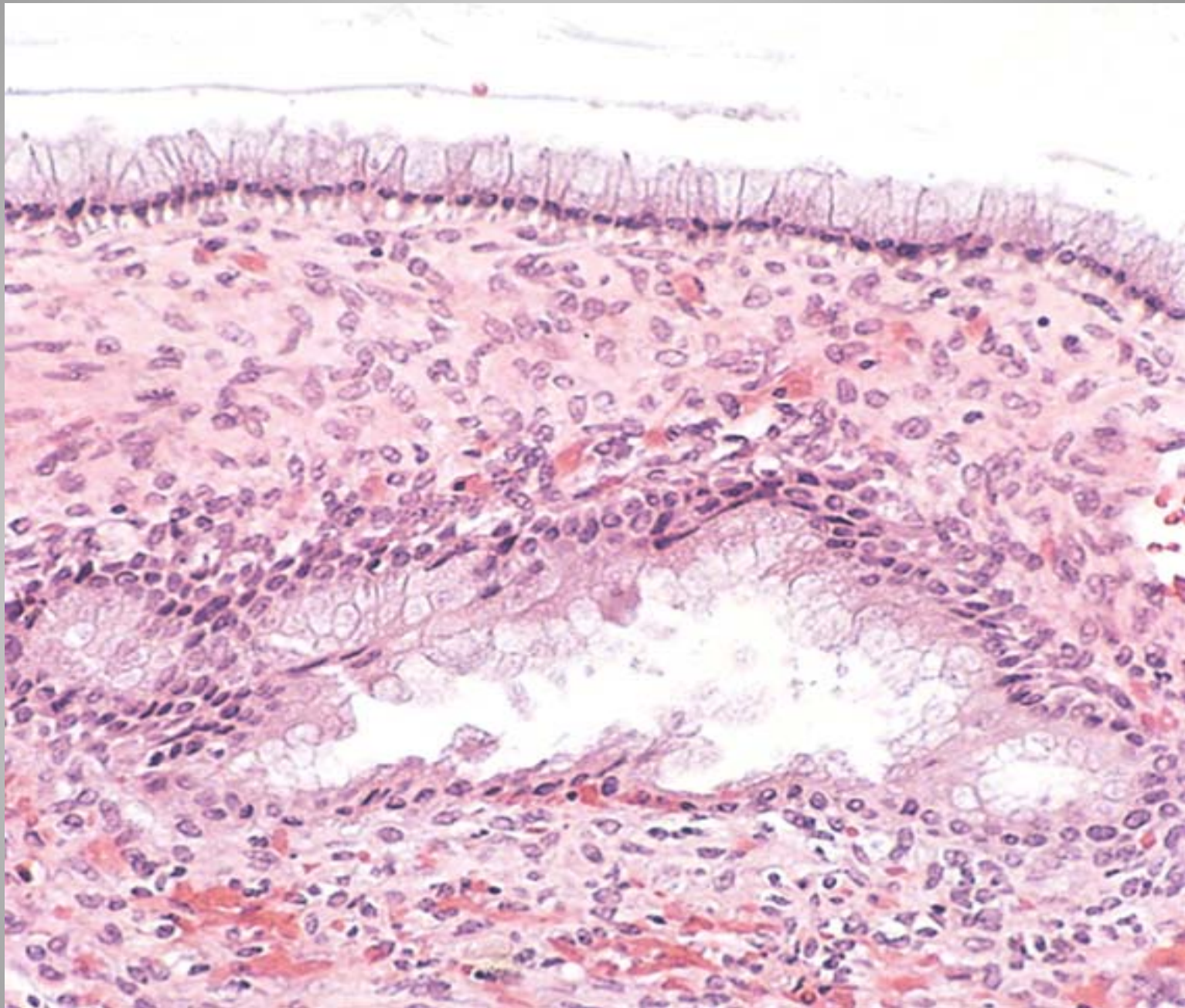
Mucinous Tumors

- They occur principally in middle adult life and are rare before puberty and after menopause.
- Primary ovarian mucinous carcinomas are relatively uncommon and account for fewer than 5% of all ovarian cancers.
- Mutations in KRAS are common in benign mucinous cystadenomas (58%), mucinous borderline tumors (75% to 86%), and in primary ovarian mucinous carcinomas (85%).

Pathology

- Mucinous tumors tend to produce larger cystic masses. They appear grossly as multiloculated tumors filled with sticky, gelatinous fluid rich in glycoproteins.
- On histologic examination, benign mucinous tumors are characterized by a lining of tall, columnar epithelial cells with apical mucin and the absence of cilia, akin to benign cervical or intestinal epithelia.
- Cystadenocarcinomas contain areas of solid growth with invasion into stroma and conspicuous epithelial cell atypia and stratification, loss of gland architecture, and necrosis.





- *Pseudomyxoma peritonei* is defined by extensive mucinous ascites, cystic epithelial implants on the peritoneal surfaces, adhesions, and frequently mucinous tumor involving the ovaries.

Endometrioid Tumors

- Characterized by the presence of tubular glands bearing a close resemblance to benign or malignant endometrium.
- Endometrioid carcinomas may arise in the setting of endometriosis and carcinoma of endometrium.
- Frequent mutations in the PTEN tumor suppressor gene and in the KRAS and β -catenin oncogenes, as well as microsatellite instability.
- Grossly, combination of solid and cystic areas. Bilaterality is usual.
- Microscopically, these are low-grade tumors that reveal glandular patterns.

Clear Cell Adenocarcinoma

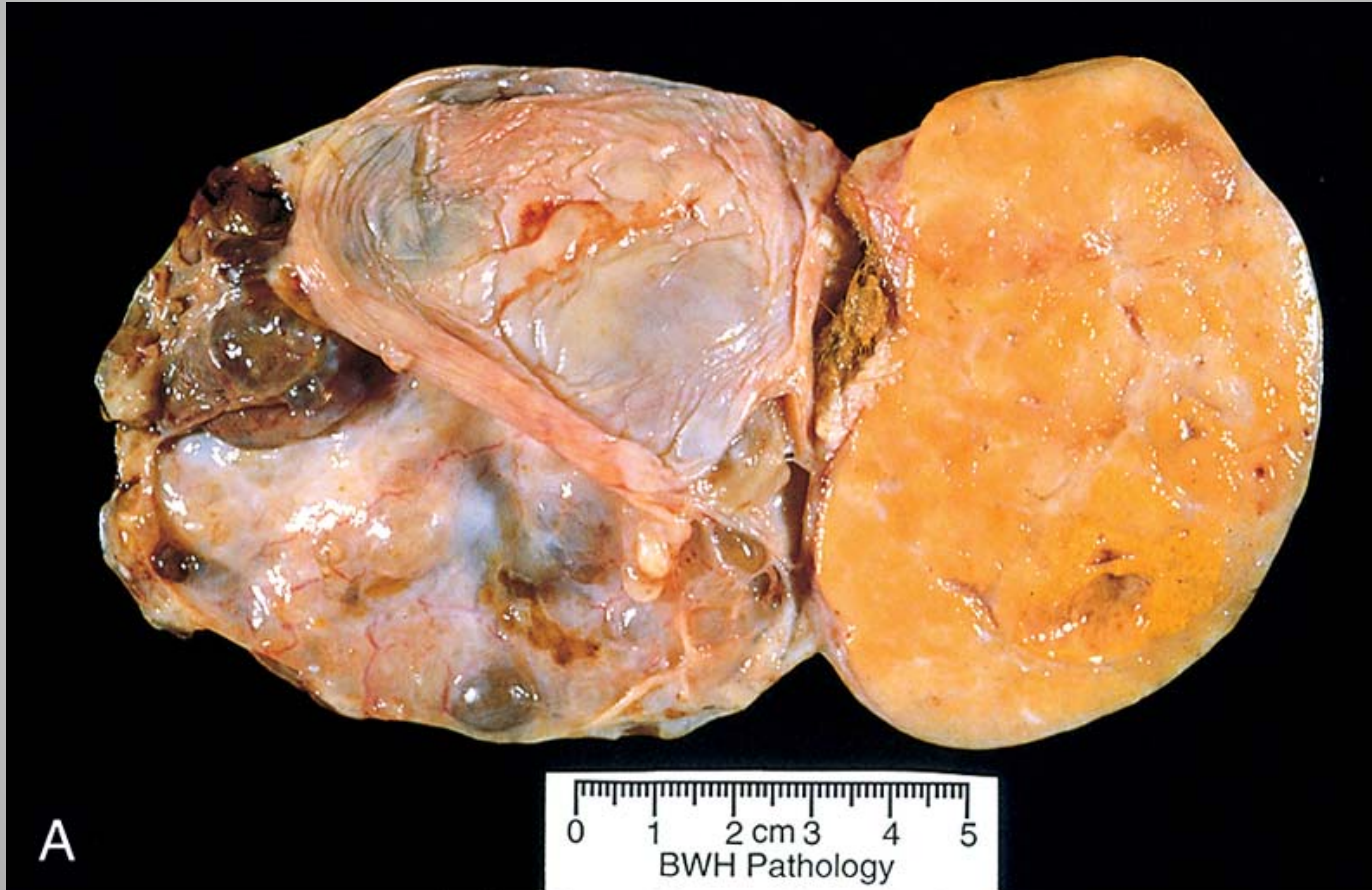
- They are characterized by large epithelial cells with abundant clear cytoplasm similar to hypersecretory gestational endometrium.

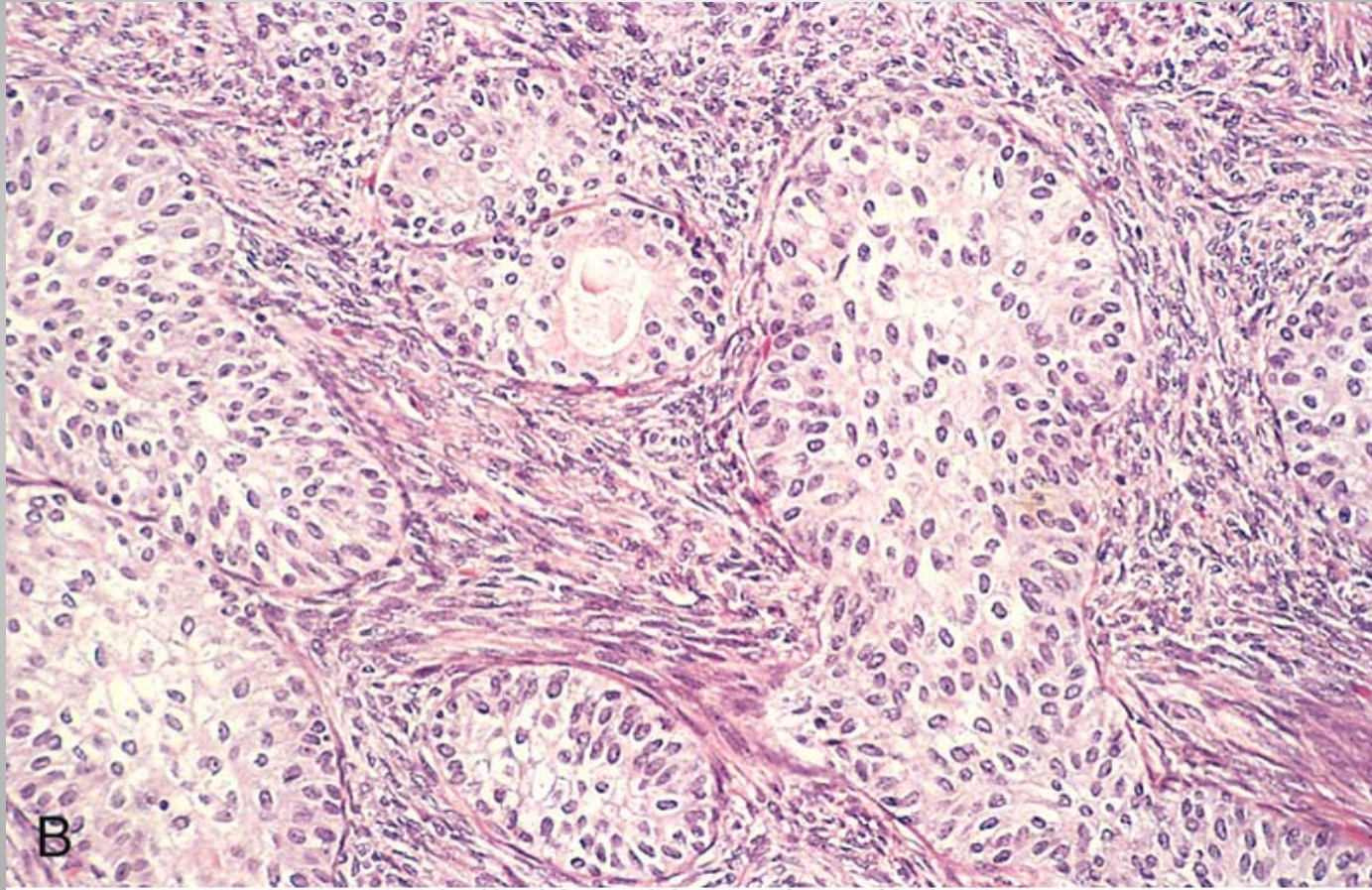
Cystadenofibroma

- Cystadenofibromas are variants in which there is more pronounced proliferation of the fibrous stroma that underlies the columnar lining epithelium.

Brenner tumor

- Brenner tumors are classified as adenofibromas in which the epithelial component consists of nests of transitional-type epithelial cells resembling those lining the urinary bladder.
- These neoplasms may be solid or cystic, are usually unilateral and vary in size from small lesions less than 1 cm in diameter to massive tumors up to 20 and 30 cm.
- The fibrous stroma, resembling that of the normal ovary, is marked by sharply demarcated nests of epithelial cells resembling the epithelium of the urinary tract.
- Most Brenner tumors are benign, but borderline (proliferative Brenner tumor) and malignant counterparts have been reported.





- Early diagnosis and prevention are top priorities.
- Tumor marker **CA-125**, is a high-molecular-weight glycoprotein present in the serum of more than 80% of patients with serous and endometrioid carcinomas. Often used to monitor disease progression after diagnosis.
- Elevations in CA-125 can occur with nonspecific irritation of the peritoneum – endometriosis, inflammation.
- Newly identified biomarkers such as **osteopontin**, which is expressed at significantly higher levels in ovarian cancer patients, may improve early detection.
- Fallopian tubal ligation and oral contraceptive therapy, prophylactic salpingo-oophorectomy are associated with significant reductions in relative risk.

GERM CELL TUMORS

Teratoma

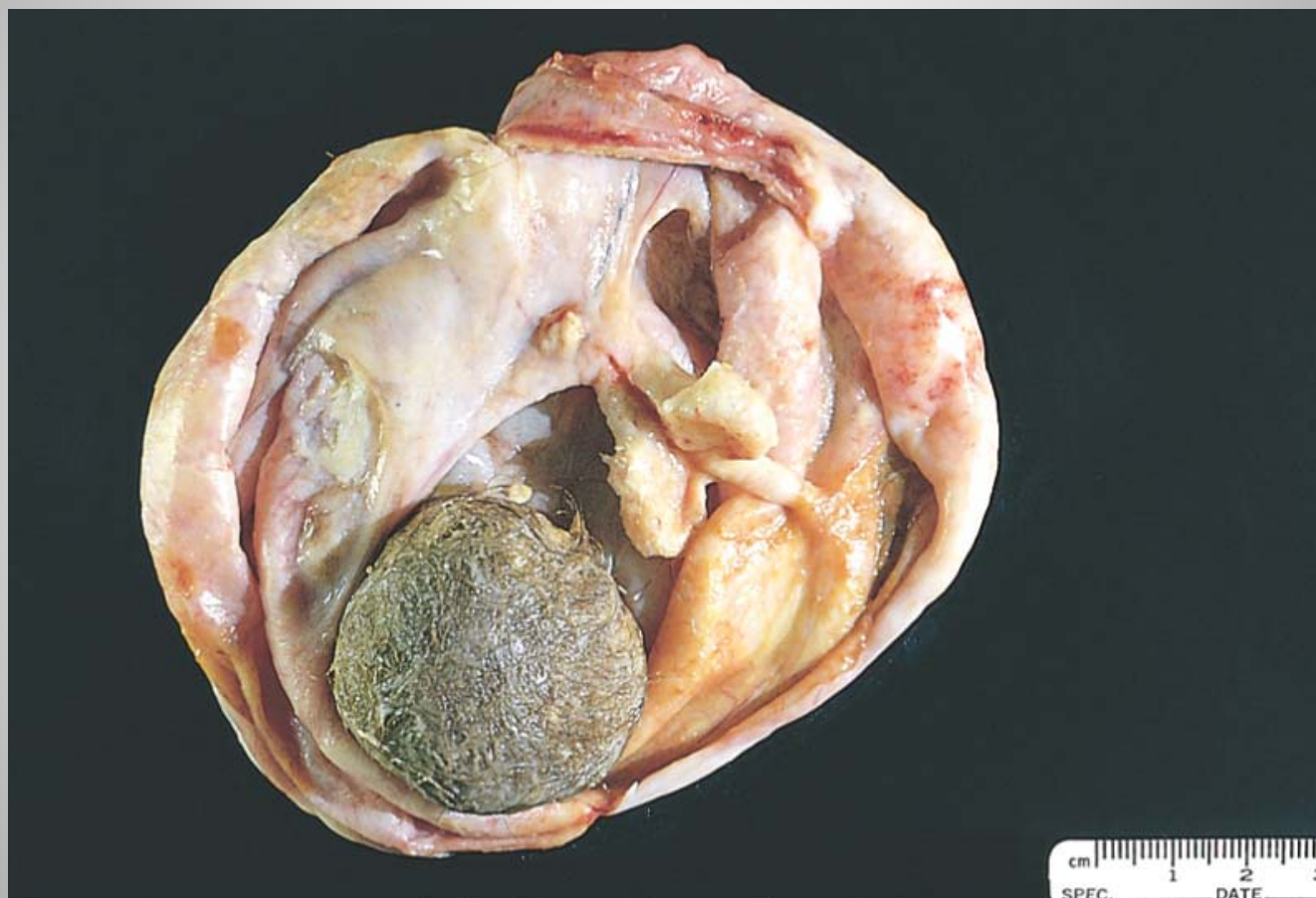
- Divided into three categories:
 - mature (benign),
 - immature (malignant), and
 - monodermal or highly specialized.

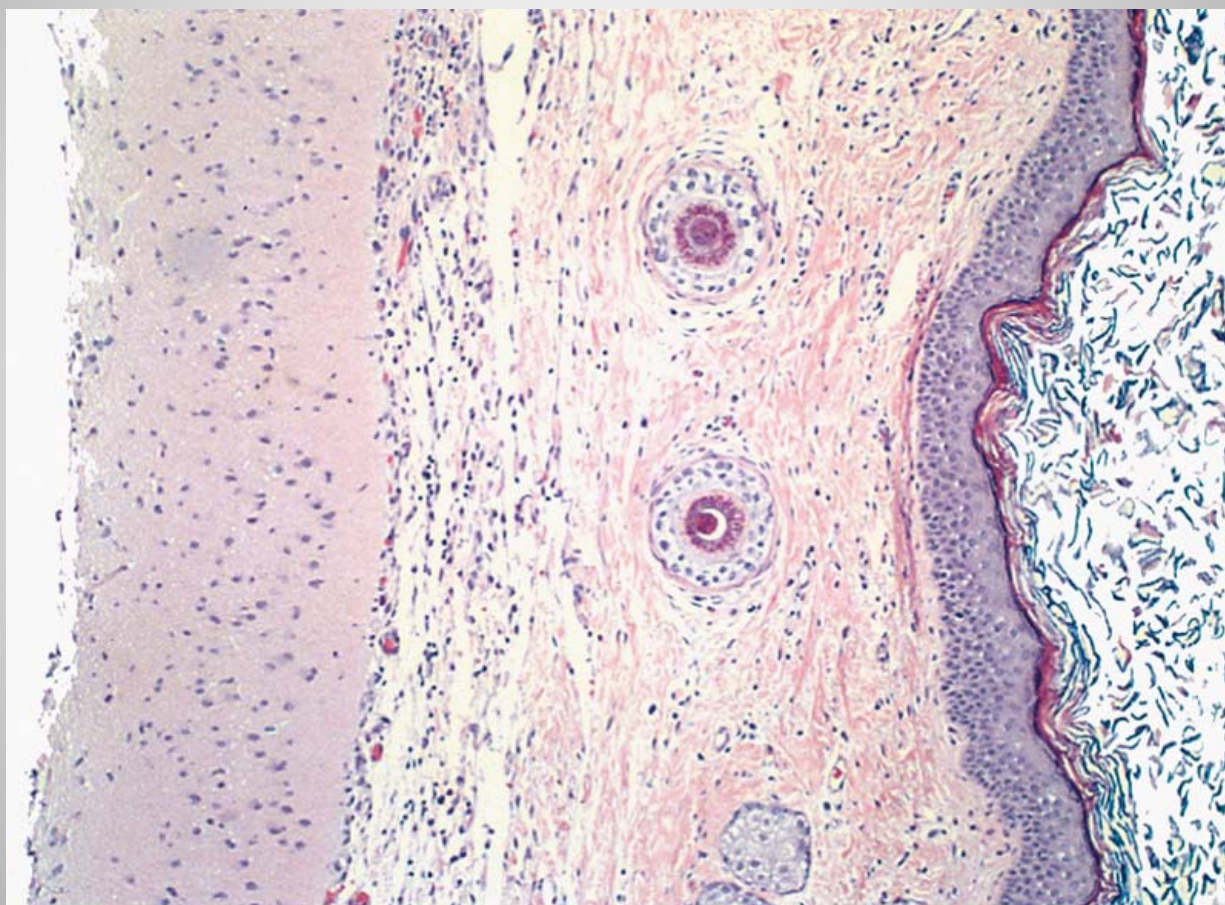
Mature (Benign) Teratomas

- Most benign teratomas are cystic and are better known as dermoid cysts.
- Cystic teratomas are usually found in young women during the active reproductive years.

Pathology

- Grossly, benign teratomas are bilateral in 10% to 15% of cases. Characteristically they are unilocular cysts containing hair and cheesy sebaceous material.
- They reveal a thin wall lined by an opaque, gray-white, wrinkled epidermis. From this epidermis, hair shafts frequently protrude. Within the wall, it is common to find tooth structures and areas of calcification.
- On histologic examination the cyst wall is composed of stratified squamous epithelium with underlying sebaceous glands, hair shafts, and other skin adnexal structures. In most cases structures from other germ layers can be identified, such as cartilage, bone, thyroid tissue and neural tissues.
- About 1% of the dermoids undergo malignant transformation (e.g., thyroid carcinoma, melanoma, but most commonly, squamous cell carcinoma).





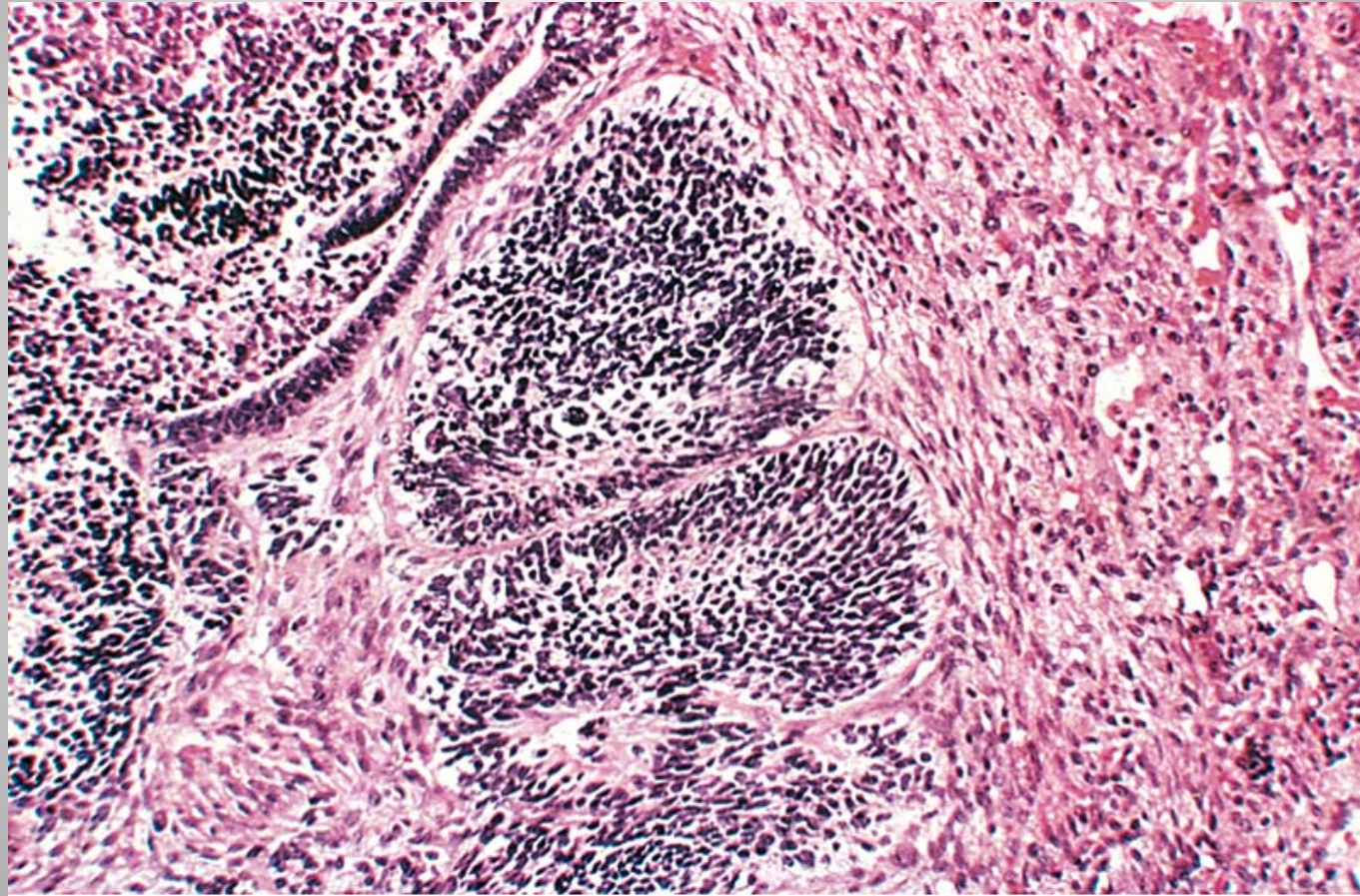
Monodermal or Specialized Teratomas

Struma ovarii and Carcinoid.

- They are always unilateral, although a contralateral teratoma may be present.
- Struma ovarii is composed entirely of mature thyroid tissue. May cause hyperthyroidism.
- The ovarian carcinoid, which presumably arises from intestinal epithelium in a teratoma can produce carcinoid syndrome.
- Rarer is the strumal carcinoid, a combination of struma ovarii and carcinoid in the same ovary.

Immature Malignant Teratomas

- The component tissues resemble embryonal and immature fetal tissue. The tumor is found chiefly in prepubertal adolescents and young women.
- Grossly, the tumors are bulky, solid and have a smooth external surface. There are areas of necrosis and hemorrhage. Hair, sebaceous material, cartilage, bone and calcification may be present.
- Microscopically, there are varying amounts of immature neuroepithelium, cartilage, bone, muscle and others.
- An important risk for subsequent extra-ovarian spread is the histologic grade of tumor (I through III), which is based on the proportion of tissue containing immature neuroepithelium.

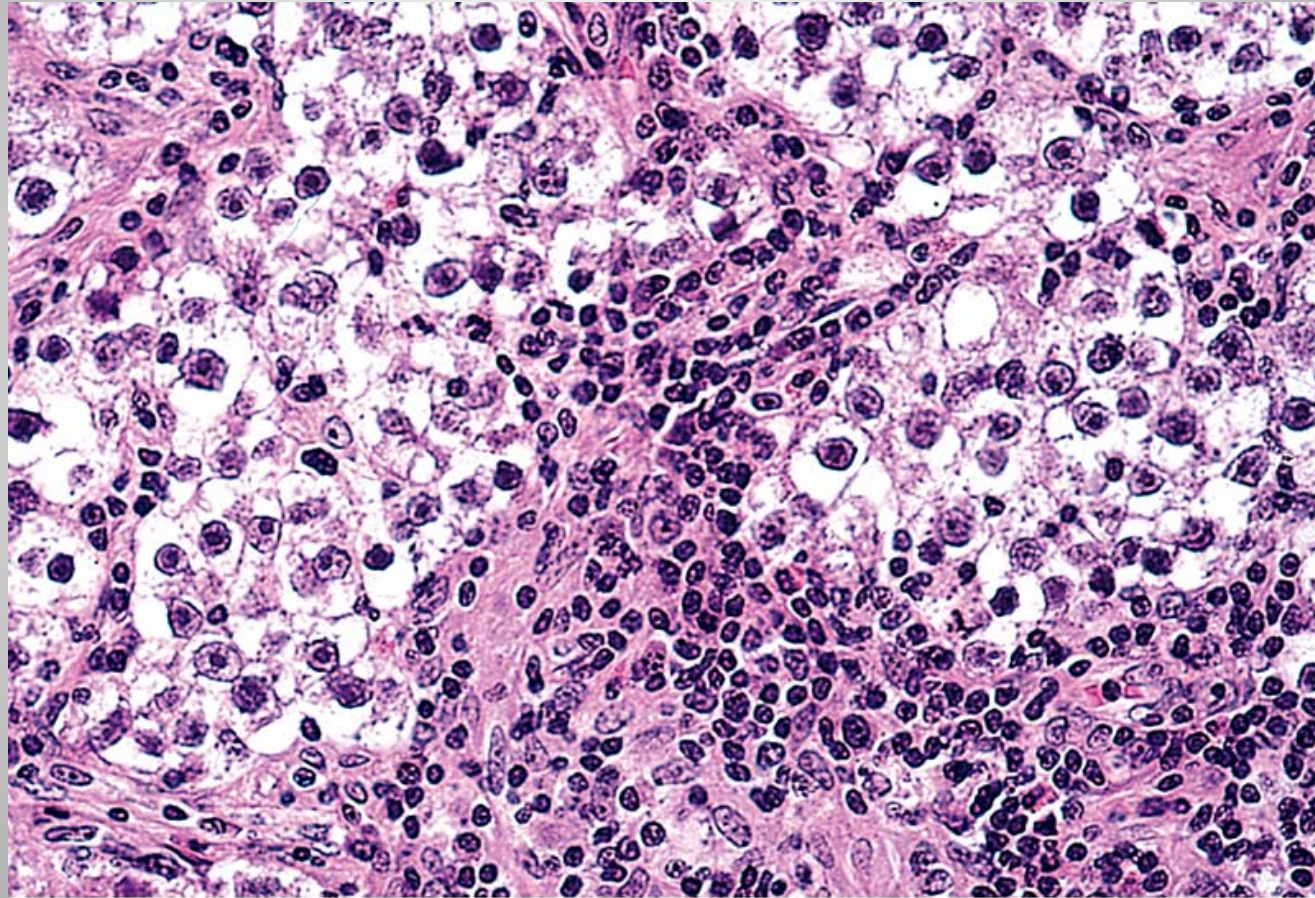


Dysgerminoma

- Ovarian counterpart of the seminoma of the testis. Similar to the seminoma, it is composed of large vesicular cells having a clear cytoplasm, well-defined cell boundaries, and centrally placed regular nuclei.
- They may occur in childhood, but 75% occur in the second and third decades. Like seminomas, dysgerminomas express Oct3, Oct4, and Nanog.
- They also express the receptor tyrosine kinase c-KIT. useful diagnostic marker, may also serve as a therapeutic target.

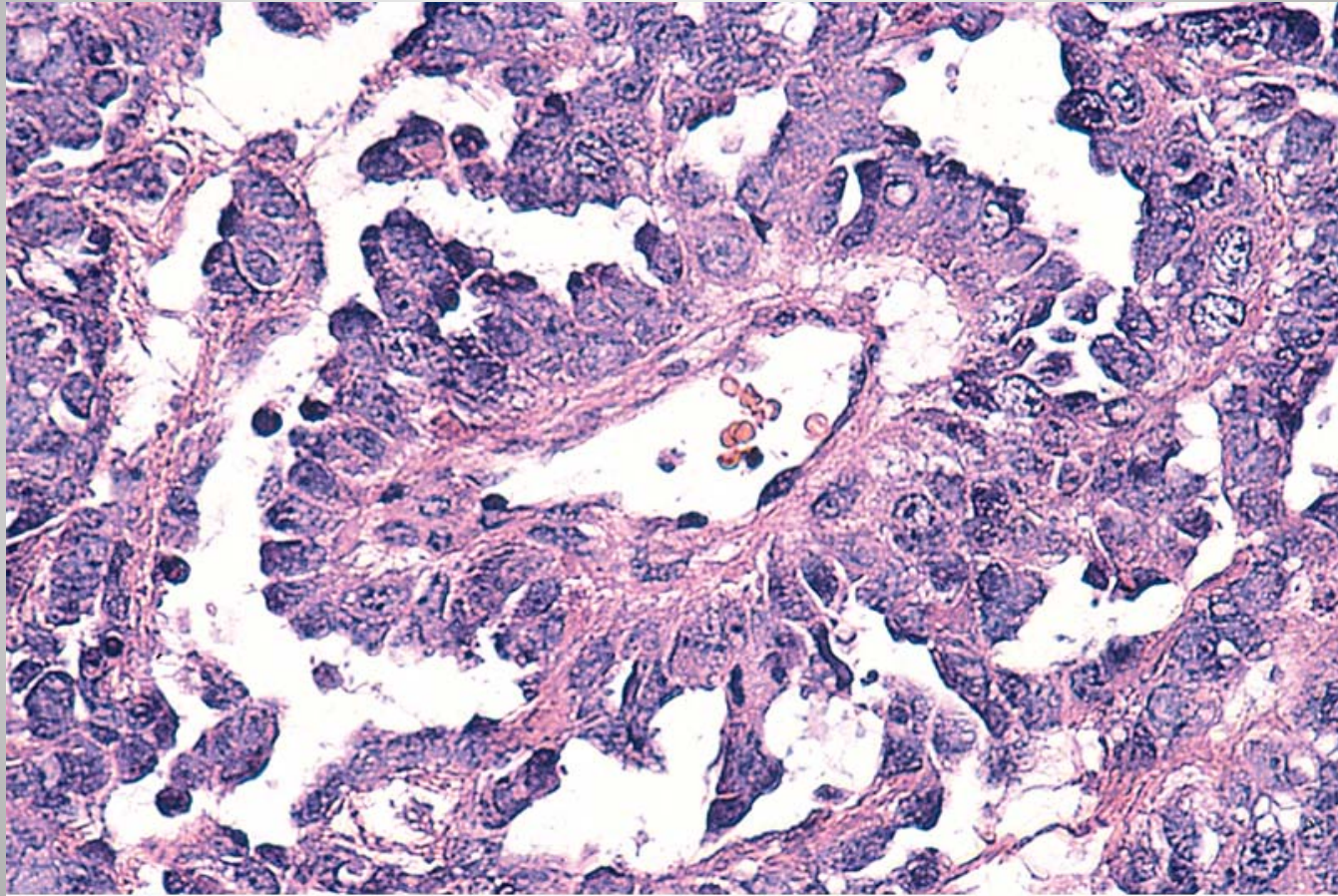
Pathology

- Usually unilateral (80% to 90%), most are solid tumors ranging in size from barely visible nodules to masses that virtually fill the entire abdomen.
- On cut surface they have a yellow-white to gray-pink appearance and are often soft and fleshy.
- On histologic examination the dysgerminoma cells are dispersed in sheets or cords separated by scant fibrous stroma.
- Fibrous stroma is infiltrated with mature lymphocytes and occasional granulomas.



Endodermal Sinus (Yolk Sac) Tumor

- Second most common malignant tumor of germ cell origin.
- Derived from differentiation of malignant germ cells along the extra-embryonic yolk sac lineage.
- Tumor is rich in α -fetoprotein and α 1-antitrypsin.
- Characteristic histologic feature is a glomerulus-like structure composed of a central blood vessel enveloped by germ cells within a space lined by germ cells (Schiller-Duval body).
- Conspicuous intracellular and extracellular hyaline droplets are present in all tumors, and some of these stain for α -fetoprotein.
- Most patients are children or young women presenting with abdominal pain and a rapidly developing pelvic mass.



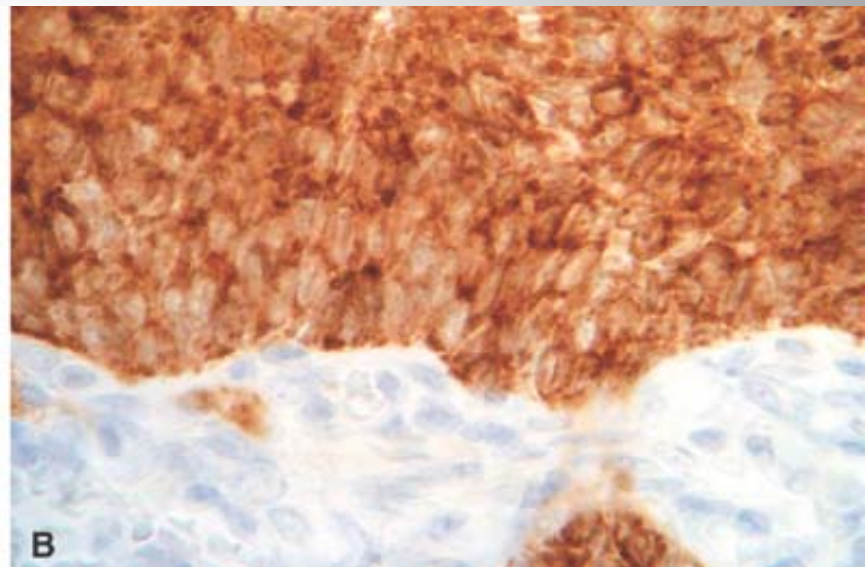
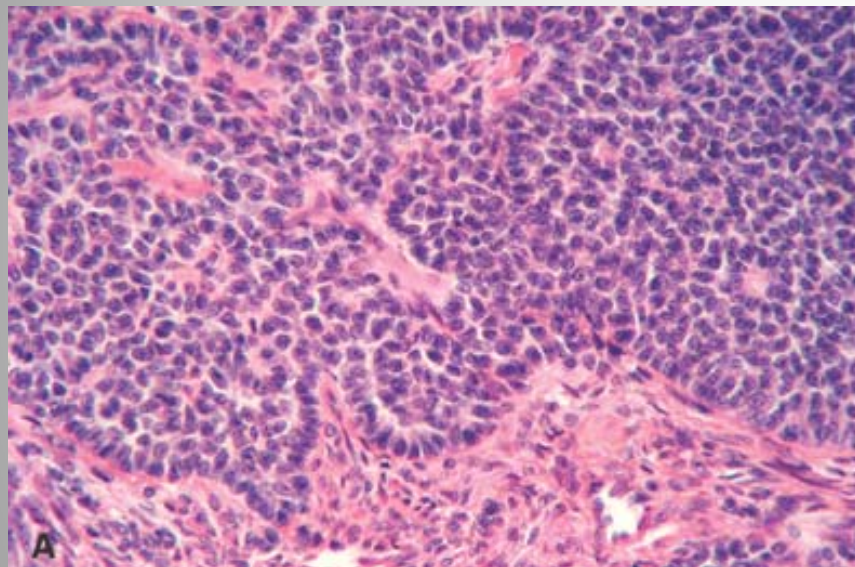
Choriocarcinoma

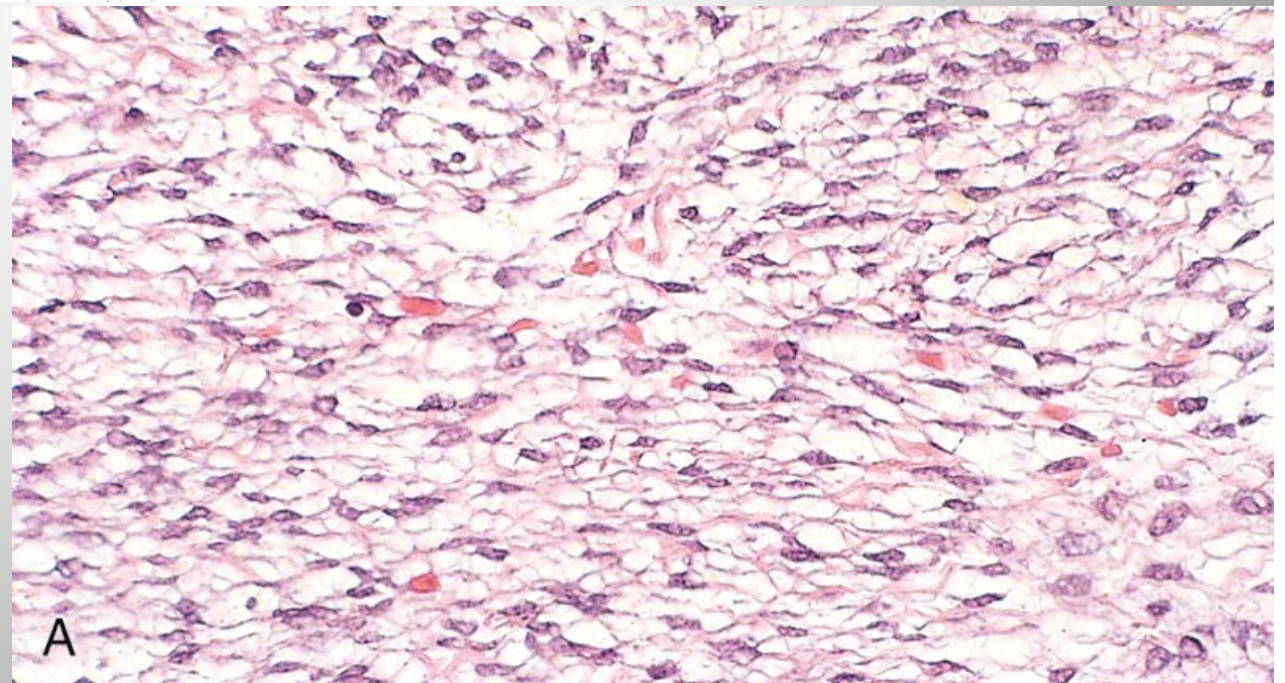
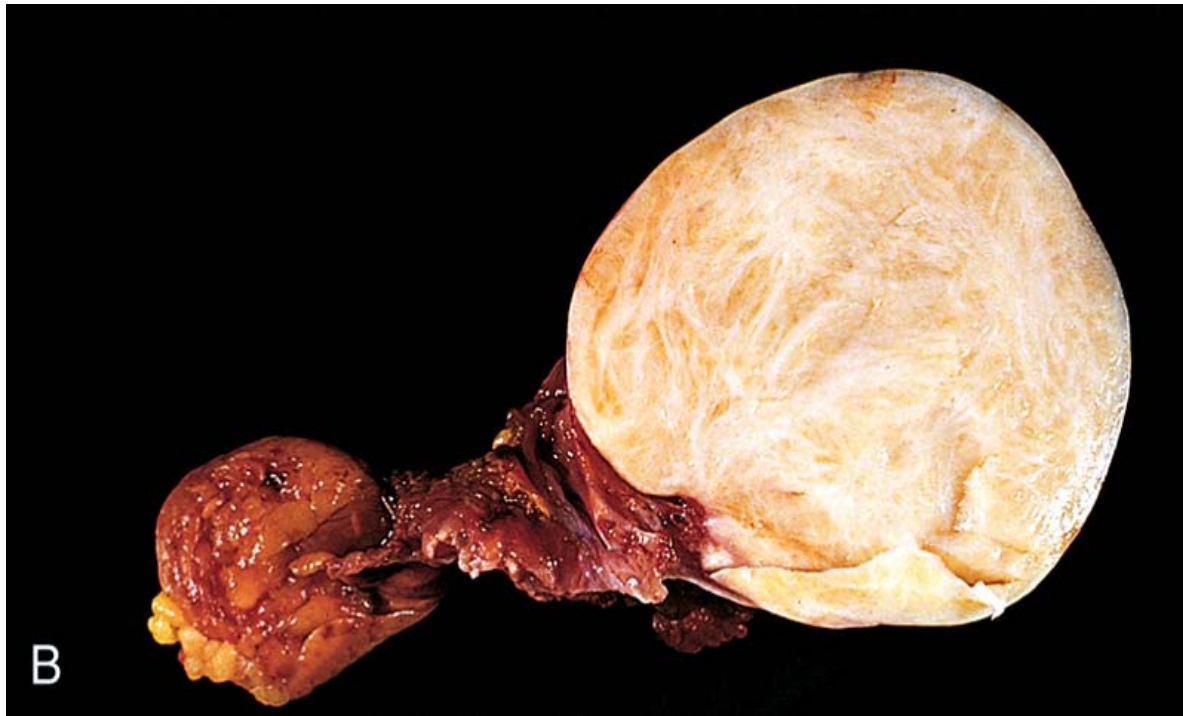
- Most ovarian choriocarcinomas exist in combination with other germ cell tumors. They are histologically identical to the more common placental lesions.
- The ovarian primaries are aggressive tumors that generally have metastasized widely through the bloodstream to the lungs, liver, bone, and other viscera by the time of diagnosis.
- Like all choriocarcinomas they elaborate high levels of chorionic gonadotropins, which is sometimes helpful in establishing the diagnosis or detecting recurrences.
- In contrast to choriocarcinomas arising in placental tissue, those arising in the ovary are generally unresponsive to chemotherapy and are often fatal.

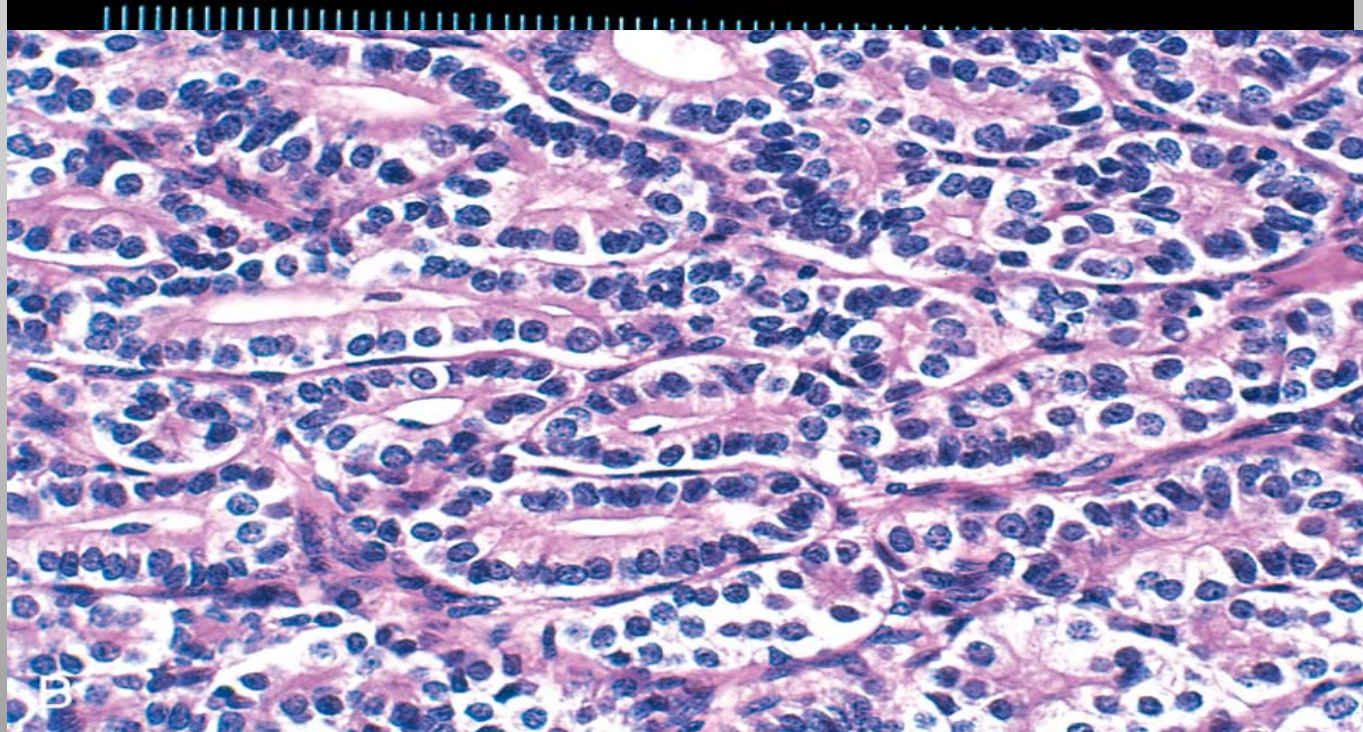
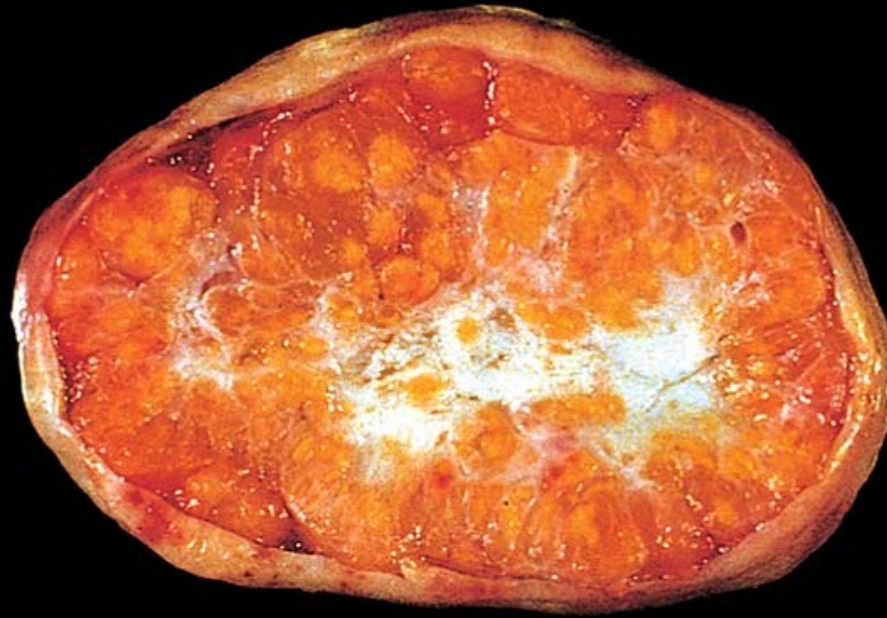SEX CORD-STROMAL TUMORS

SEX CORD–STROMAL TUMORS

- These ovarian neoplasms are derived from the ovarian stroma, which in turn is derived from the sex cords of the embryonic gonad.
- Because the undifferentiated gonadal mesenchyme eventually produces structures of specific cell type in both male (Sertoli and Leydig) and female (granulosa and theca) gonads, tumors resembling all of these cell types can be identified in the ovary.
- Moreover, because some of these cells normally secrete estrogens (granulosa and theca cells) or androgens (Leydig cells), their corresponding tumors may be either feminizing (granulosa–theca cell tumors) or masculinizing (Leydig cell tumors).







METASTATIC TUMORS

- The most common metastatic tumors of the ovary are derived from tumors of müllerian origin: the uterus, fallopian tube, contralateral ovary, or pelvic peritoneum.
- The most common extra-müllerian tumors metastatic to the ovary are carcinomas of the breast and gastrointestinal tract, including colon, stomach, biliary tract, and pancreas.
- A classic example of metastatic gastrointestinal neoplasia to the ovaries is termed Krukenberg tumor, characterized by bilateral metastases composed of mucin-producing, signet-ring cancer cells, most often of gastric origin.

THANK YOU