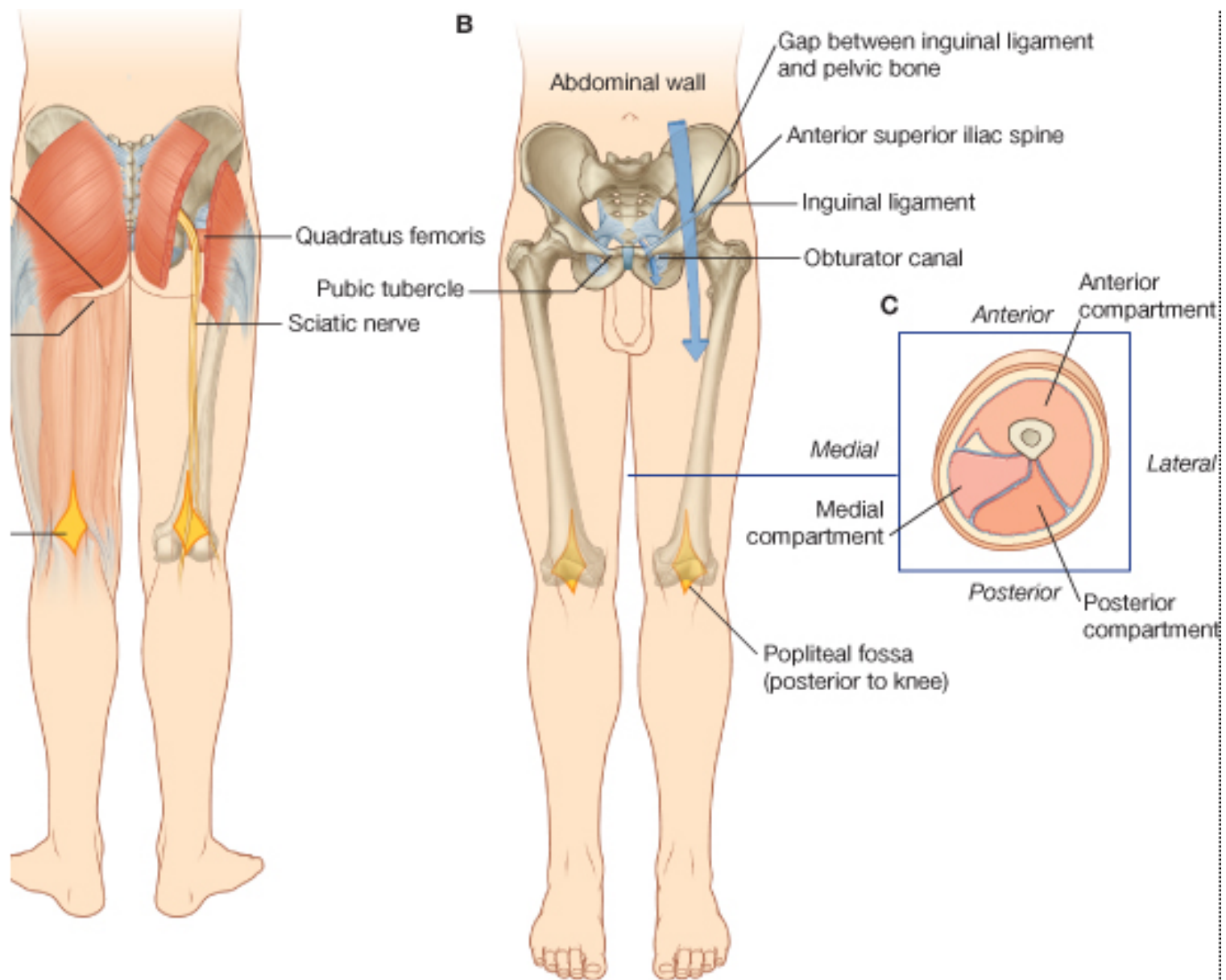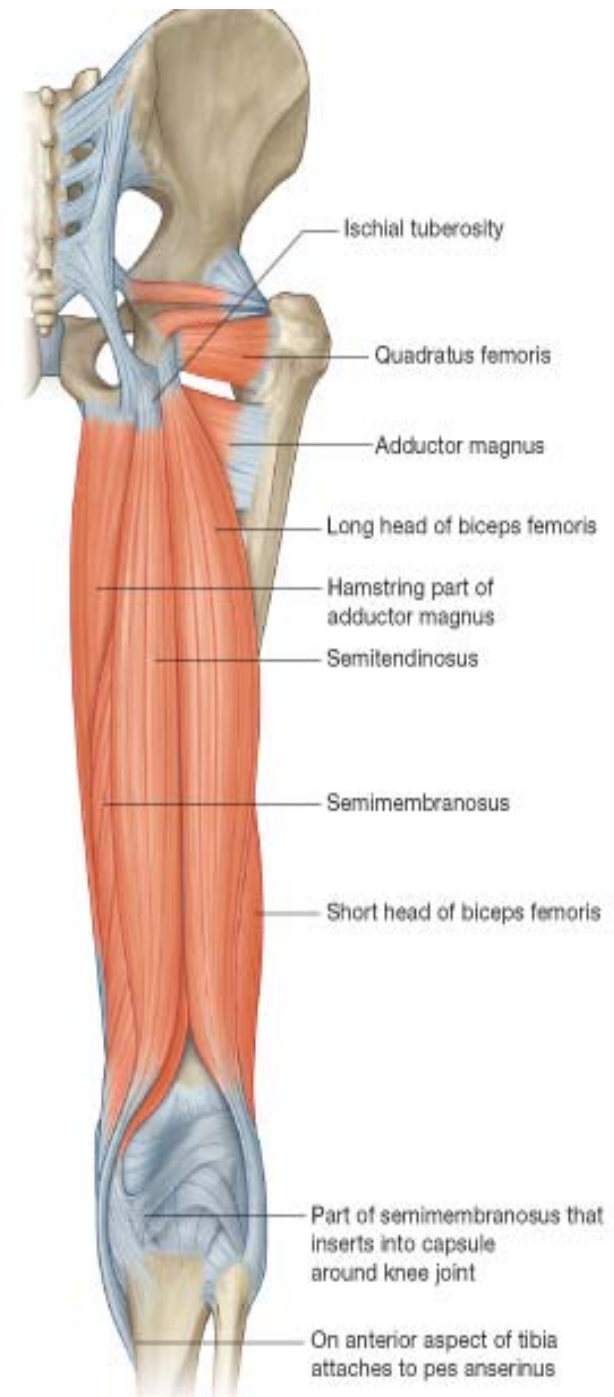
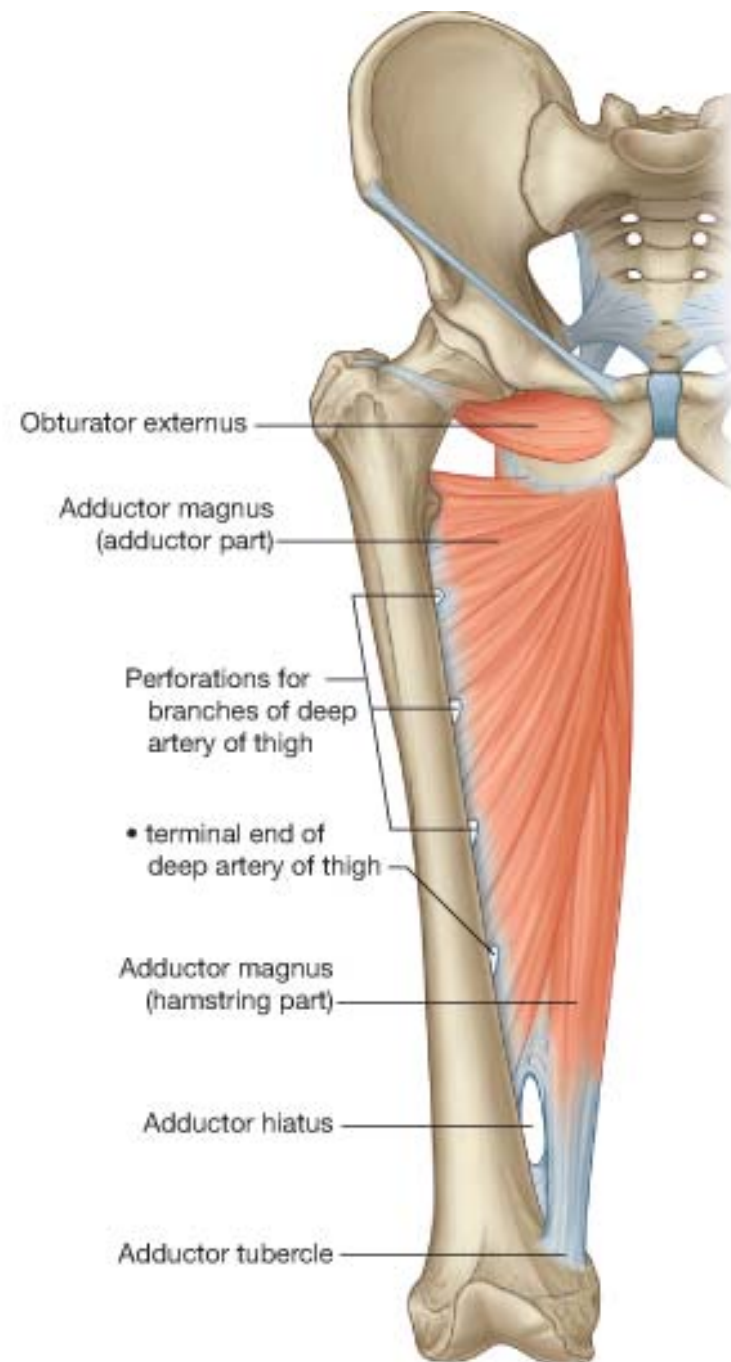
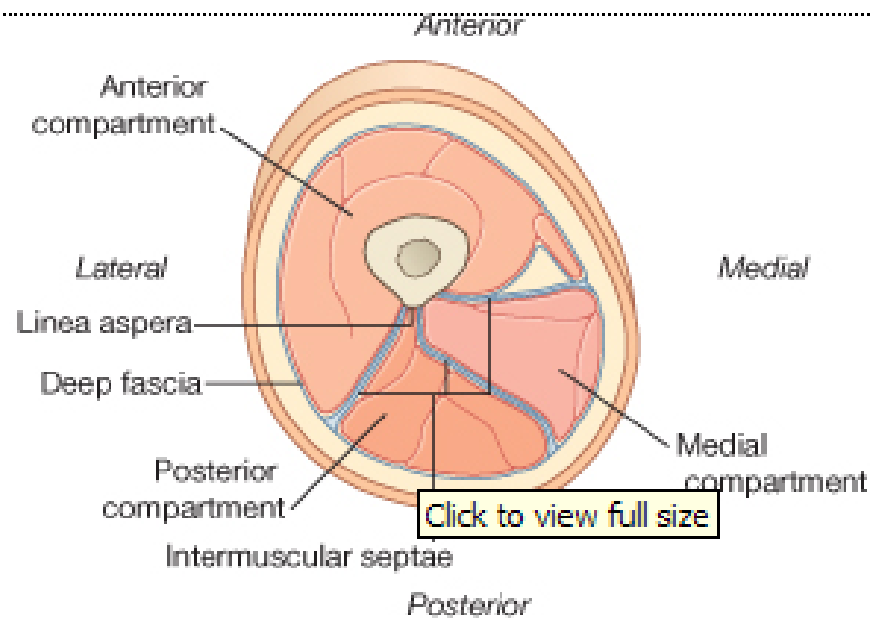


Hamstring muscles

The word *ham* originally referred to the fat and muscle behind the [knee](#). *String* refers to tendons, and thus, the hamstrings are the string-like tendons felt on either side of the back of the knee.





THE ADDUCTOR MAGNUS

Adductor magnus

Adductor part: inferior ramus of pubis, ramus of ischium

Hamstrings part: ischial tuberosity

Adductor part: gluteal tuberosity, linea aspera, medial supracondylar line

Hamstrings part: adductor tubercle of femur

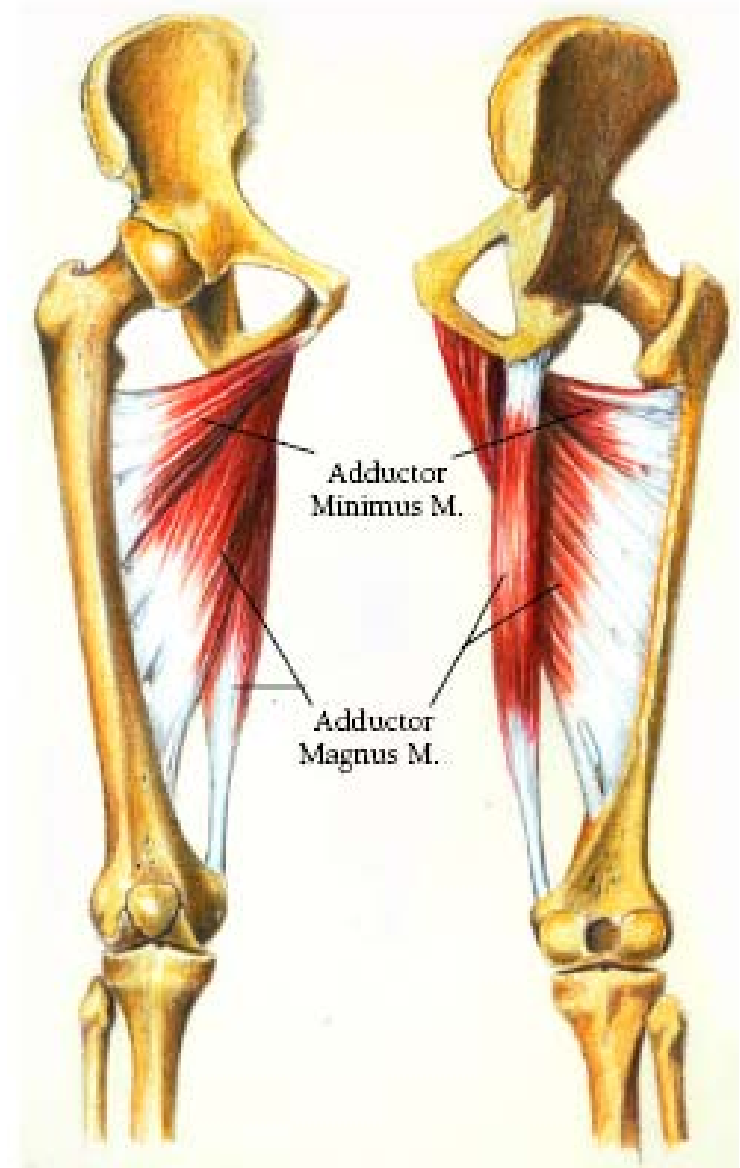
Adductor part: obturator nerve (L2, L3, L4), branches of posterior division

Hamstrings part: tibial part of sciatic nerve (L4)

Adducts thigh

Adductor part: flexes thigh

Hamstrings part: extends thigh



ANTERIOR VIEW

POSTERIOR VIEW

THE BICEPS FEMORIS MUSCLE

Long head: ischial tuberosity

Short head: linea aspera and lateral supracondylar line of femur

Lateral side of head of fibula; tendon is split at this site by fibular collateral ligament of knee

Long head: tibial division of sciatic nerve (L5, S1, S2)

Short head: common peroneal division of sciatic nerve (L5, S1, S2)

Flexes leg and rotates it laterally when knee is flexed; extends thigh (e.g., when starting to walk)



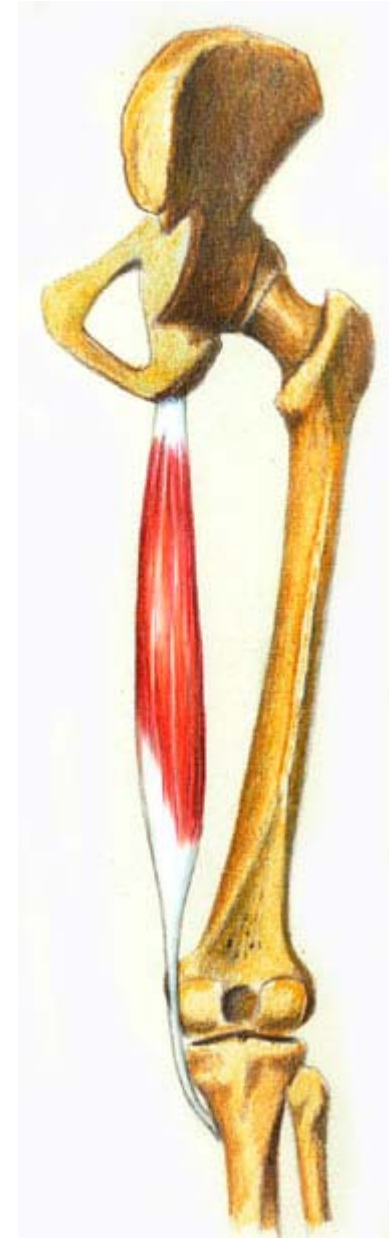THE SEMITENDINOSUS MUSCLE

Ischial tuberosity

Medial surface of superior part of tibia

Tibial division of sciatic nerve (L5, S1, S2)

Extend thigh; flex leg and rotate it medially when knee is flexed; when thigh and leg are flexed, these muscles can extend trunk



THE SEMIMEMBRANOSUS MUSCLE

Ischial tuberosity

**Posterior part of medial condyle of tibia;
reflected attachment forms oblique popliteal
ligament (to lateral femoral condyle)**

**Tibial division of sciatic nerve part of tibia (L5,
S1, S2)**

**Extend thigh; flex leg and rotate it medially
when knee is flexed; when thigh and leg are
flexed, these muscles can extend trunk**



Muscle	Attachment	Distal Attachment	Innervation	Main Action
Adductor magnus	Adductor part: inferior ramus of pubis, ramus of ischium Hamstrings part: ischial tuberosity	Adductor part: gluteal tuberosity, linea aspera, medial supracondylar line Hamstrings part: adductor tubercle of femur	Adductor part: obturator nerve (L2, L3, L4), branches of posterior division Hamstrings part: tibial part of sciatic nerve (L4) Adducts thigh	Adductor part: flexes thigh Hamstrings part: extends thigh
Semi tendinosus	Ischial tuberosity	Medial surface of superior part of tibia	Tibial division of sciatic nerve part of tibia (L5, S1, S2)	Extend thigh; flex leg and rotate it medially when knee is flexed;
Semi membranous	Ischial tuberosity	Posterior part of medial condyle of tibia; reflected attachment forms oblique popliteal ligament (to lateral femoral condyle)		when thigh and leg are flexed, these muscles can extend trunk
Biceps femoris	Long head: ischial tuberosity Short head: linea aspera and lateral supracondylar line of femur	Lateral side of head of fibula; tendon is split at this site by fibular collateral ligament of knee	Long head: tibial division of sciatic nerve (L5, S1, S2) Short head: common fibular division of sciatic nerve (L5, S1, S2)	Flexes leg and rotates it laterally when knee is flexed; extends thigh (e.g., when starting to walk)

Injuries

[Straining](#) of the hamstring, also known as a [pulled hamstring](#), is defined as an excessive stretch or tear of muscle fibers and related tissues. Usually happen in athletes. Very painful. Often result from inadequate warming up.

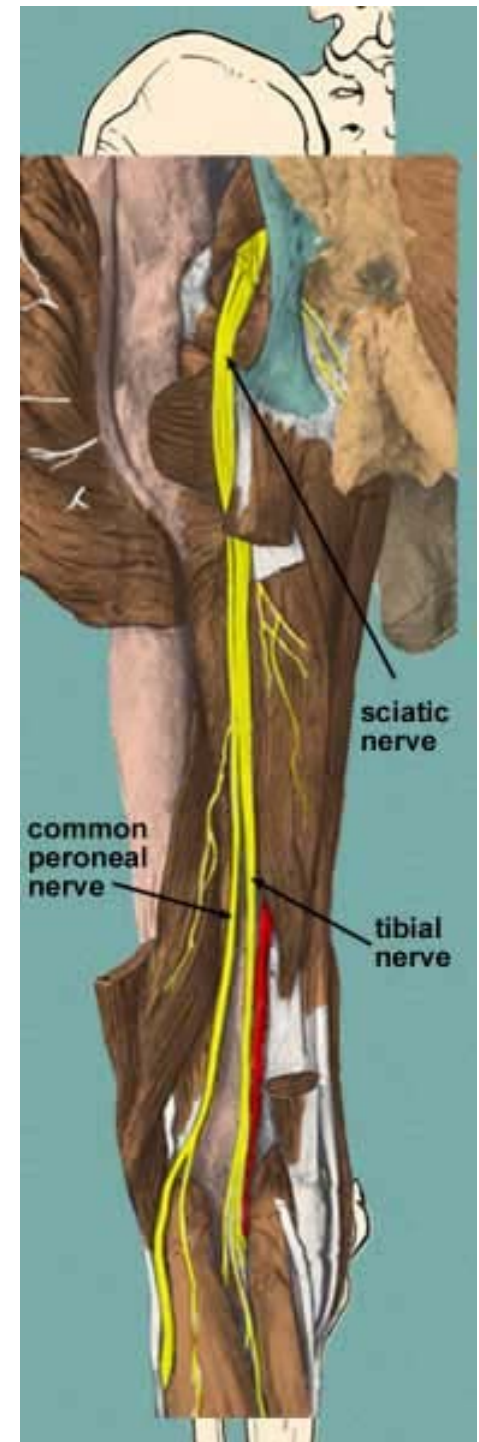
Use in surgery

The distal semitendinosus tendon is one of the tendons that can be used in the [surgical procedure ACL reconstruction](#). In this procedure, a piece of it is used to replace the [anterior cruciate ligament](#) (ACL). The ACL is one of the four major ligaments in the knee.

Sciatic nerve

The **sciatic nerve** (also known as the **ischiatric nerve**) is a large nerve that starts in the lower back and runs through the buttock and down the lower limb. It is the longest and largest single nerve in the body.

The sciatic supplies nearly the whole of the skin of the leg, the muscles of the back of the thigh, and those of the leg and foot.



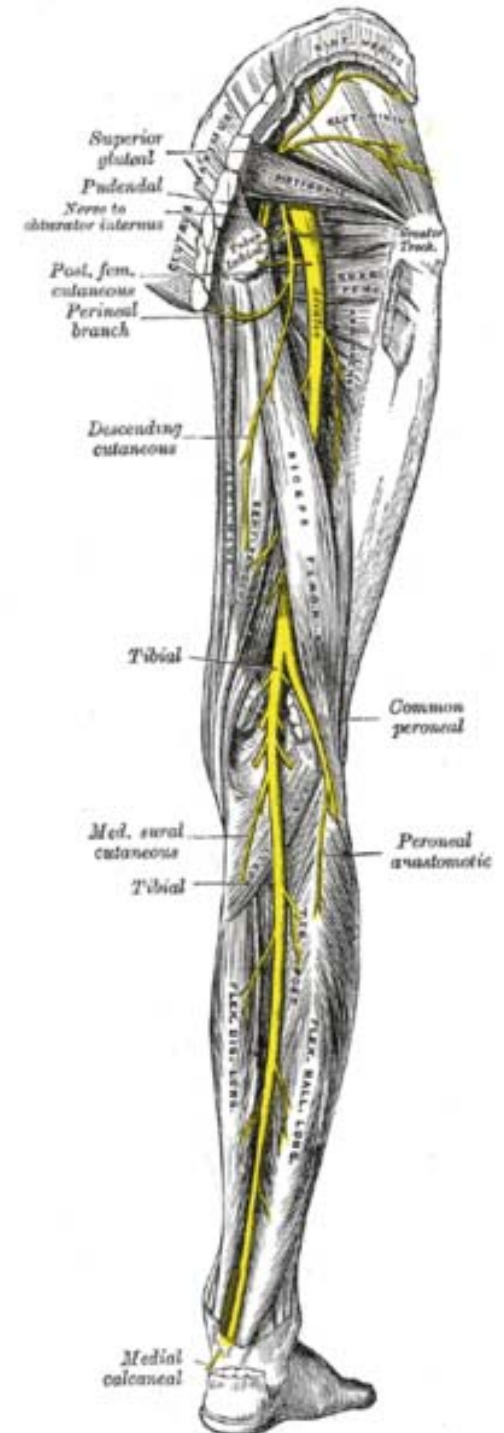
Anatomical course

The nerve enters the lower limb by exiting the [pelvis](#) through the [greater sciatic foramen](#), below the [Piriformis](#) muscle.

It descends midway in the [greater trochanter](#) of the [femur](#) and the [tuberosity of the ischium](#), and along the back of the thigh to about its lower third, where it divides into two large branches, the [tibial](#) and [common peroneal nerves](#).

In the upper part of its course, the nerve rests upon the posterior surface of the ischium, the [nerve to the Quadratus femoris](#), the [Obturator internus](#) and [Gemelli](#); it is accompanied by the [posterior femoral cutaneous nerve](#) and the [inferior gluteal artery](#), and is covered by the [Gluteus maximus](#).

Lower down, it lies upon the [Adductor magnus](#), and is crossed obliquely by the long head of the [Biceps femoris](#).



Branches

The nerve gives off articular and muscular branches.

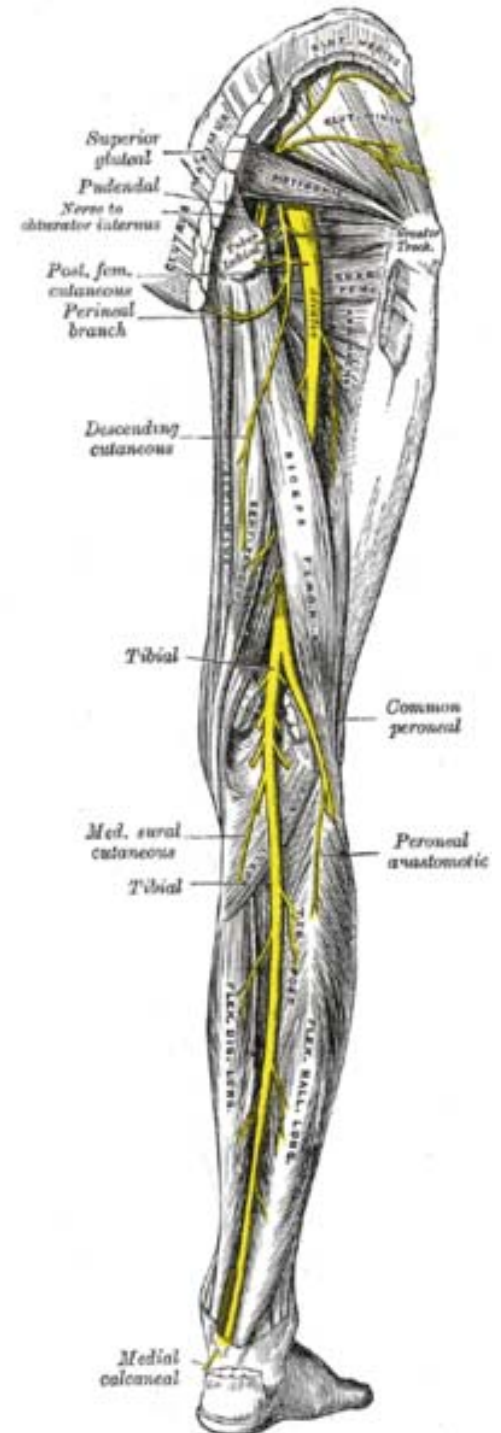
The **articular branches** (*rami articulares*) arise from the upper part of the nerve and supply the [hip-joint](#), perforating the posterior part of its capsule; they are sometimes derived from the [sacral plexus](#).

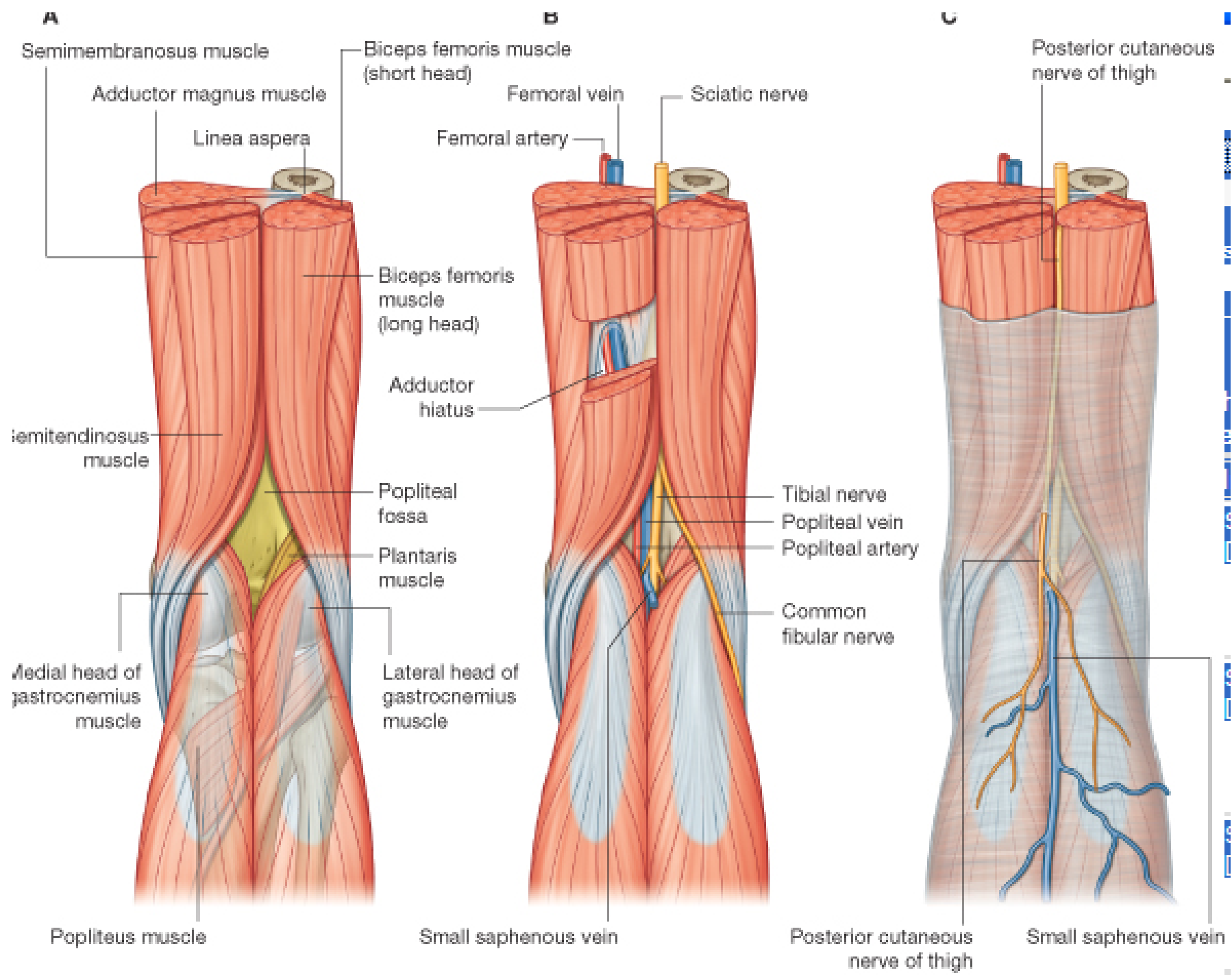
The **muscular branches** (*rami musculares*) are distributed to the following muscles of the lower limb: [Biceps femoris](#), [Semitendinosus](#), [Semimembranosus](#), and [Adductor magnus](#). The nerve to the short head of the Biceps femoris comes from the common peroneal part of the sciatic, while the other muscular branches arise from the tibial portion, as may be seen in those cases where there is a high division of the sciatic nerve.

The muscular branch eventually gives off the [tibial nerve](#) and [common peroneal nerve](#), which innervates the muscles of the (lower) leg. The tibial nerve goes on to innervate all muscles of the foot except the extensor digitorum brevis (peroneal nerve).

Pathology

Pain caused by a compression or irritation of the sciatic nerve by a problem in the lower back is called [sciatica](#). Common causes of sciatica include the following low back conditions: [spinal disc herniation](#), [degenerative disc disease](#), [spinal stenosis](#), and [spondylolisthesis](#).

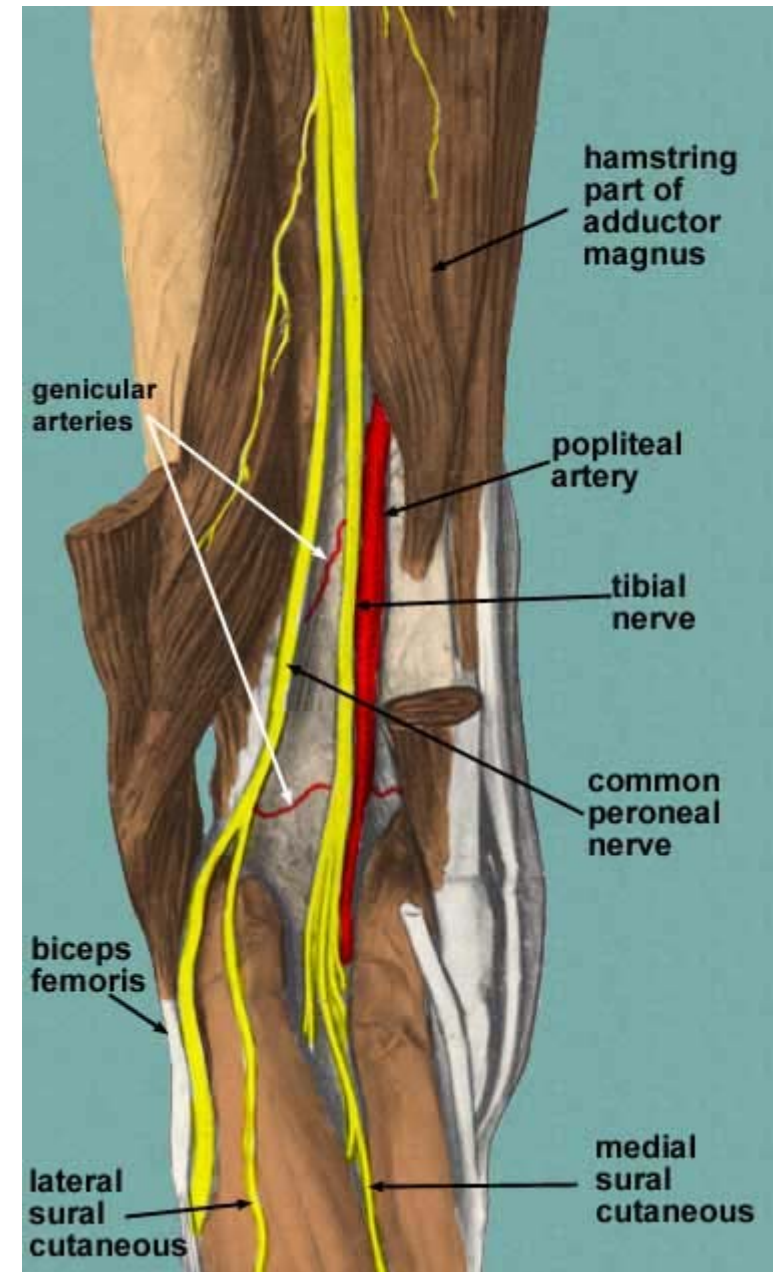




Boundaries

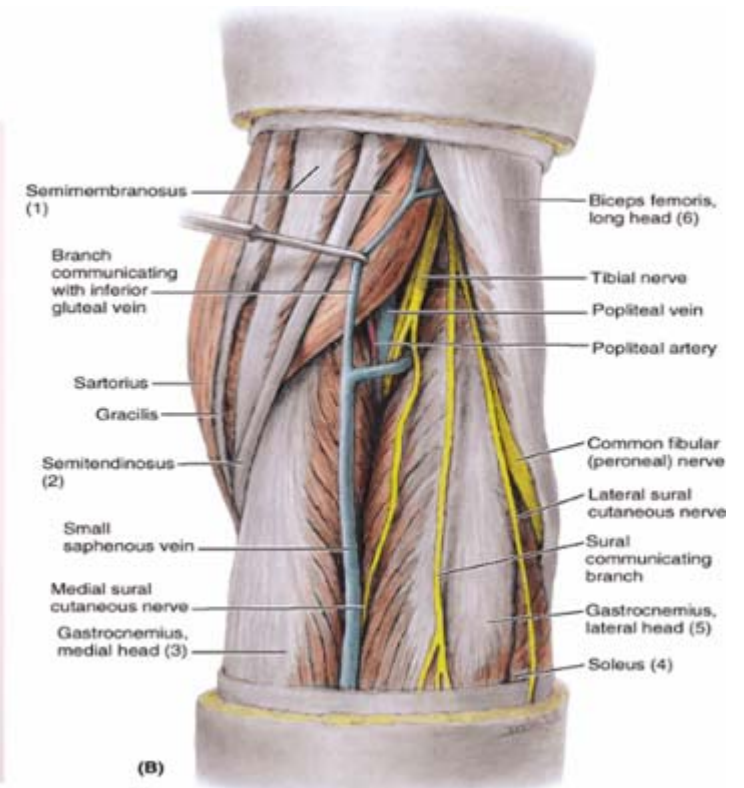
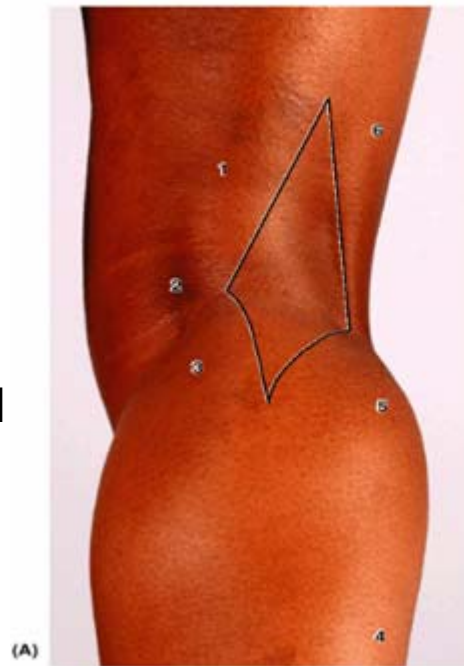
The boundaries of the fossa are:

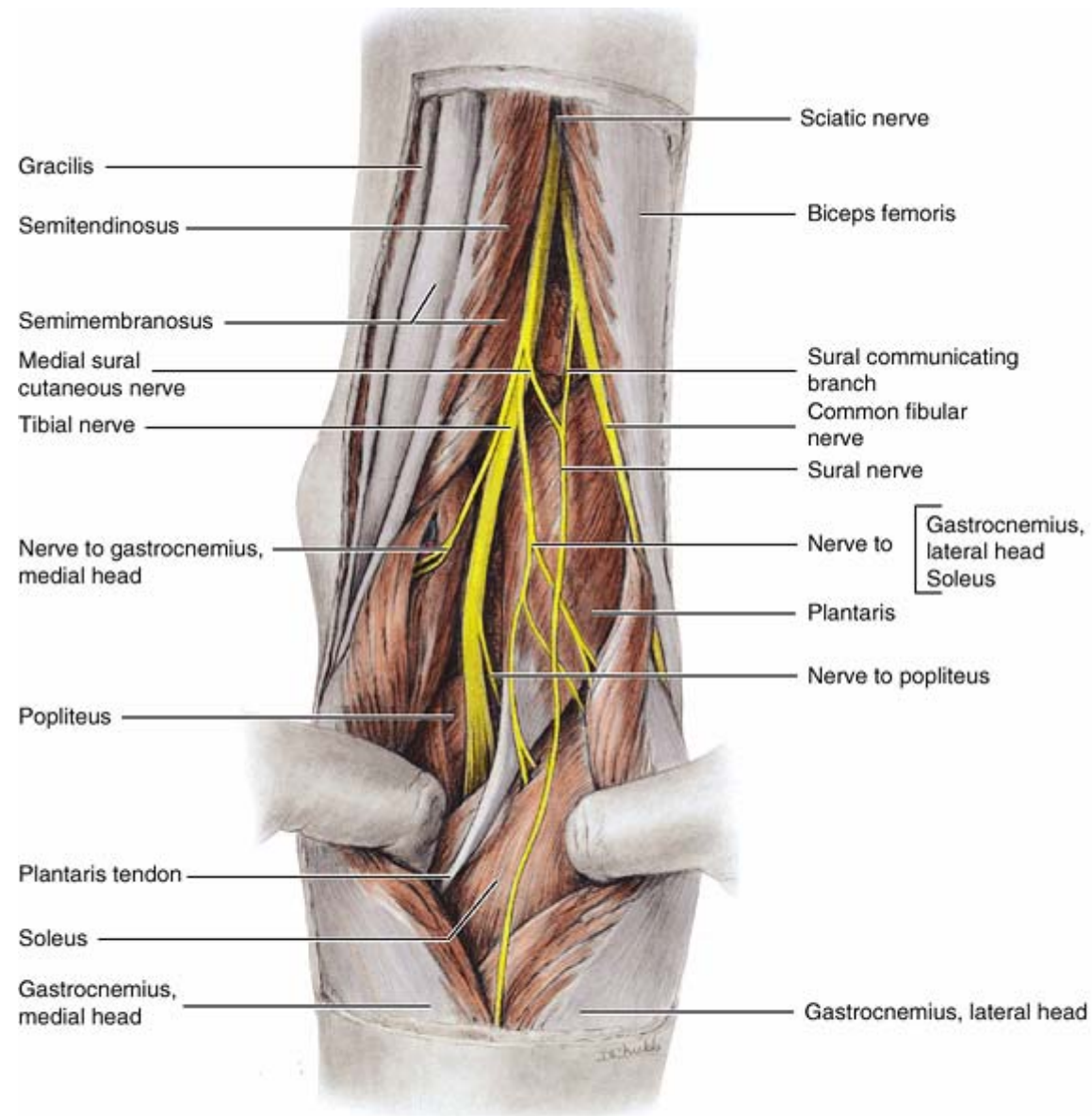
<p><i>superior and medial:</i> the <u>semitendinosus</u> muscle (<u>semimembranosus</u> is medial to the semitendinosus.)</p>	<p><i>superior and lateral:</i> the <u>biceps femoris</u> muscle</p>
<p><i>inferior and medial:</i> the medial head of the <u>gastrocnemius</u> muscle</p>	<p><i>inferior and lateral:</i> the lateral head of the gastrocnemius muscle</p>



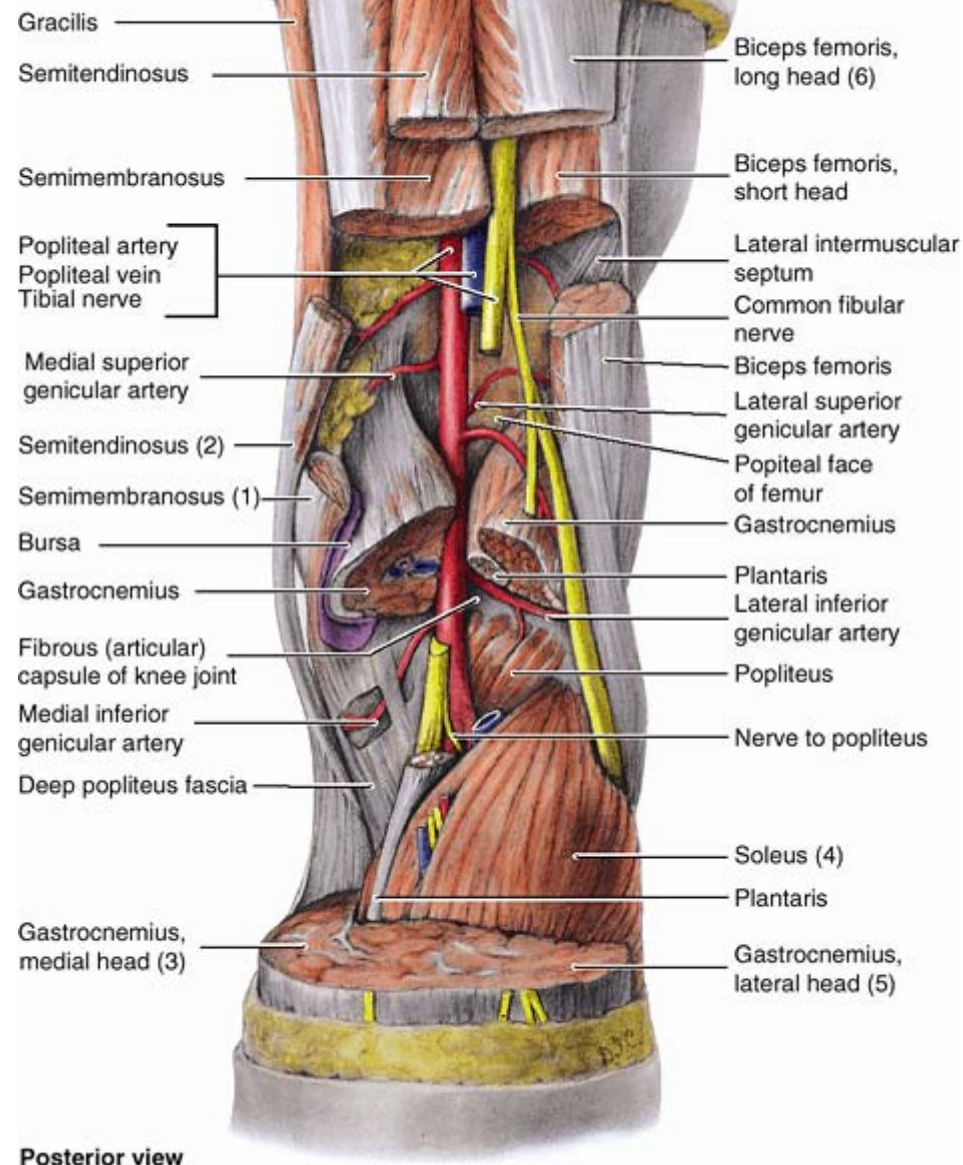
The popliteal fossa houses:

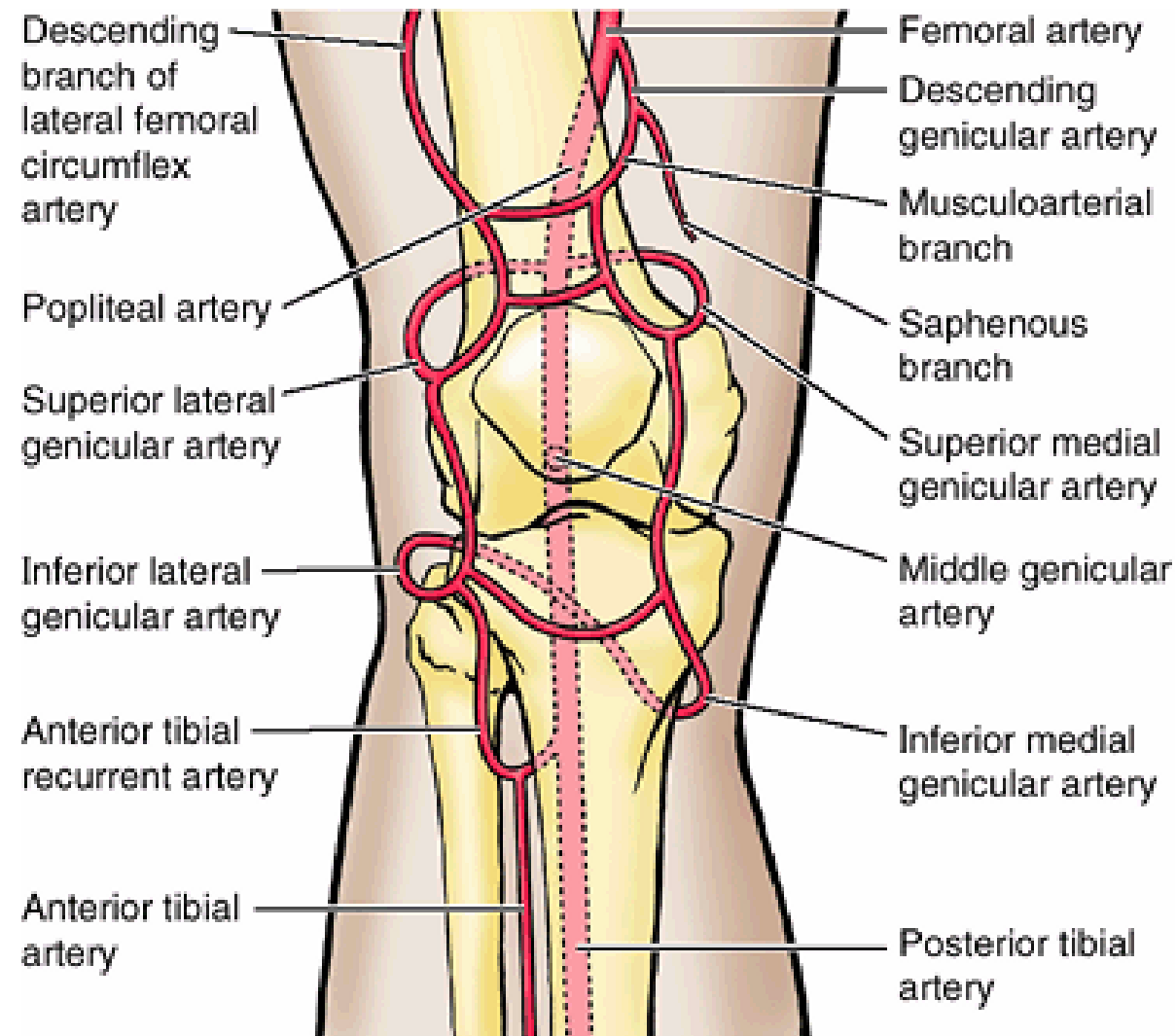
1. popliteal artery, which is a continuation of the femoral artery
2. popliteal vein
3. tibial nerve
4. common peroneal nerve
5. Six or seven popliteal lymph nodes are embedded in the fat
6. The roof contains a portion of the small saphenous vein and posterior cutaneous nerve of the thigh.





Posterior view





Anterior view