

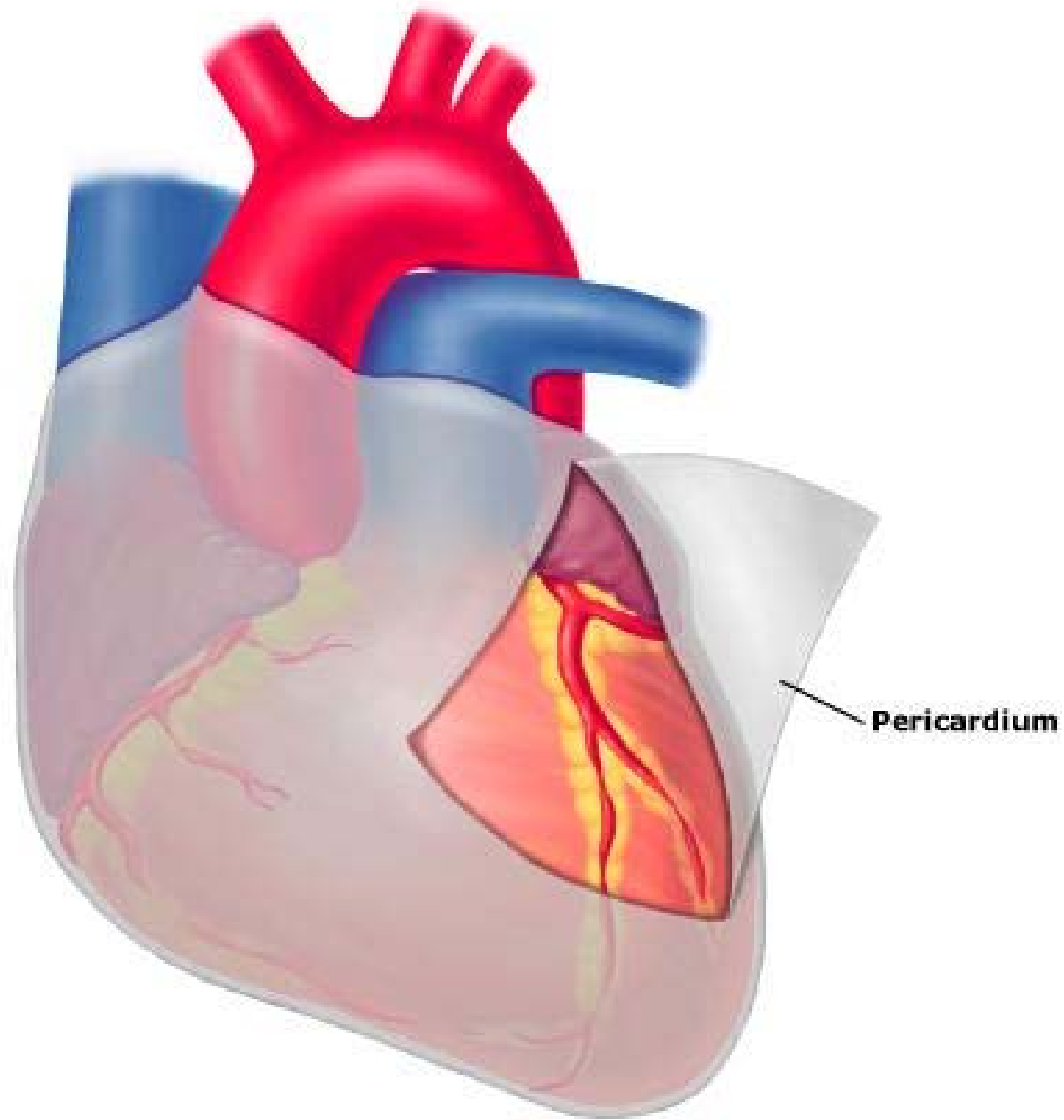
Pericardial disease

Usually secondary to systemic or other cardiac diseases

- Pericardial fluid accumulations
- Pericarditis

Pericardial Anatomy

- Two major components
 - visceral pericardium
mesothelial monolayer
facilitate fluid and ion exchange
 - parietal pericardium
fibrocollagenous tissue
- Pericardial Fluid
 - 15 - 50 ml of clear plasma ultrafiltrate



Pericardial Physiology

- Physiologic functions
 - limit cardiac dilatation
 - maintain normal ventricular compliance
 - reduce friction to cardiac movement
 - barrier to inflammation
 - limit cardiac displacement

Pericardial effusion & hemopericardium

- Pericardial effusion: ↑ fluid due to non-inflammatory causes
 - slow accumulation of 1000 ml can be accommodated
 - rapidly developing distension 200-300 ml causes compression of thin walled atria, ventricles → cardiac tamponade
- Hemopericardium: blood
 - rupture of myocardial infarct
 - rupture of dissecting aneurysm
 - bleeding diathesis
 - trauma

Pericarditis

- Acute
 - serous
 - fibrinous
 - purulent
 - hemorrhagic
- Chronic
 - tubercular
 - chronic adhesive
 - chronic constrictive

Serous pericarditis

- Serous effusion- 50-200ml, ↑ protein, high sp gravity
- Causes
 - Viral
 - Rh fever
 - Rheumatoid arthritis
 - SLE
- M/E: infiltration by some neutro, lymhos.
 - fluid usually resorbs with resolution of underlying disease

Fibrinous pericarditis

- Most common type, mixture of serous fluid and fibrinous exudate
- Causes
 - MI
 - Uremia
 - Rh fever
- Clinically- friction rub
- Morphology: normal transparent and glistening pericardium is turned into a dull, opaque, “sandy” sac
 - cardiac surface covered by dry or moist, shaggy fibrinous exudate- bread & butter appearance
- Complete resorption or healing by organisation

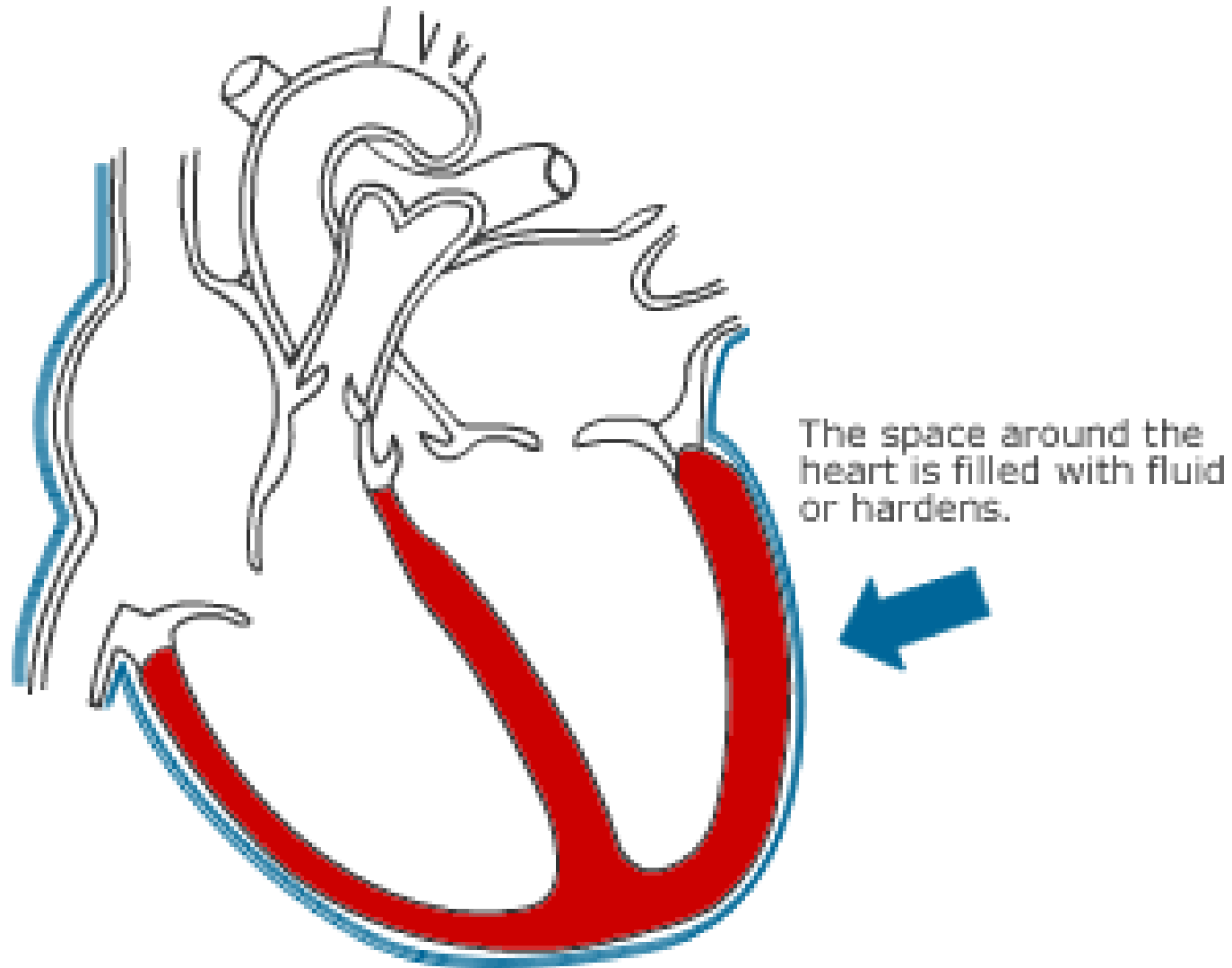
Purulent pericarditis

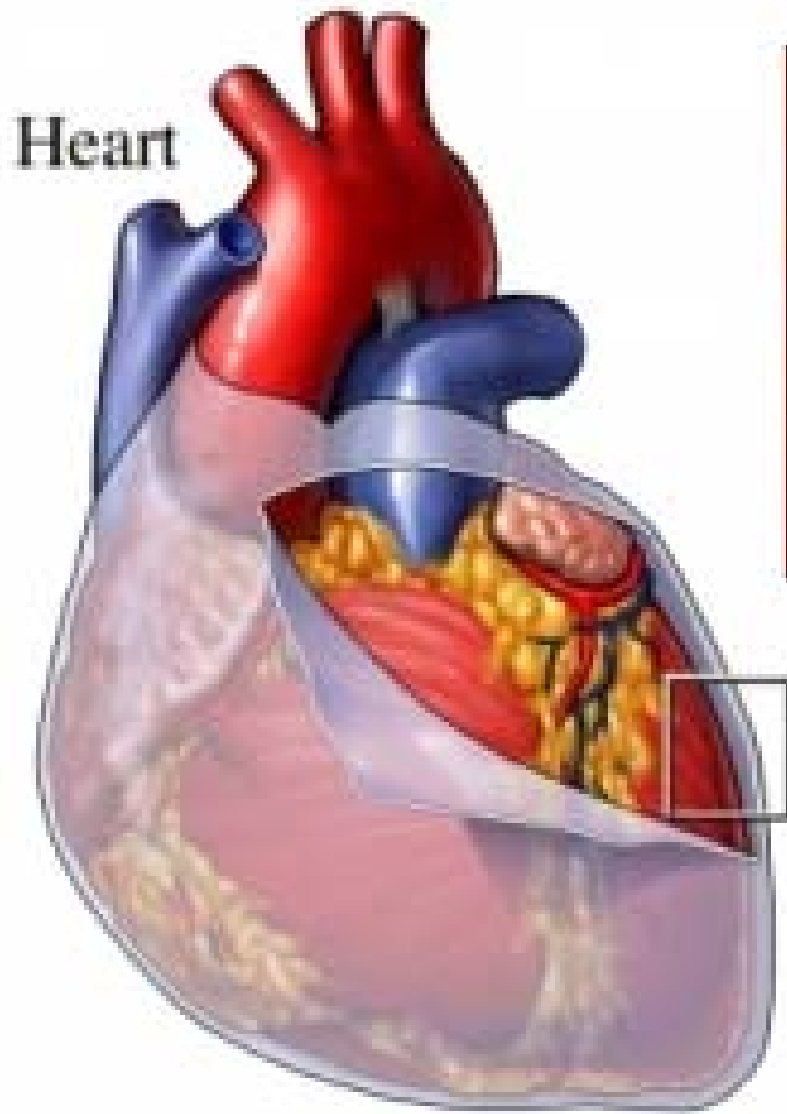
- Causes: pyogenic bacteria
- Spread
 - Contiguous spread: lungs, pleura, mediastinal lymph nodes, myocardium
 - Hematogenous spread: septicemia, toxins, neoplasm
 - Lymphatic spread
 - Traumatic or irradiation
- Gross: thick creamy pus coating the pericardial surfaces
- M/E: dense infiltration by neutrophils
- Does not resolve, heals by organisation

Acute pericarditis – diagnostic clues

- History: sudden onset of anterior chest pain
 - more likely to be sharp and pleuritic
 - ↑ with coughing, inspiration, swallowing
 - worse by lying supine, relieved by sitting and leaning forward
- Physical exam: presence of rub

The pumping action of the heart is restricted by the pericardial sac.





Normal pericardium



Inflamed pericardium

Tuberculous pericarditis

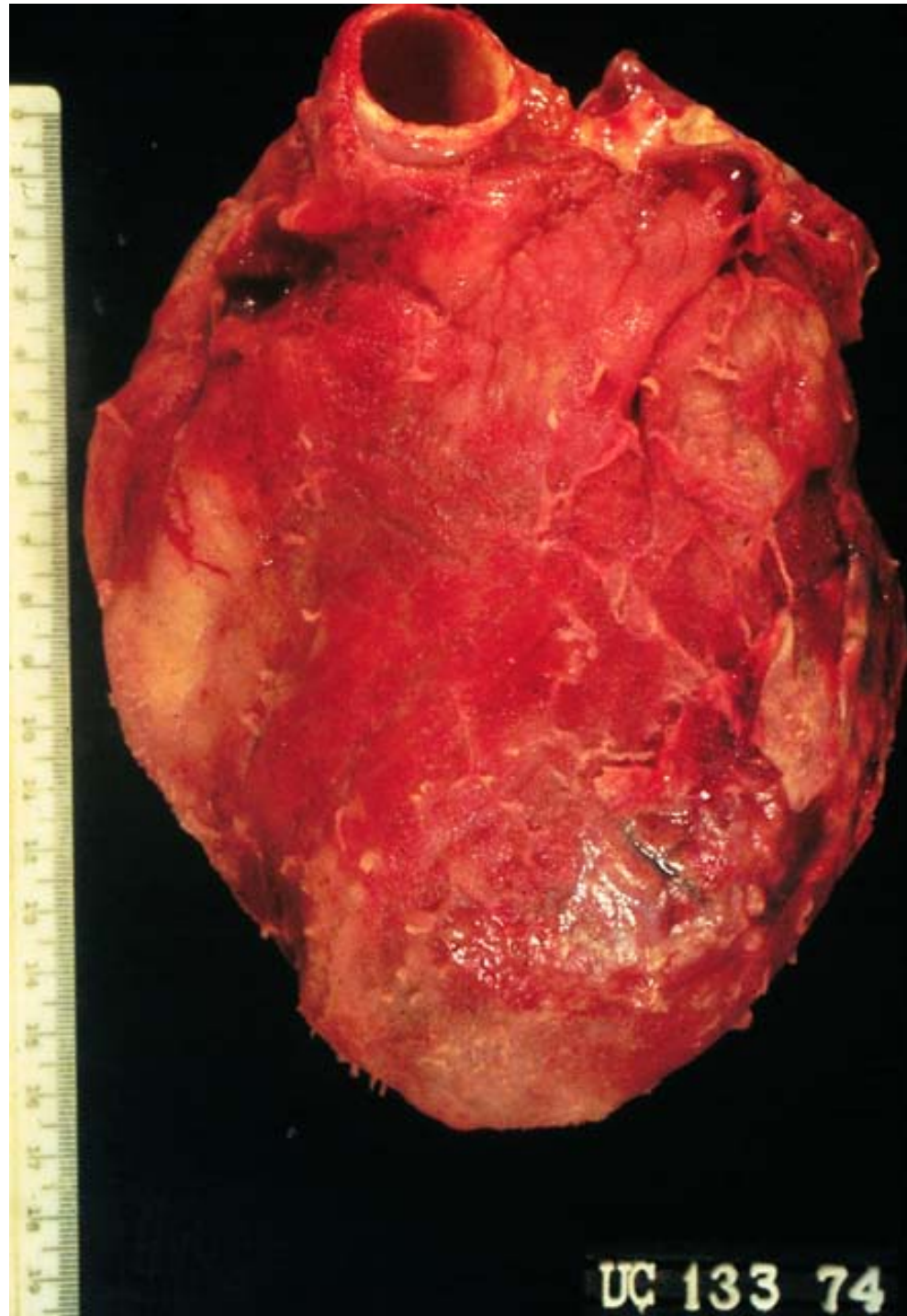
- Incidence of pericarditis in patients with pulmonary TB ranges from 1-8%
- Occurs by either direct extension from an adjacent focus or by lymphatic spread
- Physical findings: fever, pericardial friction rub
- TB skin test usually positive
- Fluid smear for TB often negative
- Pericardial biopsy more definitive: granulomas in pericardial wall
- Heal by fibrosis & calcification

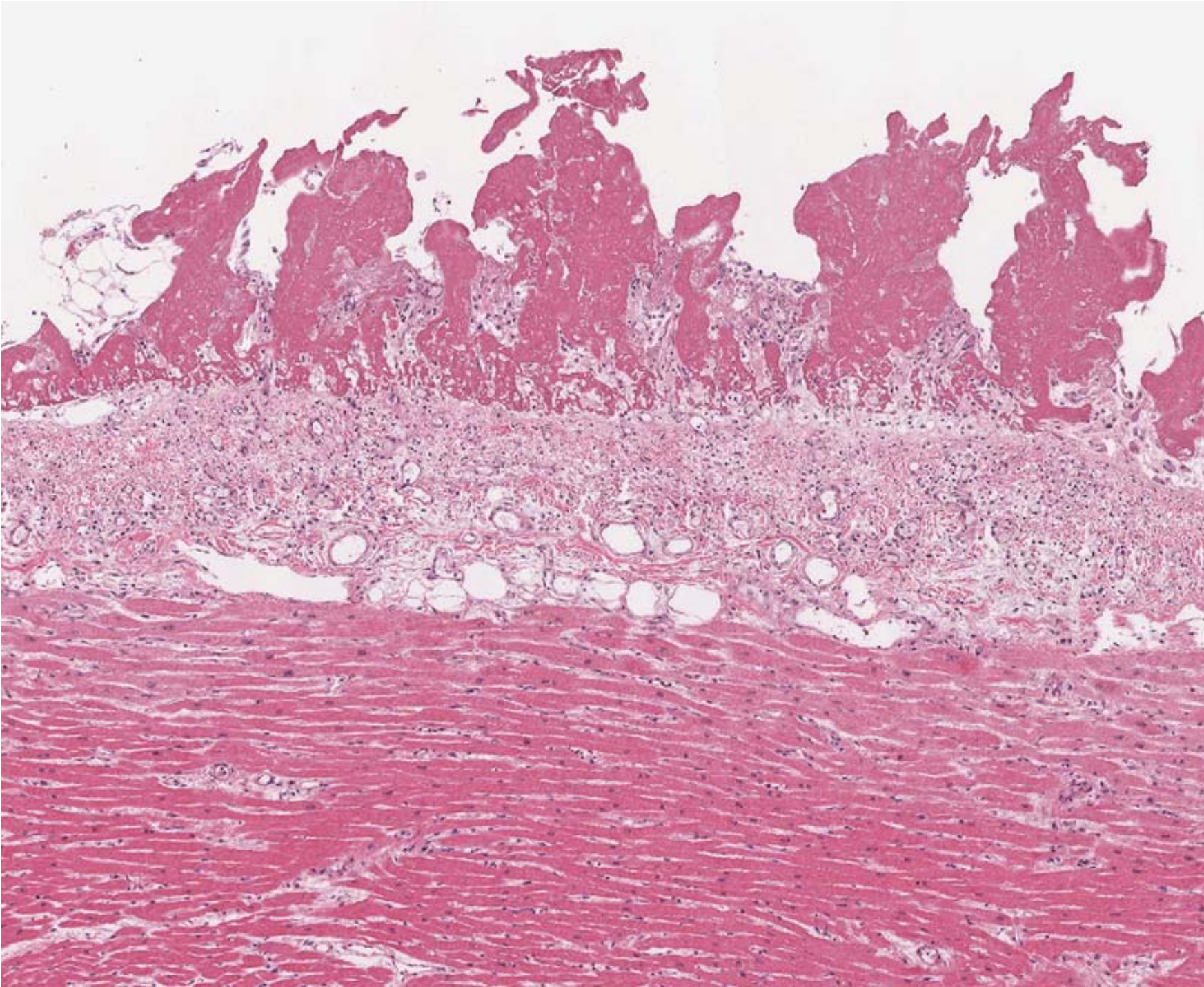
Chronic adhesive pericarditis

- Stage of organisation by fibrous adhesions
- Formation of granulation tissue & neovascularisation
- Adhesive mediastinopericarditis
- Heart function remains normal, cardiac hypertrophy & dilatation may occur

Constrictive pericarditis

- Rare, dense fibrous or fibrocalcific thickening of pericardium→ heart fails to dilate during diastole, decreased cardiac output
- Results from preceding causes- tubercular, purulent, hemopericardium
- Idiopathic, radiotherapy, cardiac surgery, connective tissue disorders
- Morphology: heart encased in .5- 1cm thick & dense collagenous scar
 - heart size normal





Dignostic evaluation

- Chest x-ray
 - usually requires > 200 ml of fluid
 - cannot distinguish between pericardial effusion and cardiomegaly
- Echocardiography
 - standard for diagnosing pericardial effusion
 - convenient, highly reliable, cost effective

Tumors of Heart

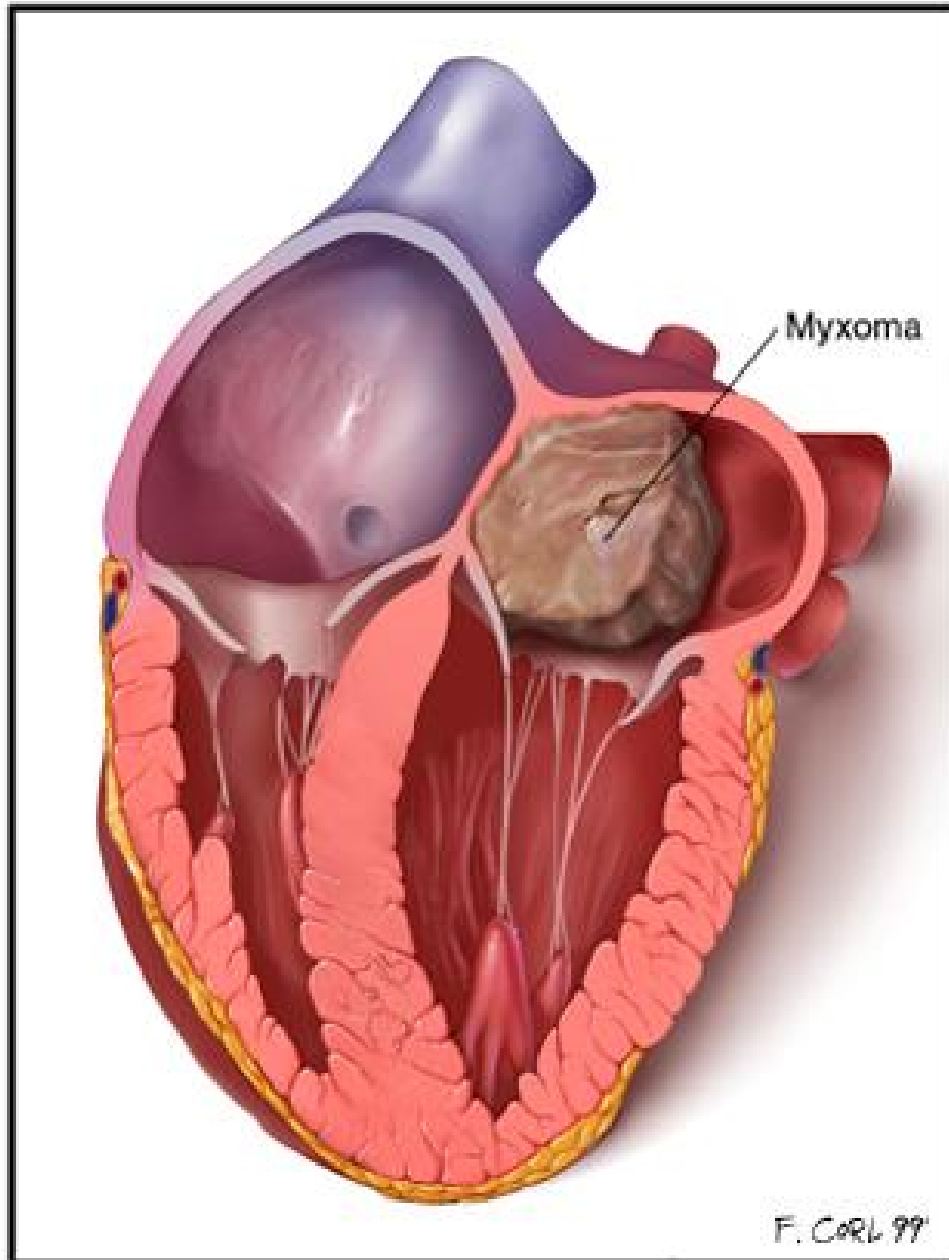
- Primary tumors < Secondary tumors
- Benign tumors:
myxoma, lipoma, fibroelastoma, rhabdomyoma,
hemangioma
- Malignant:
rhabdomyosarcoma, angiosarcoma, malignant
mesothelioma

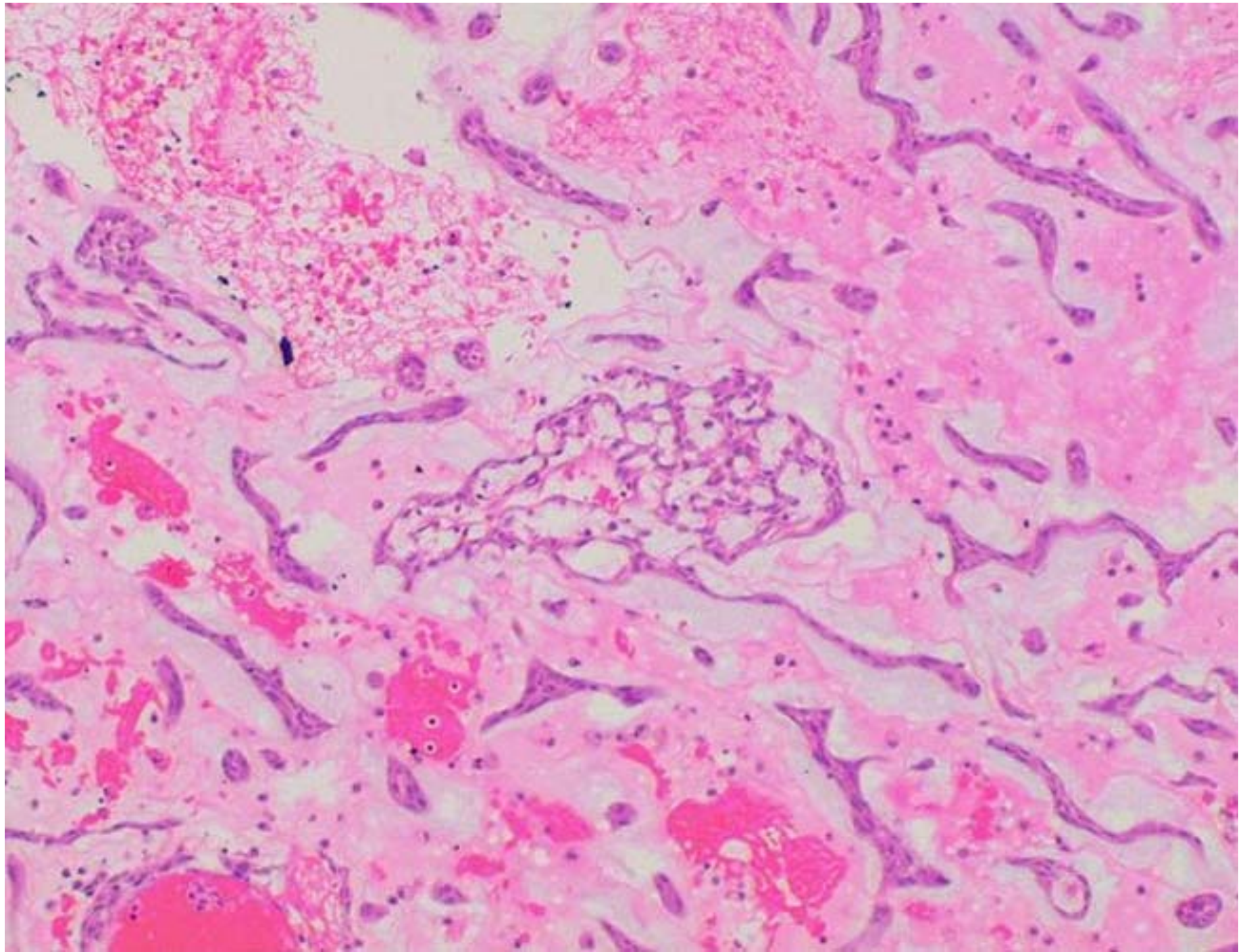
Myxoma

- M/C primary tumor of heart (50%)
 - Gross: 90% occur in left atrium
 - usually single, may be multiple
 - 1-10 cms D, polypoid, pedunculated, soft, hemorrhagic, resemble organised mural thrombus
- Micro: abundant mucoid intercellular stroma
- low cellularity with stellate shaped cells
 - numerous capillary sized bld vs
 - lymphocytes, plasma cells and foci of hemorrhages

Clinical effects:

- Ball- valve obstruction, damage to valve leaflets
- Embolization
- Constitutional symptoms of fever d/t IL6 release
- Part of Carneys syndrome





Secondary tumors

- Hematogenous or lymphatic spread from lung, breast, lymphoma, leukemia, melanoma
- Direct extension from intrathoracic tumor

Pathology of CV interventions

- Balloon angioplasty: dilation of stenosis of artery by a percutaneously inserted balloon catheter e.g percutaneous transluminal coronary angioplasty (PTCA)
 - Causes fracture of plaque, medial dissection, stretching of media of dissected segment
- Endovascular stents- are expandable tubes of mesh to preserve lumen patency: provide larger lumen, prevent mechanical vasospasm, dissections
- Vascular replacements- synthetic or autologous grafts that replace a segment of vessel or bypass diseased arteries

- Coronary artery bypass graft surgery
 - Aorto coronary bypass: autologous grafts using reversed saphenous vein or internal mammary artery
 - Failure due to rethrombosis, intimal fibrous hyperplasia, atherosclerosis
- Cardiac transplantation