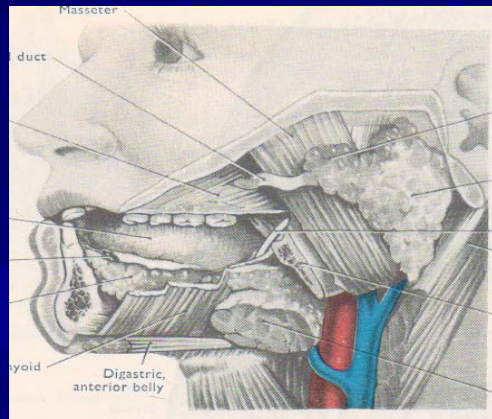


SALIVARY GLAND DISORDERS

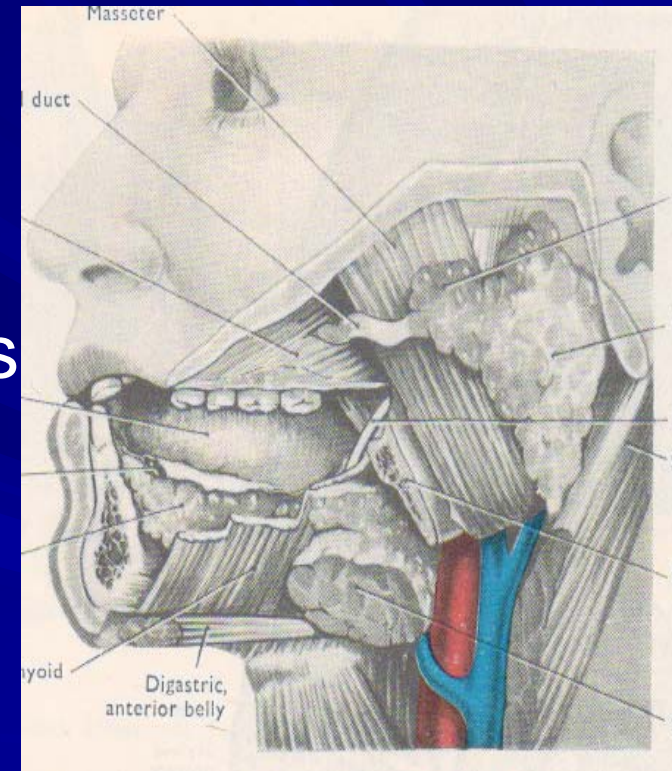


DR. ARJUN DASS

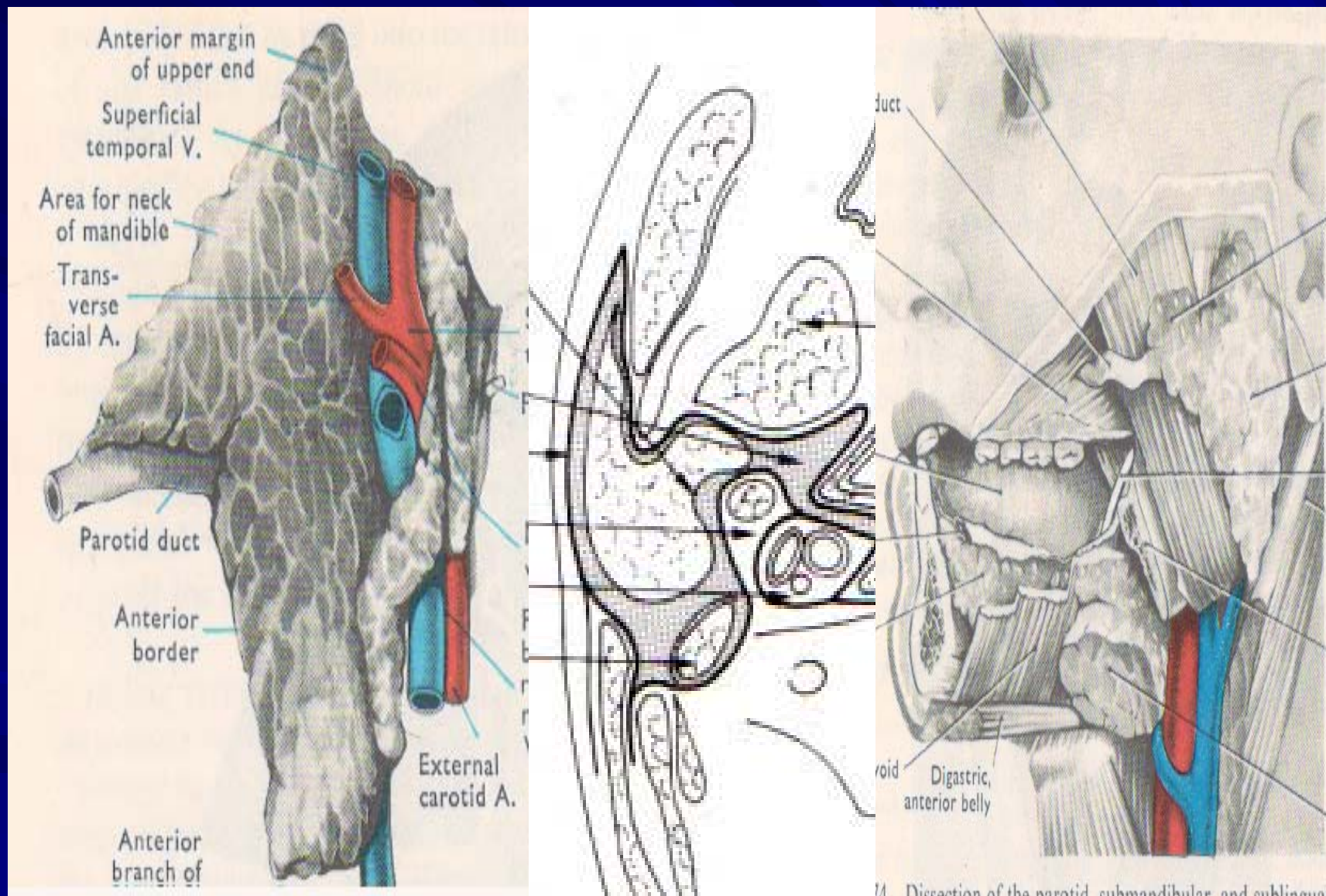
PROF. & HEAD

INTRODUCTION

- Four main salivary glands
- Two parotid glands
- Two submandibular glands
- Multiple minor salivary glands in the upper respiratory track



ANATOMY



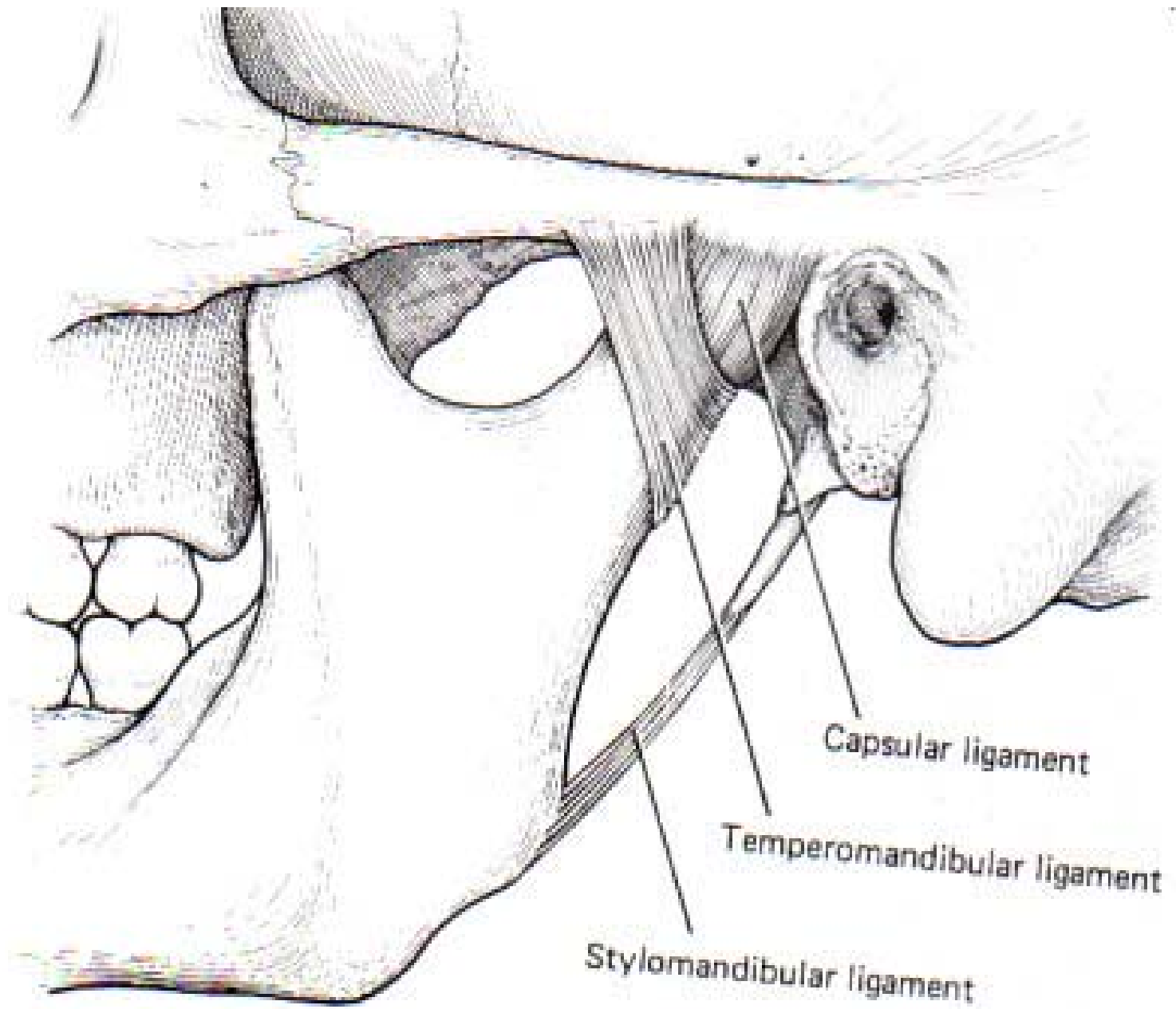
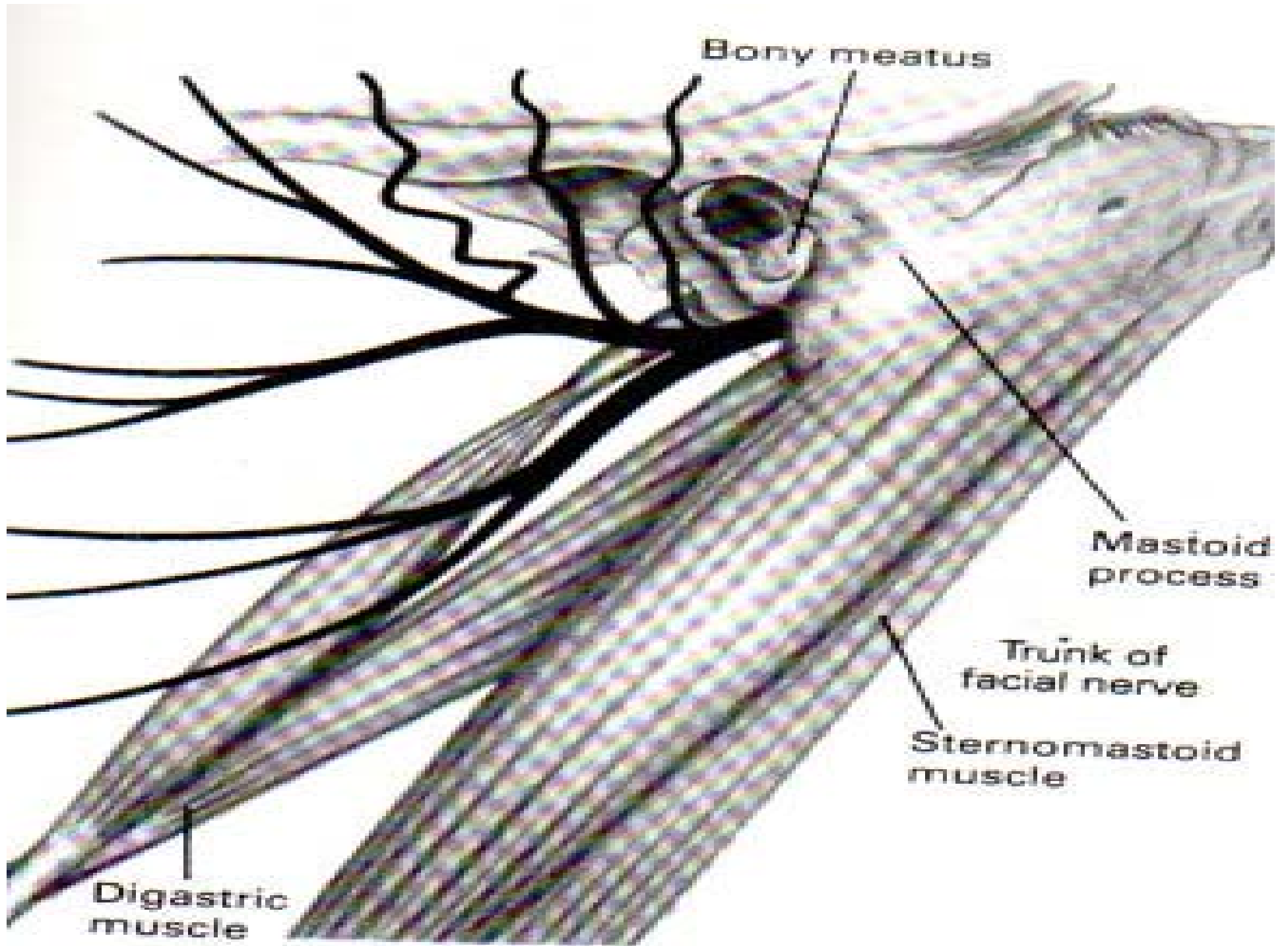
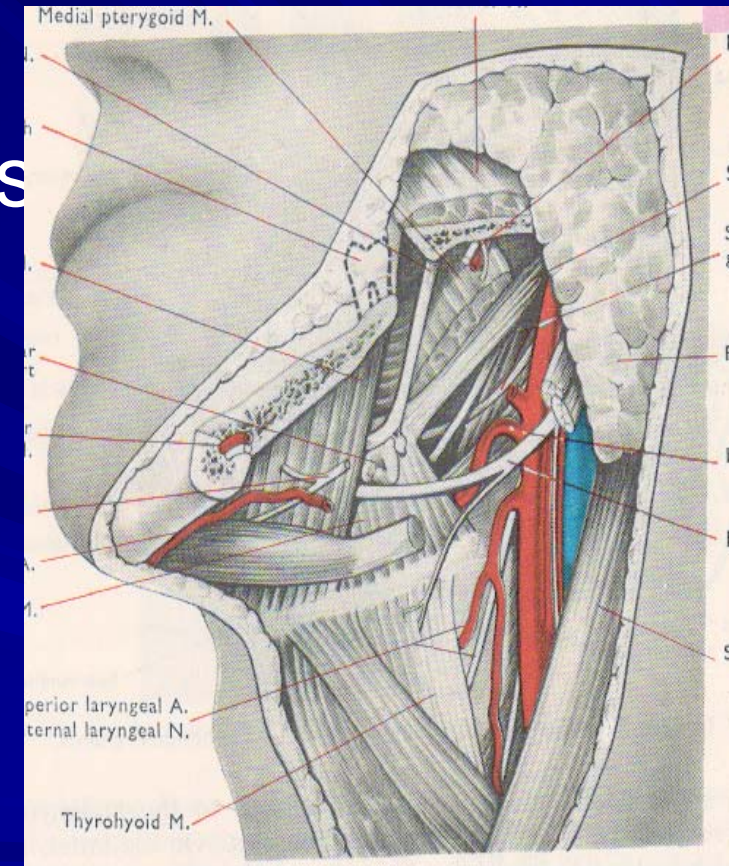


Figure 20.2 The stylomandibular ligament



IMPORTANT STRUCTURES THAT PASS THROUGH PAROTID GLAND

- Facial nerve
- Terminal part and branches of external carotid artery
- Maxillary artery
- Superficial temporal artery
- Retromandibular vein
- Intra parotid lymph nodes



SUBMANDIBULAR GLAND

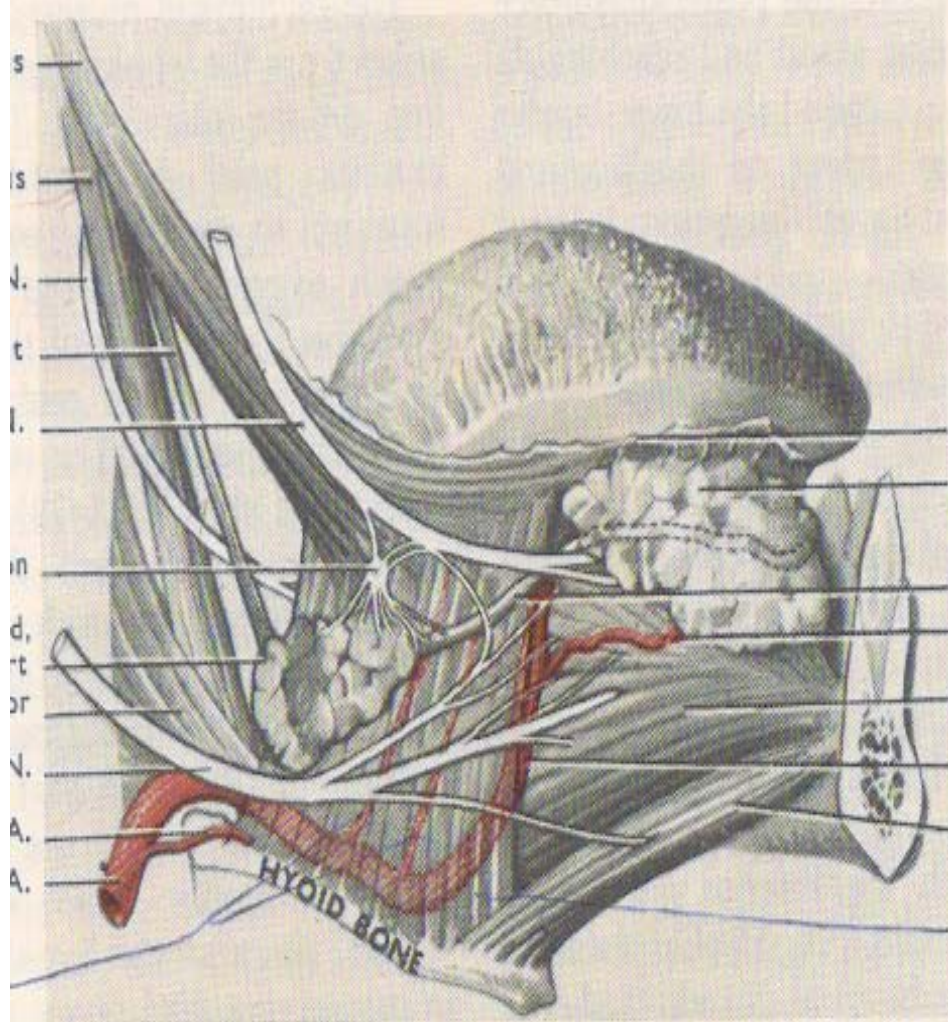


FIG. 76. Dissection of the submandibular region.

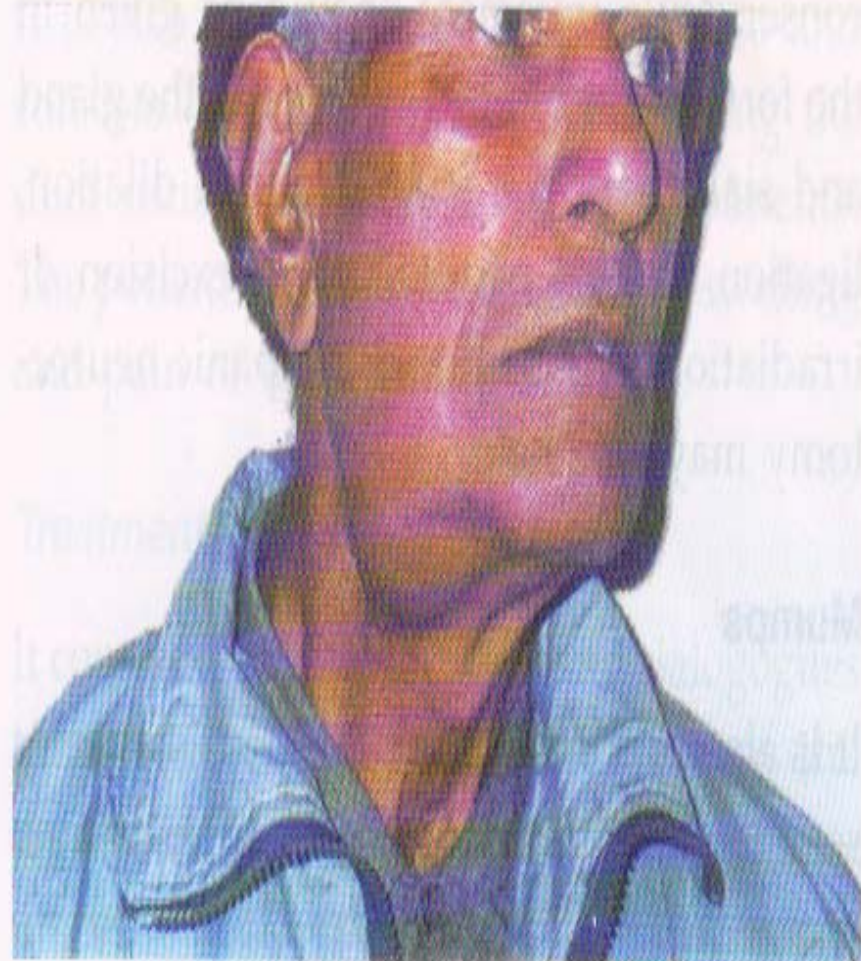


Fig. 31-1. Swelling of submandibular gland.

SALIVARY GLANDS LESIONS

- Congenital
- Inflammatory
 - Viral
 - Bacterial
- Traumatic
- Neoplasm
 - Benign
 - Malignant

INFLAMMATORY DISORDERS

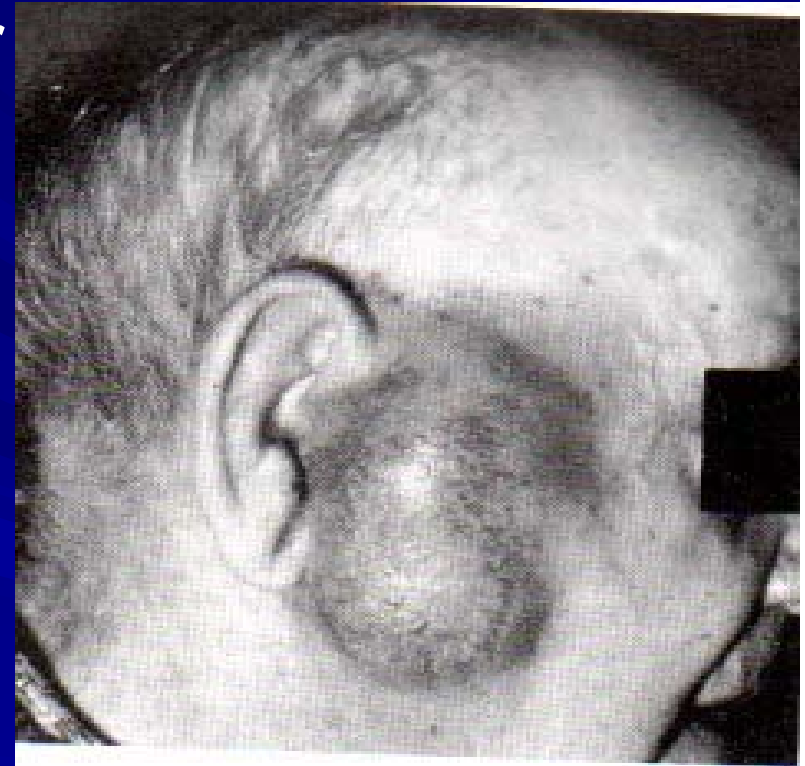- Viral infections (Mumps)
- acute painful parotid swelling
- children
- airborne droplet infection
- ex on meals
- Complications
- Orchitis ,oophritis, pancreatitis ,SNHL, meningoencephlitis

TREATMENT

- Analgesics
- Fluid intake
- Life long immunity

BACTERIAL INFECTION

- Acute Suppurative Sialadenitis
- May involve parotid or submandibular gland
- Ascending infection
- Staph aureus , strep.
- Dehydrated old / young children



ACUTE SUPPURATIVE SIALADENITIS

Clinical Features :

- Malaise, pyrexia , cx LAP
- Examination : pus from duct opening

Management :

- USG
- I.V Antibiotics
- Drainage

CHRONIC SIALADENITIS

- Chronic infection of salivary gland can lead to firm, mild enlargement of the gland with repeated acute infection
- More in parotid gland followed by submandibular gland
- History of recurrent mildly painful enlargement of gland. Massage of gland produces scanty secretions at the opening of the duct

MANAGEMENT

- USG
- Papillotomy
- Removal of calculus
- Antibiotic
- Massage of the gland
- Total gland excision
- Tympanic neurectomy

SALIVARY GLAND TUMOURS

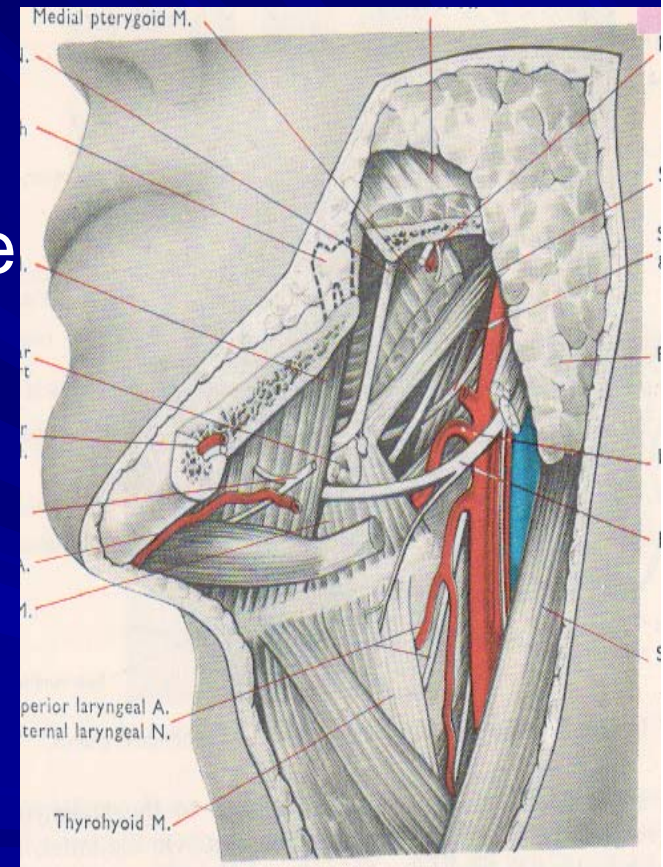
- Tumours of salivary glands represent a complex and histopathologically diverse group of tumour
- Diagnosis and management is complicated by the fact that they are infrequent
- Making up only 1% of head and neck tumour
- Proper management requires accurate diagnosis by the pathologists and physicians

Salivary gland tumours

	Benign	malignant
• Parotid	80-90%	10-20%
• Submandibular	50%	50%
• Sublingual	5%	95%
• Minor	10%	90%

PAROTID TUMOURS

- Most common site of salivary neoplasm
- Mainly arise from superficial lobe
- Slow growing painless mass below or in front of pinna
- Deep lobe tumours present as parapharyngeal mass
- Dysphagia / snoring / mass in oropharynx



PLEOMORPHIC ADENOMA

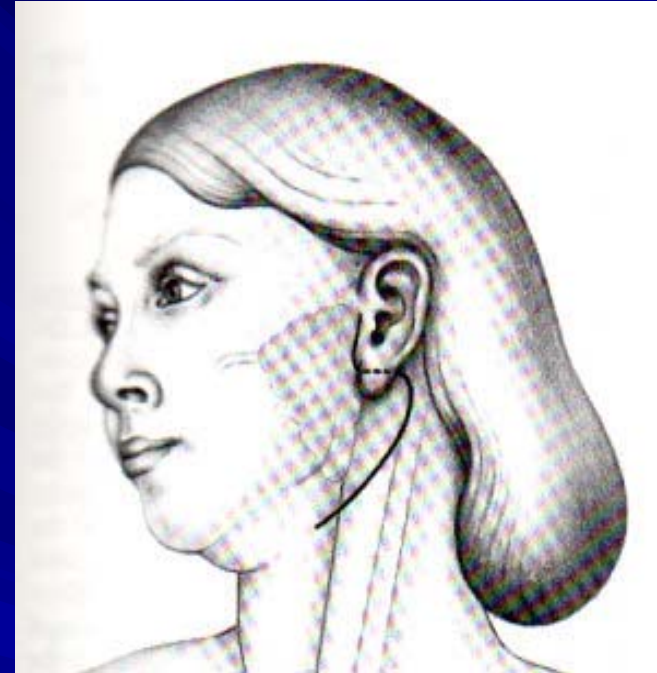- Most common benign tumour
- Can arise from parotid, submandibular or other salivary gland
- In the parotid it usually arises from tail
- Slow growing tumour
- Seen in 3rd or 4th decade
- More in female
- Both epithelial and mesenchymal elements are seen

DIAGNOSIS

- History
- Clinical examination
- FNAC
- Ultrasonography
- CT Scan
- MRI

TREATMENT

- Surgical Excision
- Superficial parotidectomy
- Total parotidectomy with preservation of facial nerve



WARTHIN'S TUMOUR

- More common in male (5:1)
- Seen between 5th & 7th decade
- Mostly involve tail of parotid
- Bilateral in 10%
- May be multiple
- Rounded, encapsulated at time cystic
- **Treatment** : Superficial parotidectomy

CLINICAL FEATURES OF MALIGNANT SALIVARY TUMOURS

- Facial palsy
- Rapid increase in size
- Hard mass / ulceration
- Cervical lymphadenopathy

SIALADENOSIS

- Non inflammatory swelling affecting salivary glands
 1. Diabetes mellitus
 2. Alcoholism , pregnancy
 3. Bulemia
 4. Drugs
 5. idiopathic

DEGENERATIVE CONDITIONS

Sjogren syndrome

- Autoimmune
- Progressive destruction of salivary and lacrimal glands
- xerostomia
- Primary
- Secondary connective tissue disorders

DISEASES OF SUBMANDIBULAR GLAND

- Inflammatory conditions
 - Viral
 - Bacterial
- Obstructive
 - calculus
 - trauma
- Tumours

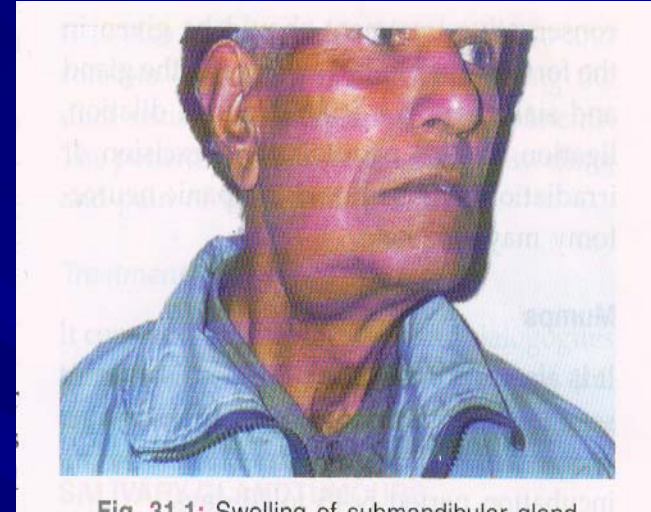


Fig. 31.1: Swelling of submandibular gland

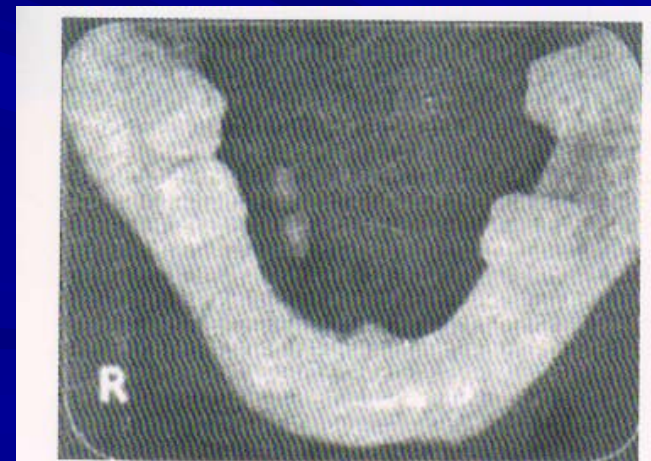

Fig. 31.2: X-ray showing salivary calculus

THANK YOU

