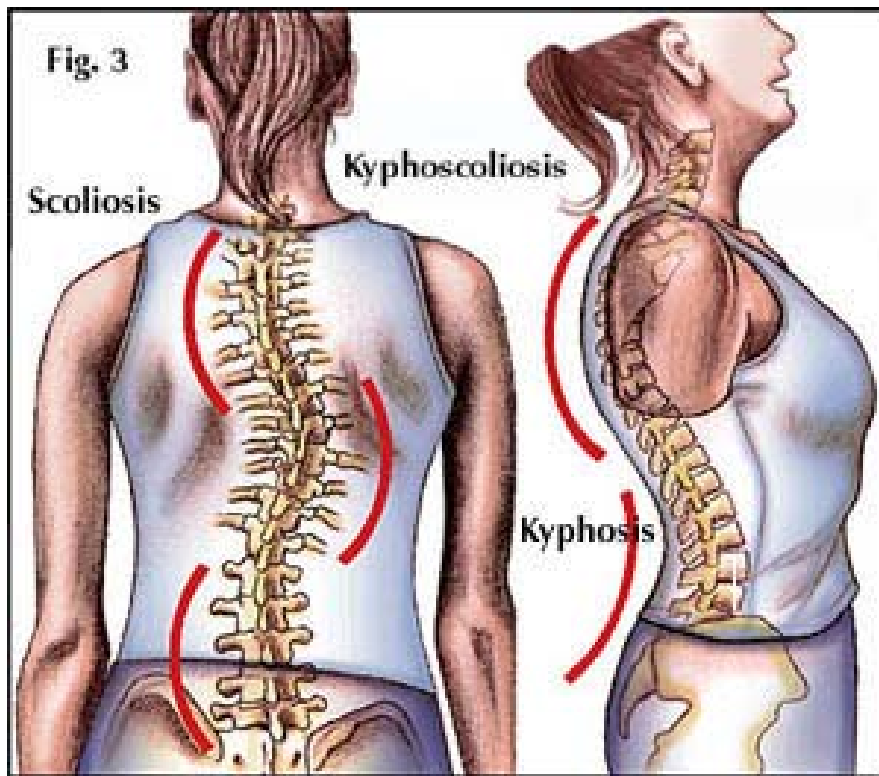


Anaesthetic considerations in management of kyphoscoliosis

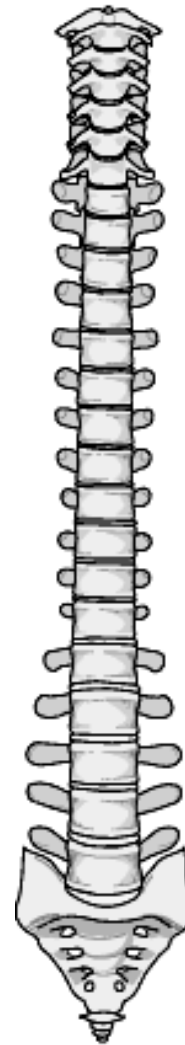


Overview

- Anatomy and definition
- Prevalence
- Types
- Signs & symptoms
- Severity and Cobb's angle
- Effects of kyphoscoliosis on various organ systems
- Surgical correction
- Preoperative evaluation
- Management of anaesthesia

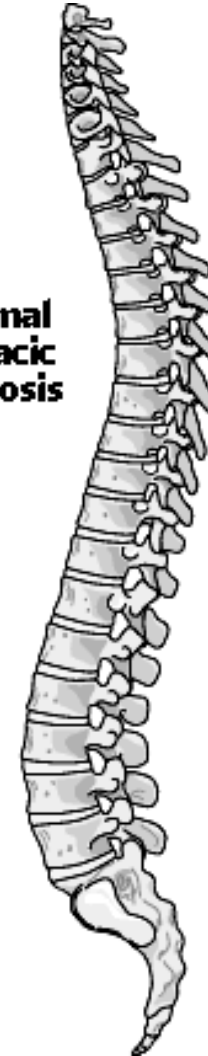Normal curves of spine

- In thoracic region spine curves posteriorly known as thoracic kyphosis.
- In lumbar region spine curves anteriorly known as lumbar lordosis.



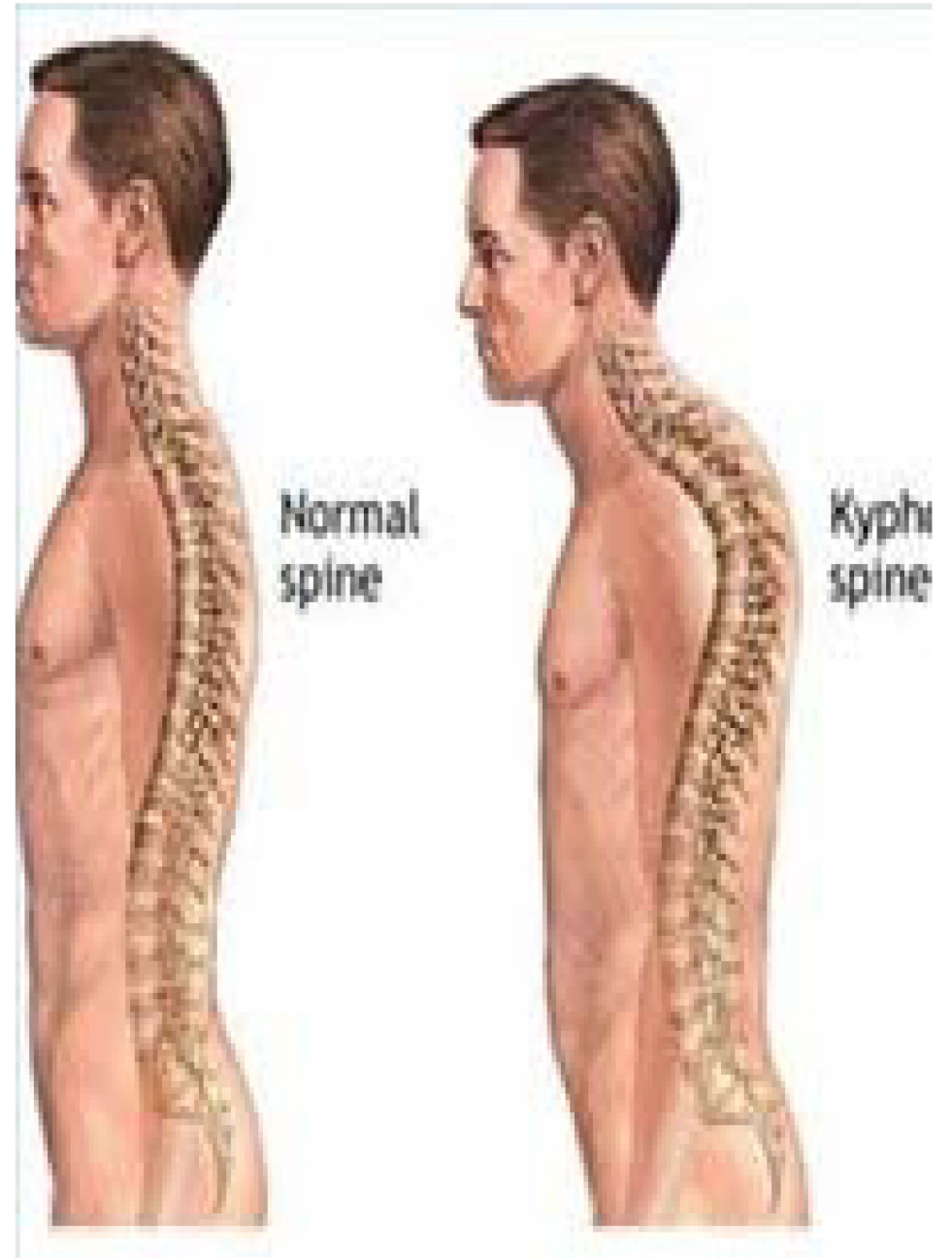
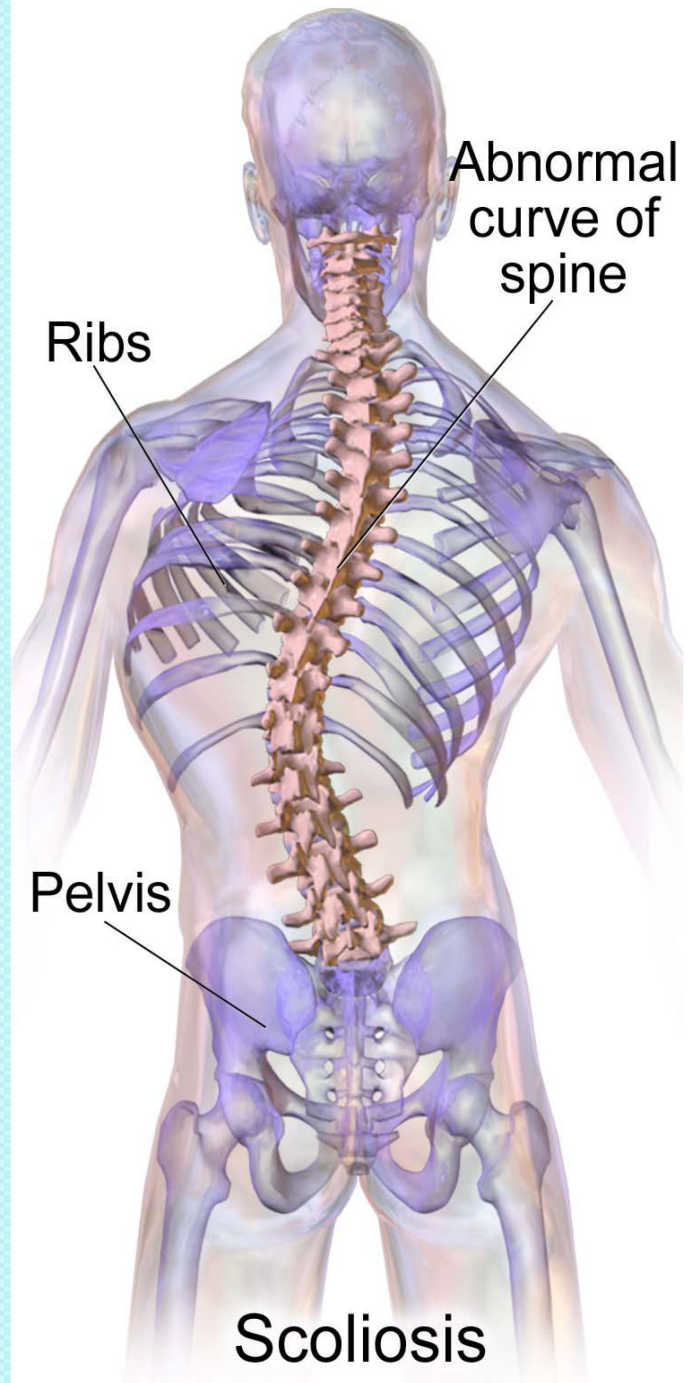
**Normal
thoracic
kyphosis**

**Normal
lumbar
lordosis**

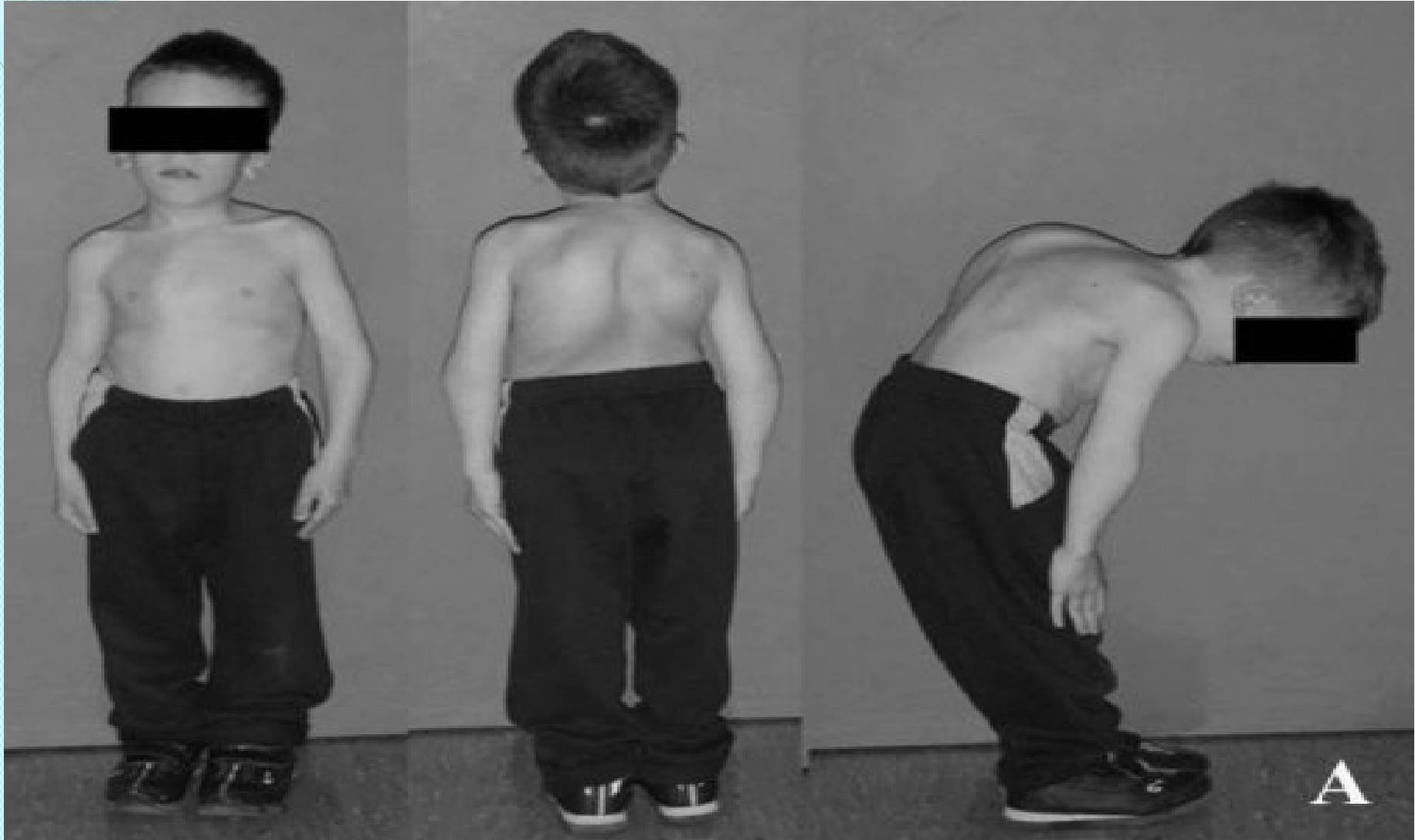

Definition

- Kyphoscoliosis describes an abnormal curvature of the spine in both a coronal and sagittal plane
- Kyphosis is a curving of the spine that causes a bowing of the back
- Scoliosis is defined as a lateral rotation of the spine greater than 10 degrees accompanied by vertebral rotation

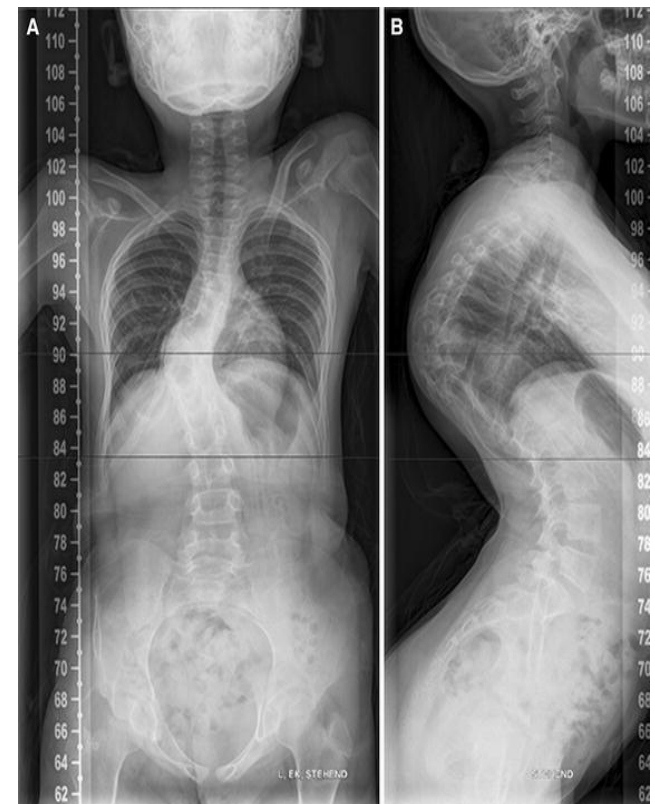

Kyphoscoliosis



Prevalence

- Curves $>10^\circ$: 1.5 – 3% of population
- Curves $>20^\circ$: 0.3 to 0.5%
- Curves $>30^\circ$: 0.2 to 0.3%
- Most curves convex to the right
- Males are more likely to have infantile/ juvenile scoliosis
- Females- adolescent scoliosis







2. Neuromuscular scoliosis (paralytic scoliosis)

- **Neuropathic**

- Upper motor neuron (CP, spinal cord injury)

- Lower motor neuron (poliomyelitis, meningomyelocele)

- Familial dysautonomia

- Myopathic**

- Muscular dystrophy

- Myotonic dystrophy



3. Congenital scoliosis

- Abnormality of development of vertebrae – hemivertebrae/congenitally fused ribs
- 1/2 cases associated with other organ system abnormalities

4. Neurofiromatosis mesenchymal disorders

- Marfan's syndrome
- Ehlers Danlos syndrome



5. Trauma

- Vertebral fracture or surgery
- Post thoracoplasty
- Post radiation

Types of kyphosis

- Postural kyphosis
 - most common type
- Scheuermann's kyphosis
 - a form of juvenile osteochondrosis of the spine
- Congenital kyphosis
- Nutritional kyphosis
 - Vit D deficiency
- Gibbus deformity
 - Tuberculosis
- Post-traumatic kyphosis

Associated conditions

- Cerebral palsy
- Cerebral muscular dystrophy
- Spina bifida
- Duchenne's muscular dystrophy
- Familial dysautonomia
- Friedreich's ataxia
- Skeletal dysplasia
- Marfan's syndrome
- Neurofibromatosis
- Connective tissue disorders
- Craniospinal axis disorders : syringomyelia

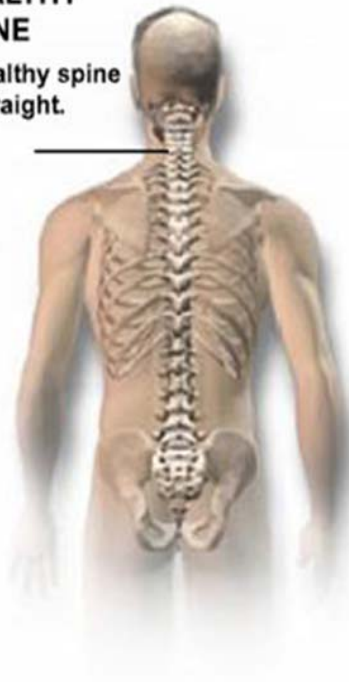Signs and Symptoms

- Back pain
- Leg length discrepancy
- Abnormal gait
- Uneven hips or waist
- One shoulder higher than other
- Prominent shoulder blade.
- Appearance of leaning to one side
- Increased space between the body and the elbow while standing in natural posture.
- Chest/rib prominence.

Scoliosis

HEALTHY SPINE

A healthy spine is straight.

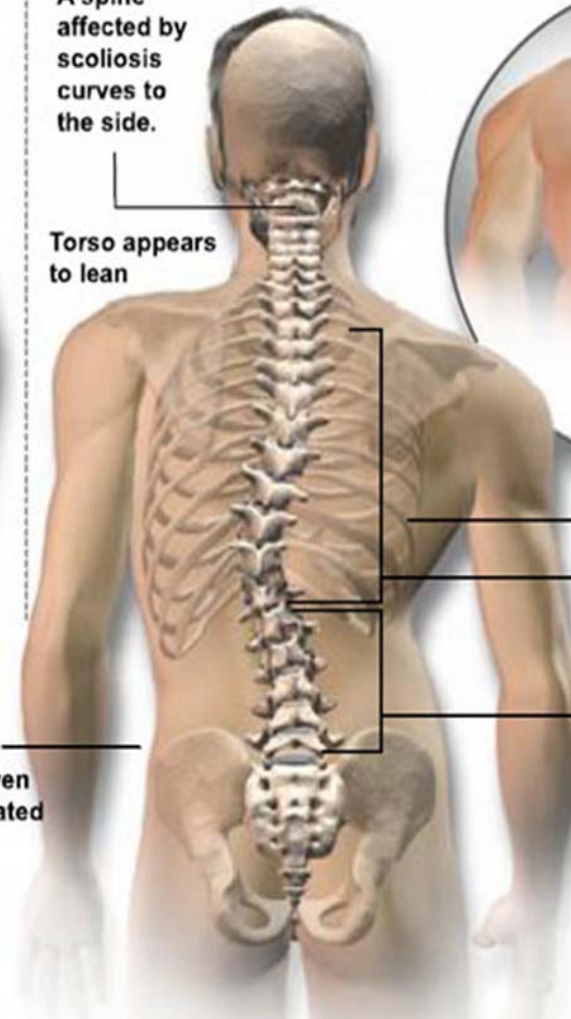


SYMPTOMS OF SCOLIOSIS

A spine affected by scoliosis curves to the side.

Torso appears to lean

Waist may appear uneven or hips elevated



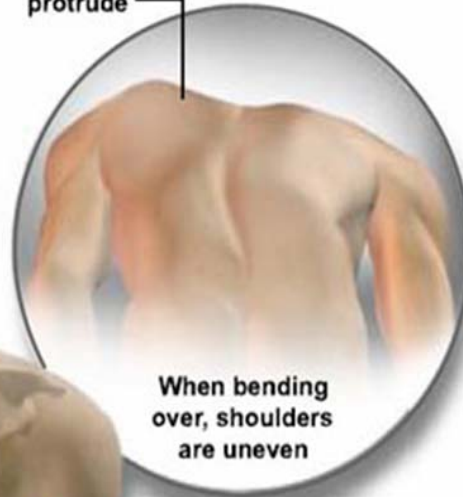One or both shoulder blades protrude

When bending over, shoulders are uneven

Misshaped rib cage

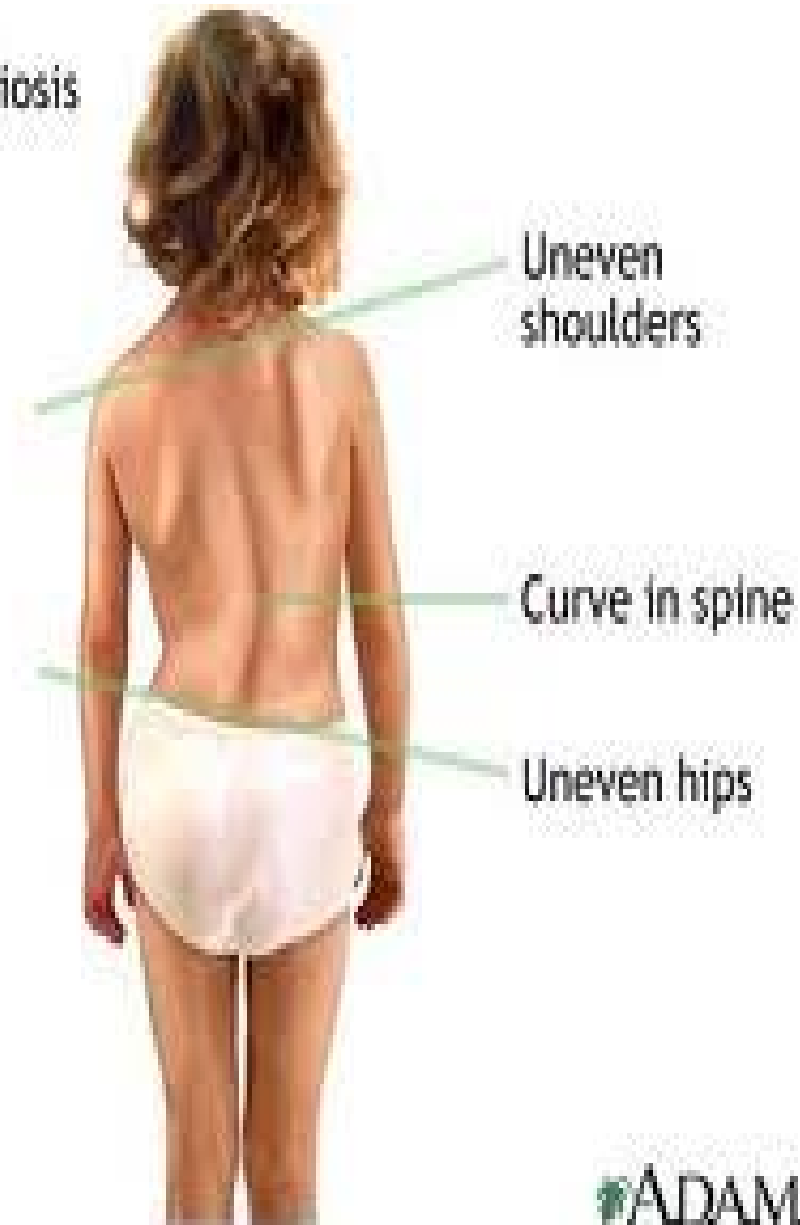A curvature may be seen in the mid back (thorax) ...

... or it may be seen in the lower back (lumbar).



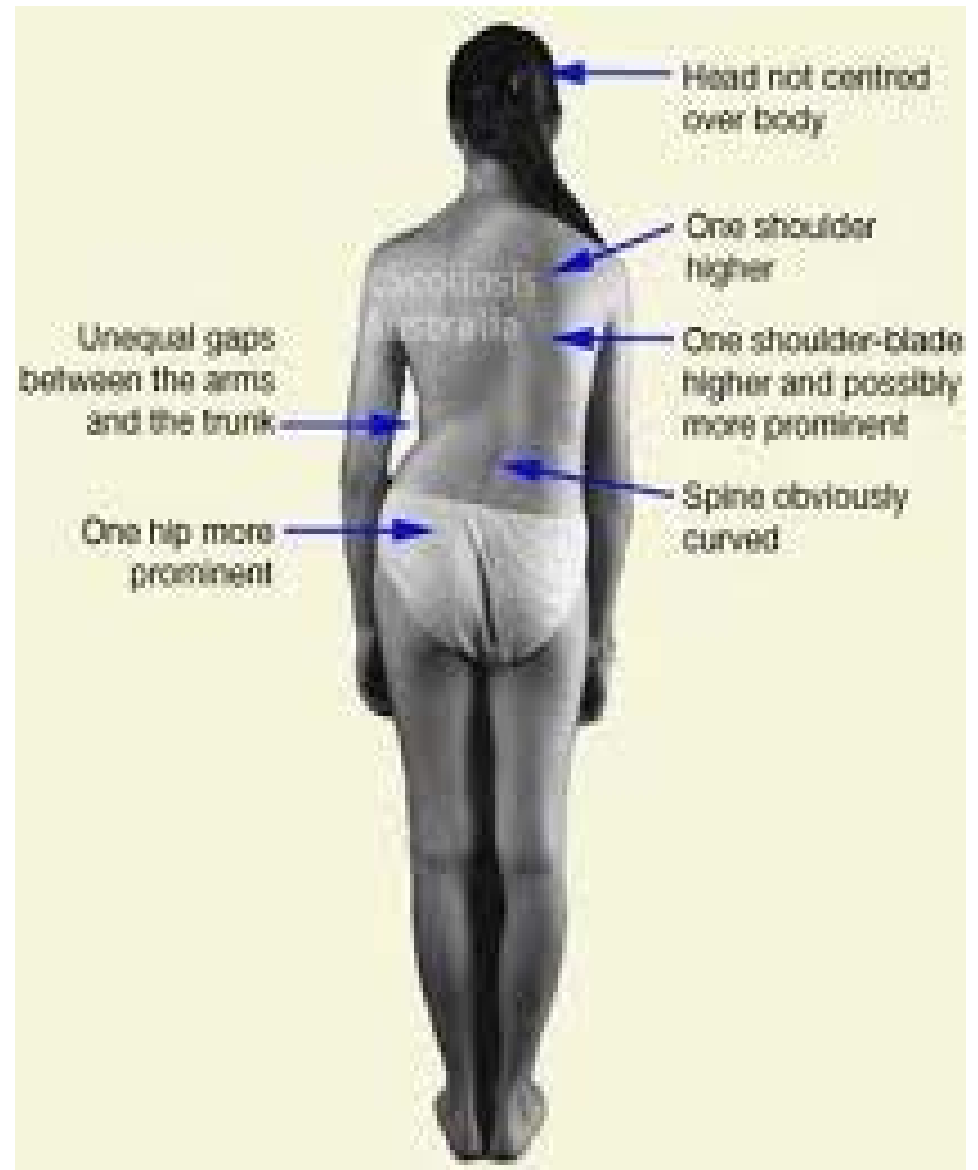
Signs of scoliosis

Signs of scoliosis



Physical examination

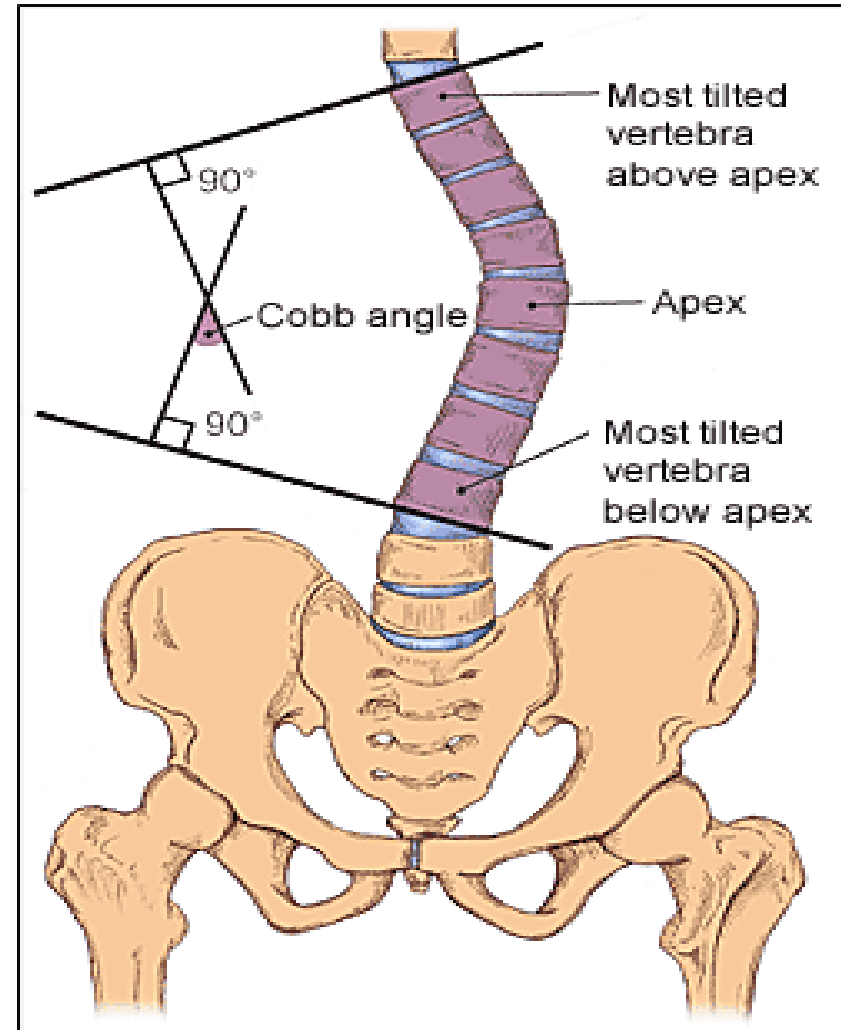
- Feet for cavovarus deformity
- Muscle tone – spasticity
- Gait
- Thorough neurological exam



Assessment of severity

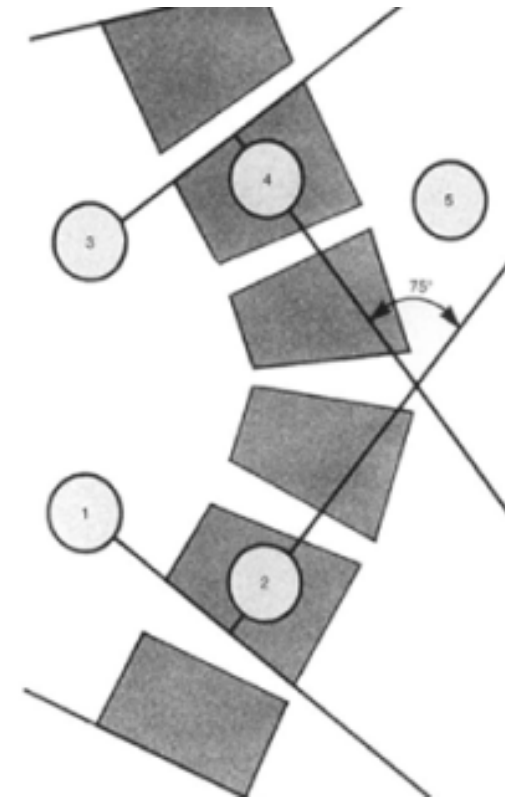
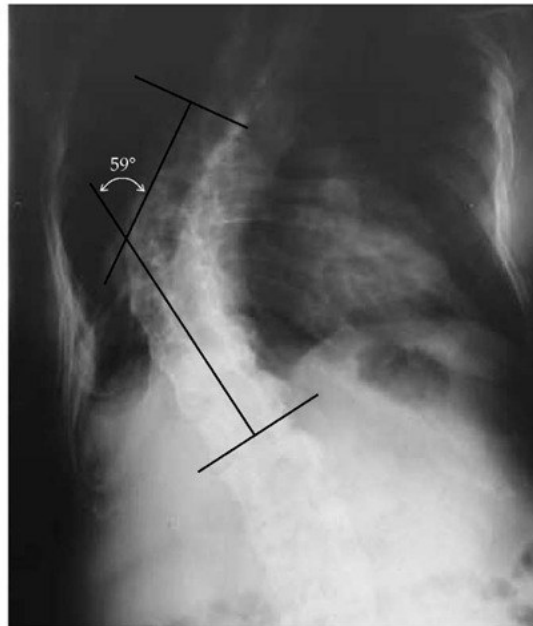
Cobb's angle

- To measure coronal plane deformity on antero-posterior plane radiographs in the classification of scoliosis
- Determining severity of disease



Measurement of the curve in scoliosis using Cobb's angle.

- Identify the upper and lower end vertebrae
- Draw lines extending along the vertebral borders.
- Measure the cobb angle(5)



Cobb' s angle

- $< 10^\circ$: normal curvature
- $> 25^\circ$: ECHO evidence of increased pulmonary artery pressure
- $> 40^\circ$: surgical intervention required
- $> 65^\circ$: restrictive lung disease
- $> 100^\circ$: dyspnoea on exertion
- $> 120^\circ$: alveolar hypoventilation



Scoliosis severity increases with:-

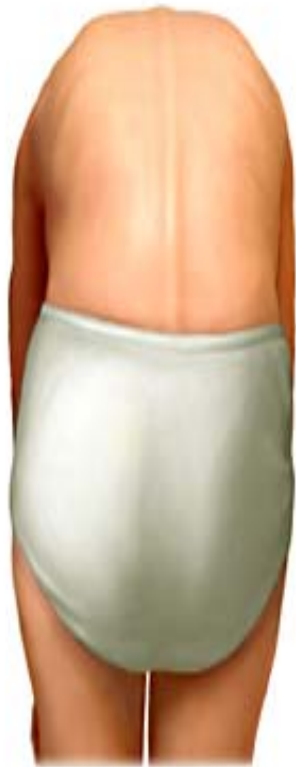- Greater number of vertebrae involved
- More cephalad location of curve
- Loss of normal thoracic kyphosis
- Neuromuscular types

Adams forward bend test

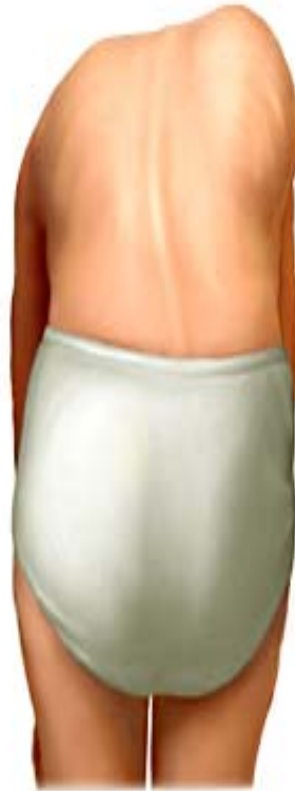- Stand erect with feet together & knees fully extended & palms touching each other
- Bending forward until back is horizontal
- Asymmetry of thoracic or lumbar spine may be detected with Scoliometer
- Measure Angle of Trunk Rotation(ATR) at thoracic , thoraco lumbar & lumbar areas of spine

Adams forward bend test

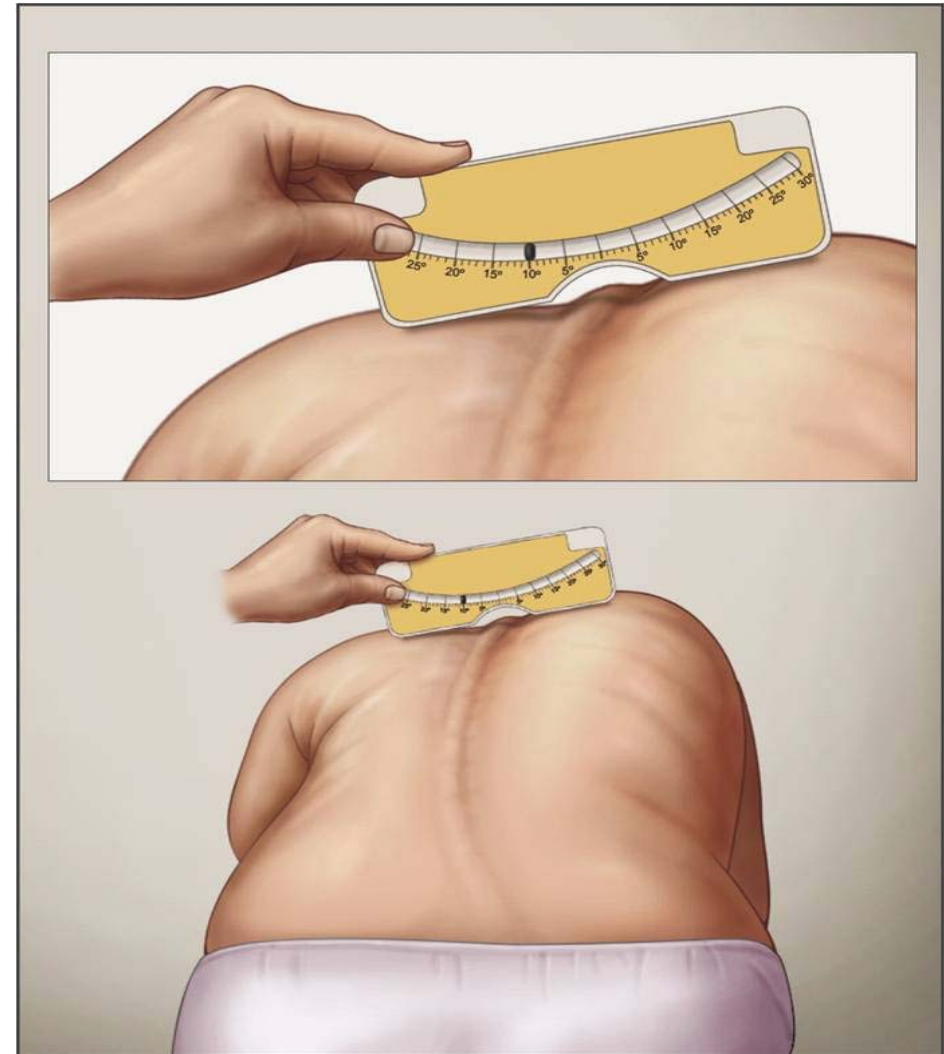
Normal spine



Deformity from scoliosis



ADAM.





Effects of kyphoscoliosis on various organ systems

Respiratory system

Abnormalities in PFTs-

- Restrictive pattern is seen- $\downarrow\downarrow$ vital capacity (60-80% of predicted)
 - \downarrow TLC, \downarrow FRC, \downarrow IC, \downarrow ERV.
 - FEV1/FVC remains normal*
-
- During exercise the ventilation is adequate but there is \downarrow TV and \uparrow RR the maximum work capacity decreases.

Cause of abnormal PFT

- Due to abnormal thoracic cage geometry leading to marked decrease in chest wall compliance

* the lungs and respiratory muscles are normal except in congenital and infantile type where the growth of the lungs may be impaired.




Blood gas abnormality in scoliosis

- Arterial O₂ desaturation
- pCO₂ and pH are normal
- Arterial hypoxemia is mainly because of ventilation perfusion mismatch.
- ↓ diffusing capacity and alveolar hypoventilation may contribute.
- Severe long standing scoliosis is a/w marked V/Q mismatch, alveolar hypoventilation and CO₂ retention. If not surgically treated may lead to respiratory failure.

Cardiovascular system

- May be associated with ↑pulmonary vascular resistance and pulmonary hypertension.
- May result in RVH and Right ventricular failure.
- **Cause-** hypoxemia → pulmonary vasoconstriction → ↑PVR → ↑PA pressure.
- Chronic hypoxemia → PAH.
- A/w with mitral valve prolapse. Antibiotic prophylaxis before catheterization & laryngoscopy

- 
- **Cardiomyopathy- Duchenne's muscular dystrophy**
 - **Mitral/ aortic insufficiency- Marfan's syndrome**
 - **Congenital heart disease is common.**

Treatment

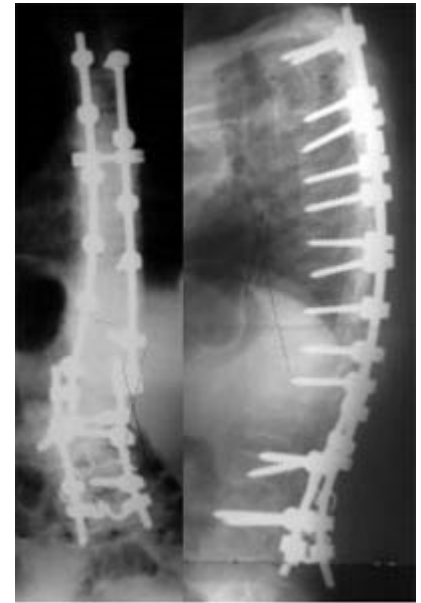
- Surgical intervention occurs when the curve magnitude estimated by the Cobb method is more than 40 degrees
- Fuse vertebrae in a more normal curve
- Severe curves : leading to cardio-respiratory compromise

Surgical procedure

- Aim : to achieve spinal fusion in corrected position
 - Decortication & maintaining correction till bony fusion with the help of instrumentation
- Erector spinae, spinous process, intraspinal ligament, facet joint removed
- Vertebrae decorticated & bone graft placed

Surgical options

- Posterior correction & instrumentation
- Anterior correction & instrumentation
- Anterior release/fusion & posterior instrumentation
- Posterior release/fusion & anterior instrumentation
- Combined anterior & posterior instrumentation & fusion



Preoperative evaluation

i. **Nature of spinal curve**

- Location of curve-thoracic scoliosis is a/w \uparrow PFT abnormality and cervical scoliosis with difficult airway.
- Age of onset-early onset scoliosis may be a/w \downarrow alveolar number and impaired gas exchange.
- Severity- $>60^{\circ}$ related to decrease pulmonary function and $>100^{\circ}$ to impaired gas exchange.
- Etiology-may be a/w other diseases.

History


- H/O SOB, DOE and effort tolerance to assess the cardiopulmonary reserve.
- H/O cough or wheeze to see association with any parenchymal lung disease.
- Pt of marfan's and neurofibromatosis may have symptoms of palpitations and syncope because of underlying cardiac conditions.

Physical examination

- Auscultation of lungs for any wheeze (obstructive or parenchymal lung disease)
- Heart-signs of PAH(loud P2)and signs of RVH(engorged veins, hepatomegaly, edema)
- Skin-café au lait spots in NF
- Airway assessment-to see for cervical scoliosis, high arched palate(Marfan's), neurofibroma.
- Neurological assessment-pt with pre existing neurological deficit are at ↑risk of spinal cord injury during surg. Also documentation of pre op neurological status is imp.

Investigations

- Haemogram
 - O₂ carrying capacity
 - Guide to transfusion
- SERFT, LFT
- Coagulation studies
 - PT, PTI, platelet count
- Chest radiograph
- Electrocardiogram
- Echocardiogram

- 
- Pulmonary function tests
 - ABG
 - Spirometry
 - FVC
 - FEV₁/FVC
 - PEFr
 - Peak inspiratory pressure
 - Peak expiratory pressure
 - Exercise capacity
 - Vital capacity < 40% normal
 - Req of postoperative ventilation
 - ABG : Hypoxemia
 - V/Q abn. > alveolar hypoventilation
 - CC > FRC
 - Decreased DLCO



- Cardiac evaluation- ECHO

- Marfan's syndrome
- Ehlers Danlos syndrome
- Duchenne's muscular dystrophy
- Friedreich's ataxia

Anaesthetic technique

- Depends on whether wake up test is to be used
- Induction : thiopentone/ propofol
- Maintenance: high dose fentanyl + propofol infusion+ very low/ no isoflurane
- Suxamethonium : avoid in muscle disorders
- P/O pain relief : spinal, epidural, caudal

Monitoring & lines

- Two wide bore iv lines
- Standard ASA monitoring : ECG, NIBP, SpO₂, vapour pressure, EtCO₂, Airway pressures
- Invasive blood pressure, CVP monitoring
- Urine output, temperature
- Warm fluids, warm blanket
- Eye care, pressure points & positioning
- Esophageal stethoscope

Intraoperative concerns

- Blood loss & replacement
- Hypothermia
- Prone position complications
- Lung isolation
- Spinal cord monitoring (Wake up test & evoked potentials)
- Venous air embolism

Blood loss & replacement

- Usually associated with large blood losses
 - 15 to 20 ml/kg
- Factors
 - surgical technique
 - operative time
 - number of vertebral levels fused
 - Anaesthetics
 - mean arterial blood pressure
 - platelet abnormalities
 - dilutional coagulopathy
 - primary fibrinolysis

Blood loss

- Techniques to reduce loss
 - Avoid light anaesthesia, hypertension, hyperdynamic circulation, hypercapnia
 - Surgical hemostasis & vasoconstrictor use
 - Proper positioning – avoid raised intra abdominal pressure
 - Deliberate controlled hypotensive anaesthesia
 - Pharmacological agents

Deliberate controlled hypotensive anaesthesia

- Young healthy patient - mean arterial pressure of 50 to 60 mm Hg
- Adult patient with cardiovascular disease : higher pressures
- Pre requisites : invasive BP & urine output, ABG
- Techniques:
 - high dose inhalational agent
 - vasodilators: Na nitroprusside, nitroglycerine
 - Ganglionic blocking agents-trimethaphan
 - B adrenergic blockers: esmolol, labetalol
 - ACE I: captopril
 - α_2 agonist: dexmedetomidine

*concern- \downarrow SC blood flow \rightarrow \uparrow chance of SC injury

Pharmacological agents

- Aprotinin
 - Reduces blood loss in spine surgeries
 - Inhibits plasmin & kallikrein and preserves platelet function.
 - 1-2 million KIU bolus - 0.25-0.5 million KIU/hr
- Desmopressin
- Tranexamic acid 10mg/kg → infusion @ 1mg/kg/hr

Preoperative autologous blood donation

- Hb > 11g%, HCT > 33%
- No age / weight limits
- Donate 10-15% of blood volume
- 2 donations (1/week)
- Last donation no less than 72 hours before surgery
- Started 1 month before
- Oral Fe / Erythropoietin supplementation

Acute normovolemic hemodilution

- Removal of whole blood shortly before anticipated significant blood loss
- Collected in standard blood bags with anticoagulation
- Simultaneous infusion of crystalloid(3:1) or colloid(1:1)
- Stored at room temperature
- Re infused during surgery after major blood loss has occurred
- Re infused in reverse order of collection



Blood salvage

- Blood lost during surgery is collected using commercially available equipment and is then anticoagulated, filtered for clots and debris, centrifuged, resuspended in saline and reinfused to the patient.
- Clotting factors need to be replaced using fresh frozen plasma.
- The technique is unsuitable in the presence of malignancy or infection.

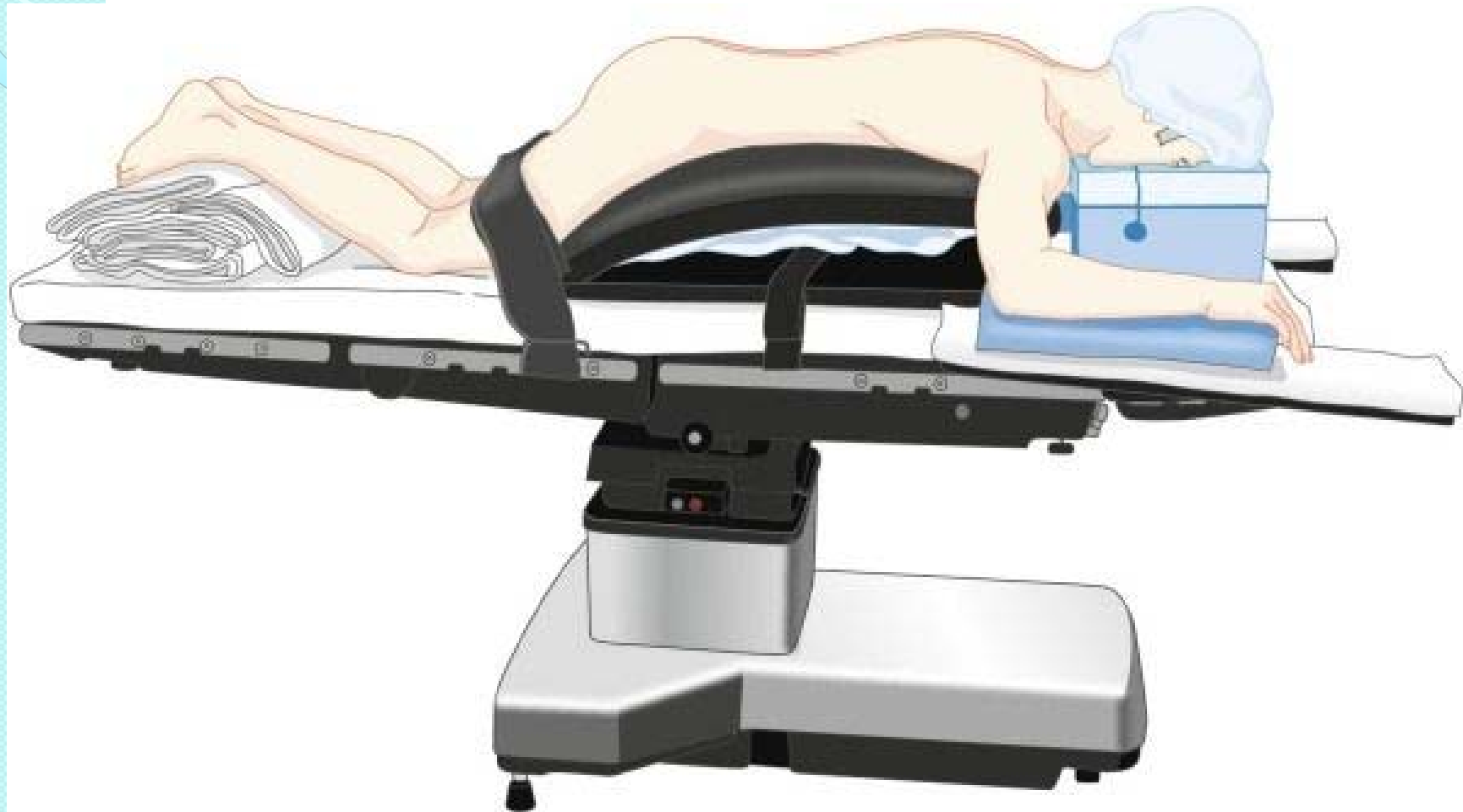



Hypothermia

- Long duration of surgery
- Transfusion of blood & blood products
- Hazards
 - Impaired coagulation
 - Wound infection
 - Delayed recovery
 - Acid/base changes
- Prevention
 - Monitoring , warm fluids, warming blankets, warm irrigation solutions

Prone position & concerns





Prone position & concerns

- Arms are abducted less than 90 degrees whenever possible(prone “superman” position)
- Pressure points are padded
- Soft head pillow has cut outs for eyes and nose and a slot to permit endotracheal tube exit
- Chest and abdomen are supported away from the bed
 - minimize abdominal pressure and preserve pulmonary compliance
- Eyes checked frequently
- Elastic stockings and active compression devices > lower extremities >minimize pooling of the blood


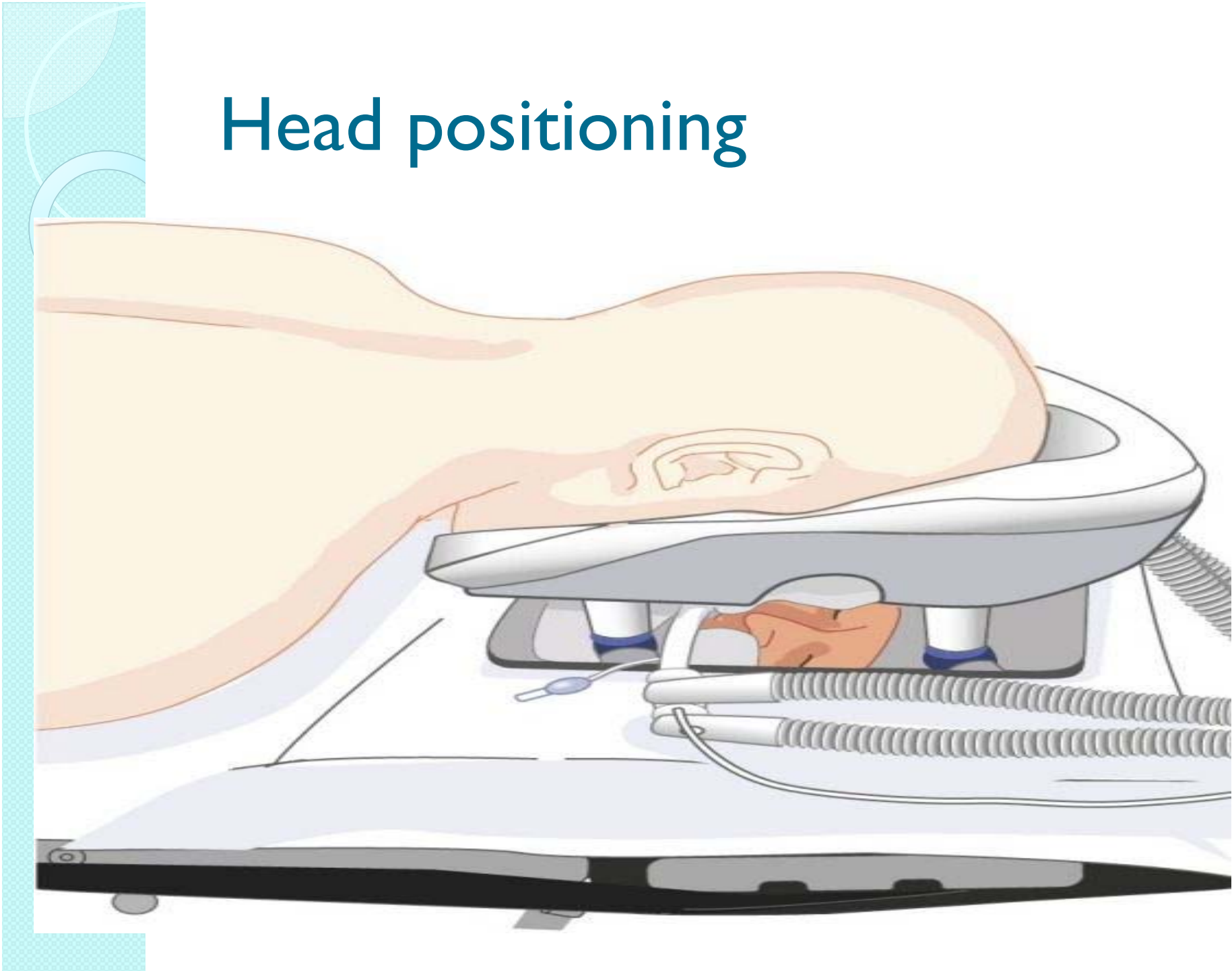


Figure
A: De
arms



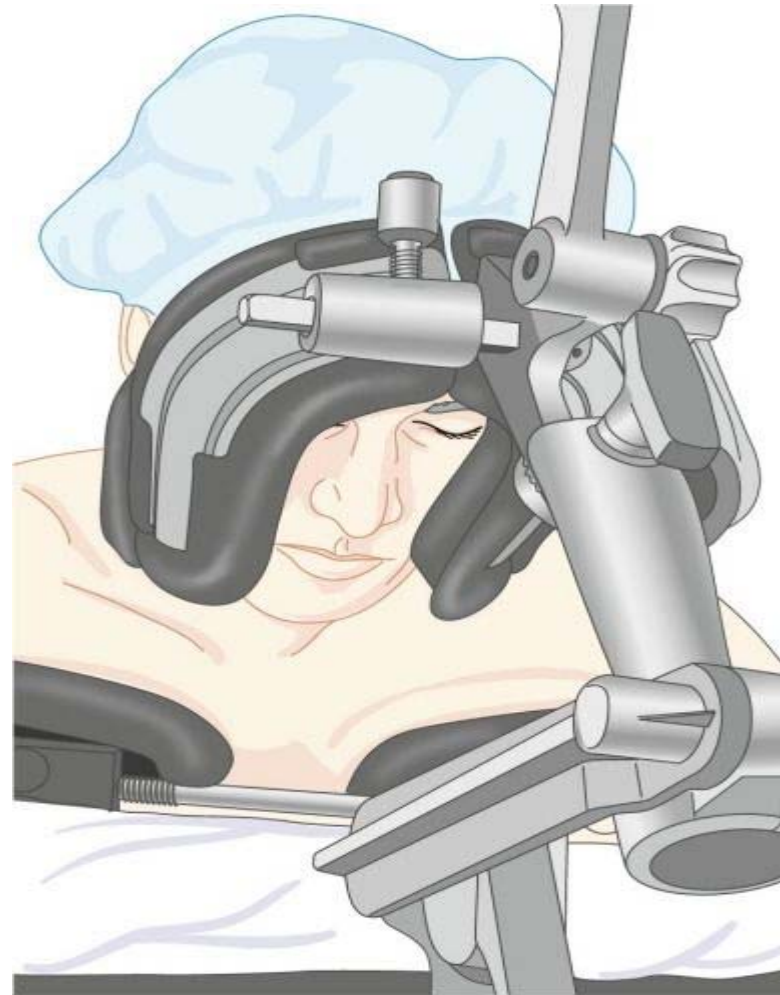Figure
surge
the th
comp

Head positioning



Prone position

- Horseshoe shaped adapter
- Superior access to airway & visualization of eyes



Spinal cord monitoring

- Postoperative neurologic deficit is one of the most feared complications
- Varies with type of instrumentation
 - Harrington rod - 0.23%
 - Luge correction - 1%
 - Cotrel dubouset) - 0.6%
- Increased risk in non idiopathic scoliosis
- Severe rigid deformity > 120°
- Congenital scoliosis
 - Lipomas, tethered cord, cysts, teratomas

Causes of neurological injury

- Direct injury due to instruments
- Spinal cord distraction
- Hypotension
- Ischemic (loss of blood supply)



Spinal cord monitoring

- Wake up test
 - Gold standard
- Somatosensory evoked potentials(SSEPs)
 - Evaluate posterior/sensory portion of the cord
- Motor evoked potentials(MEPs) & electromyograms
 - Integrity of anterior motor spinal cord

Wake up test

- Explaining procedure prior to surgery
- Repeat/enact before induction
- Switch off inhalation & MR
- Maintain on opioid
- First asked to grip hand, then move leg
- Preparation to restrain any unwanted movement

Wake up test

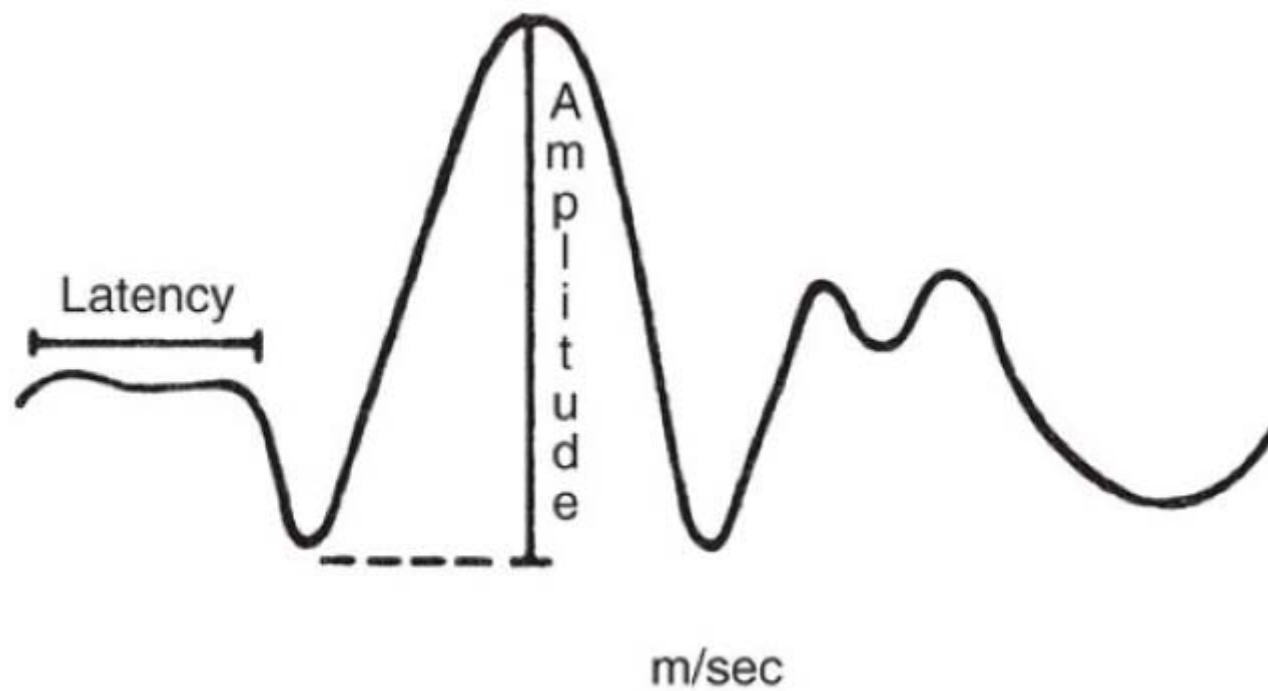
- Hazards & disadvantages
 - Results influenced by anaesthetics and the cognitive integrity of the patient
 - inadvertent extubation of the patient during movement in the prone position
 - air embolism during a deep inspiration
 - dislodgment of the instrumentation during violent movements
 - Injury



SSEP

- Evaluate posterior/sensory portion of the cord
- Stimulation of peripheral nerve
 - Posterior tibial
- Recorded from scalp or cervical/thoracic epidural electrodes
- Increased latency > 10-15% & decreased amplitude > 50 % significant
- Muscle activity disturbance eliminated by NMB
- Affected by hypotension, hypothermia, hypocarbia, hypoxemia, anemia, and anesthetics

Typical SSEP



MEP

- Assess the integrity of the spinal motor pathways (anterior columns)
- Electric or magnetic trans-cranial stimulation
- Epidural , neurogenic or myogenic MEP
- Conduction of these stimuli through the motor pathways is monitored as peripheral nerve impulses, electromyographic signals, or actual limb movements.
- More sensitive to anesthetic interface



Anaesthetic agents & EP

- Opioid have least effect on SSEPs
- Cortical SSEP is very sensitive to Potent inhalational agents , nitrous oxide.
- Sub cortical SSEP is more resistant
- MEPs is affected by
 - nitrous+inhalational
 - BZD, thiopentone
- MR have no effect on SSEPs or MEPs



Postoperative concerns

- Pain management
- Pulmonary function
- Post op ventilation
- Hyponatraemia
- Bleeding & coagulation abnormalities

Pain management (multimodal analgesia)

- Parental opioid (48 hours)
 - continuous infusion/iv PCA
- NSAIDs
 - Opioid sparing effect
 - Reports that ketorolac inhibits spinal fusion
- Epidural infusion
 - Local anaesthetic + opioid infusion
- Intrathecal opioid
 - Morphine 5 – 10 µg/kg

Optimisation of pulmonary status

- Incentive spirometry
- Coughing and deep breathing should be encouraged
- Bronchodilators therapy if reactive airway disease also present
- Adequate analgesia



Predictors of post op ventilation

- Patient factors
 - Severe restrictive lung disease
 - Vital capacity < 35%
 - $P_{i,max} > -40\text{cm H}_2\text{O}$
 - $P_{E,MAX} > + 40\text{cm H}_2\text{O}$
 - $\text{PaO}_2 < 60 \text{ mmHg}$
 - $\text{PaCO}_2 > 50 \text{ mm Hg}$
 - Right ventricular failure
 - Pre existing neuromuscular disease
 - Congenital heart disease
 - Obesity



Predictors of post op ventilation

- Surgical factors
 - Blood loss > 30 ml/kg
 - Surgical invasion to thoracic cavity



summary

- In Kyphoscoliosis there is involvement of various organ systems.
- Anaesthesia is often needed for corrective orthopaedic surgery.
- A detailed preanaesthetic assessment and optimization of the respiratory and cardiovascular systems is important.
- Intraoperative considerations are monitoring, temperature and fluid balance maintenance, positioning, spinal cord integrity monitoring and blood conservation.
- Post operative concerns- intensive care, respiratory care and pain therapy



Thank you
