

# PRINCIPLES OF DIAGNOSIS

- History Taking
- Clinical Examination

# Structure of skin

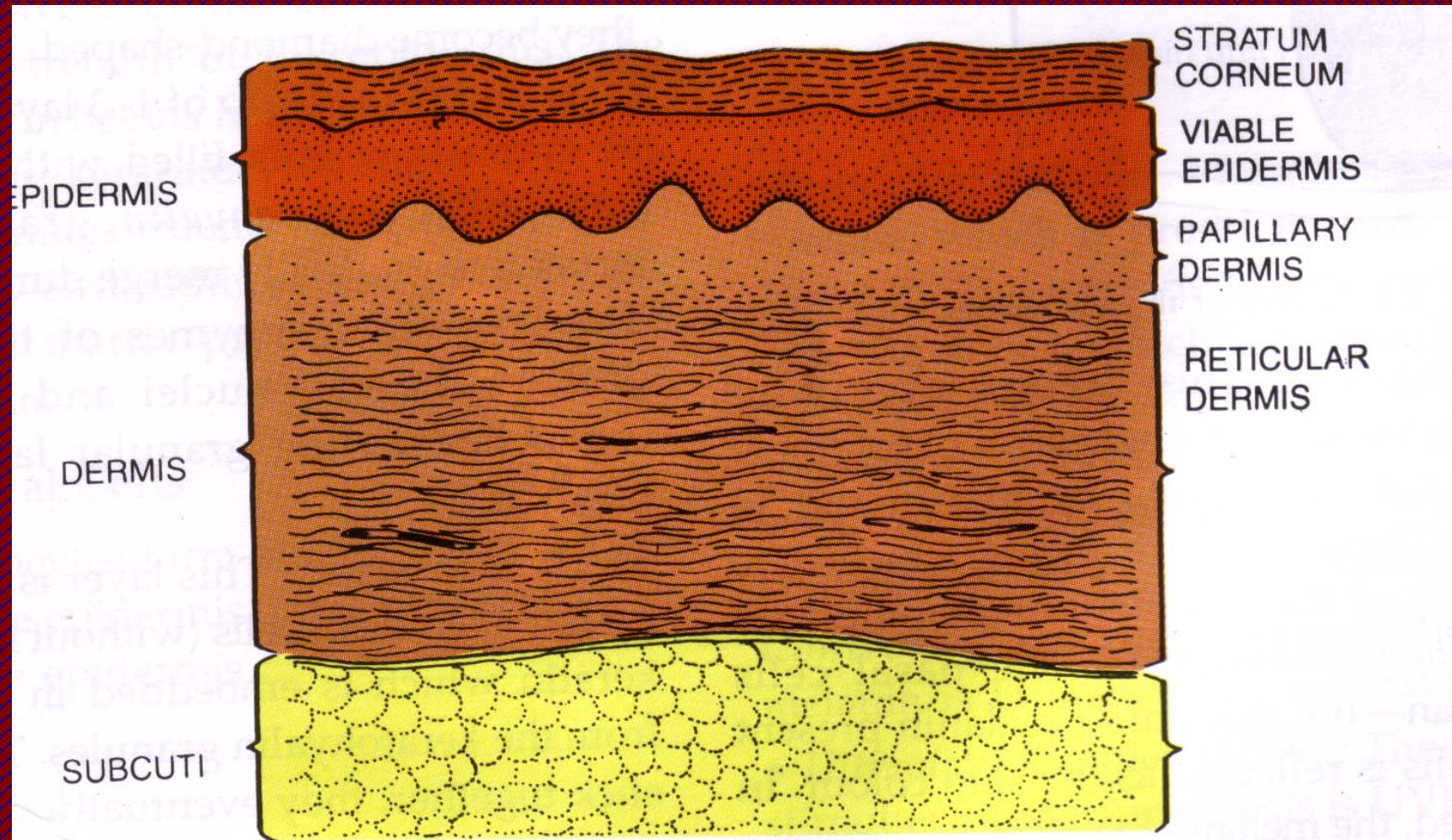


Fig. 2.1. Three layers of the skin.

# Chief Complaints

## Itching /Pruritus

### Generalised

Scabies, Pediculosis

Eczema, urticaria

Internal disease

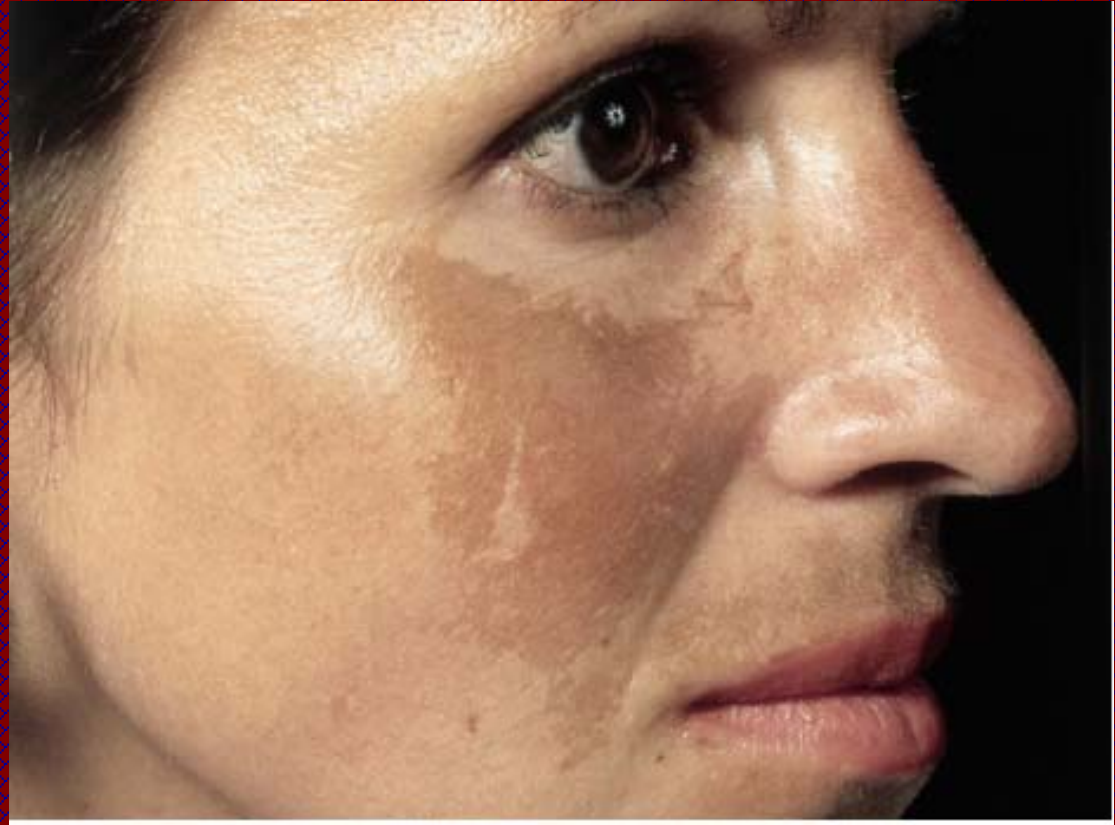### Pruritus

Itching without skin lesions

# Pigmentary changes

Hyperpigmentation

Melasma

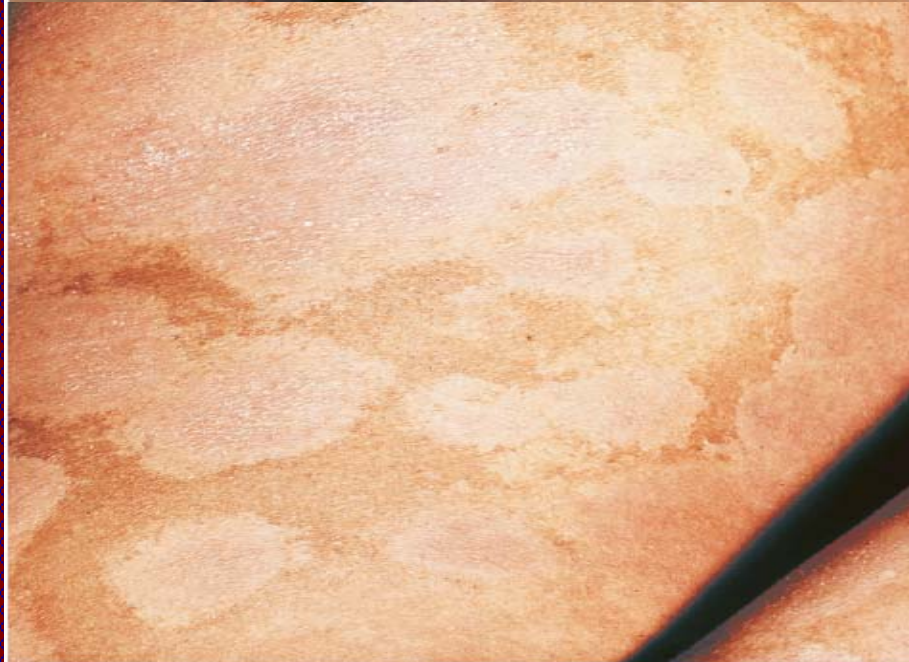
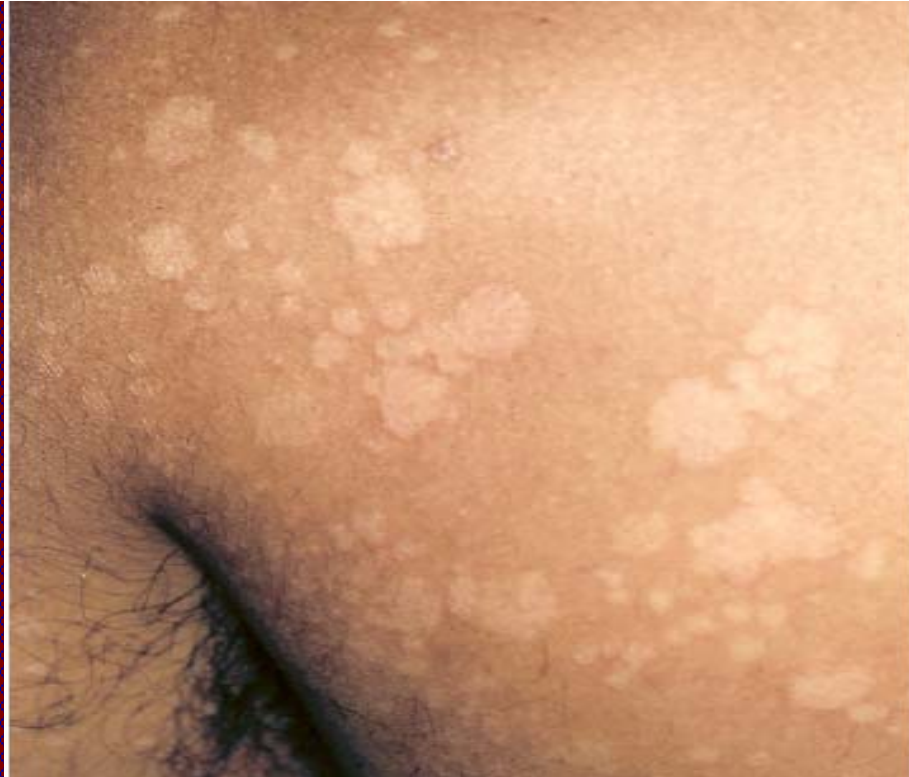

# Pigmentary changes

Hypopigmentation

Leprosy

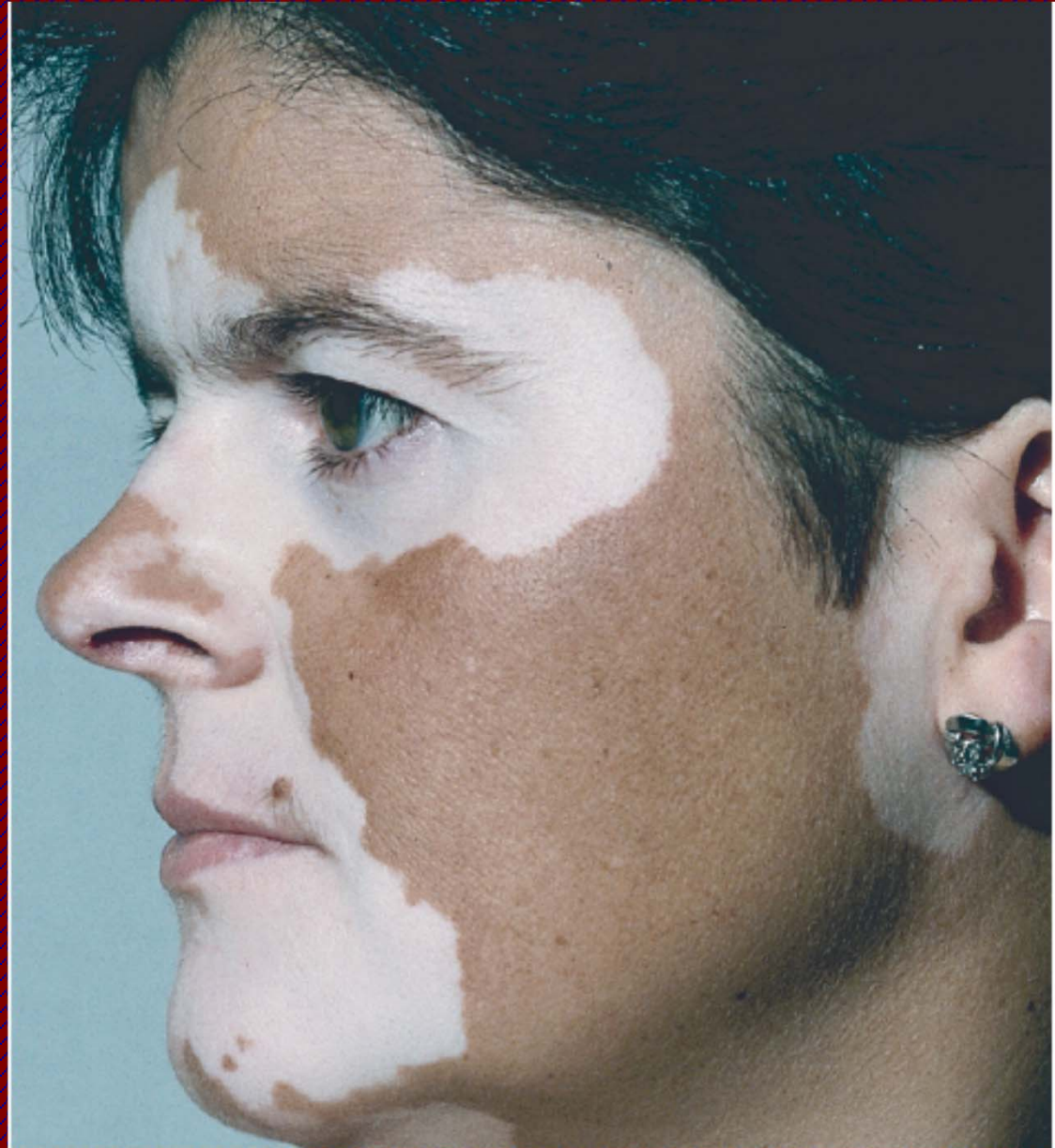*P. versicolor*



# Pigmentary changes

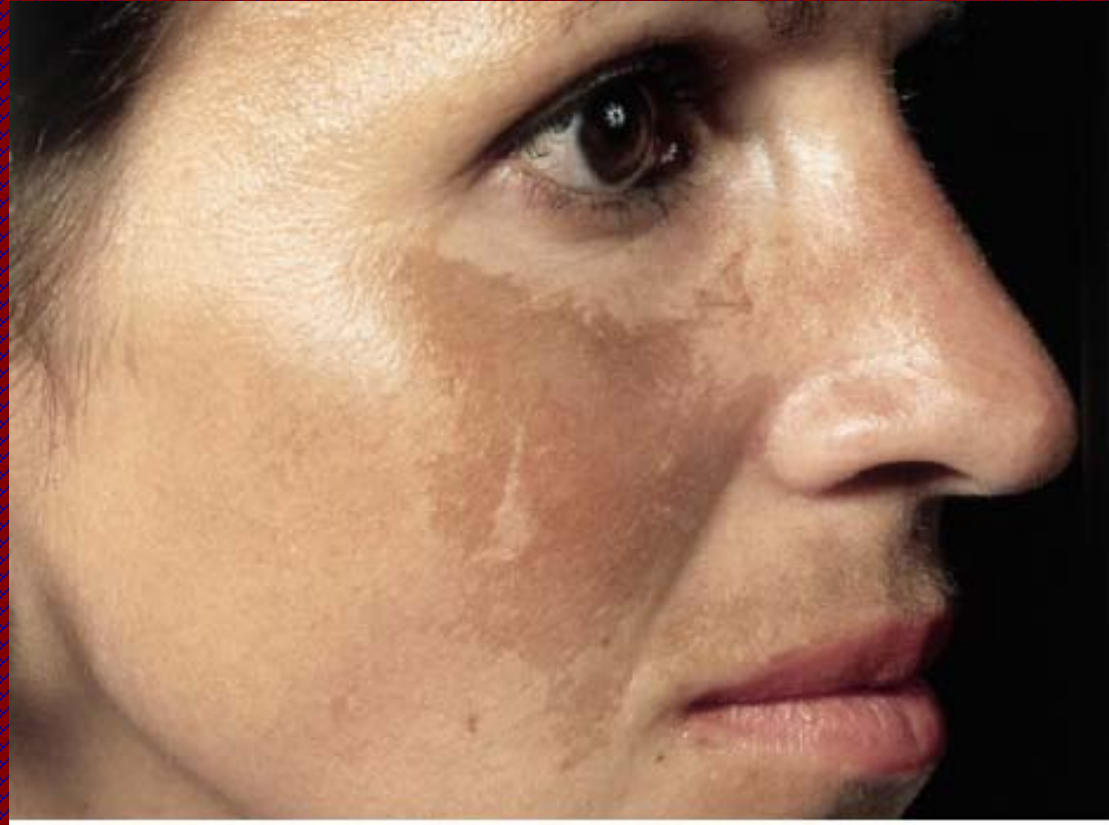Depigmentation

Vitiligo



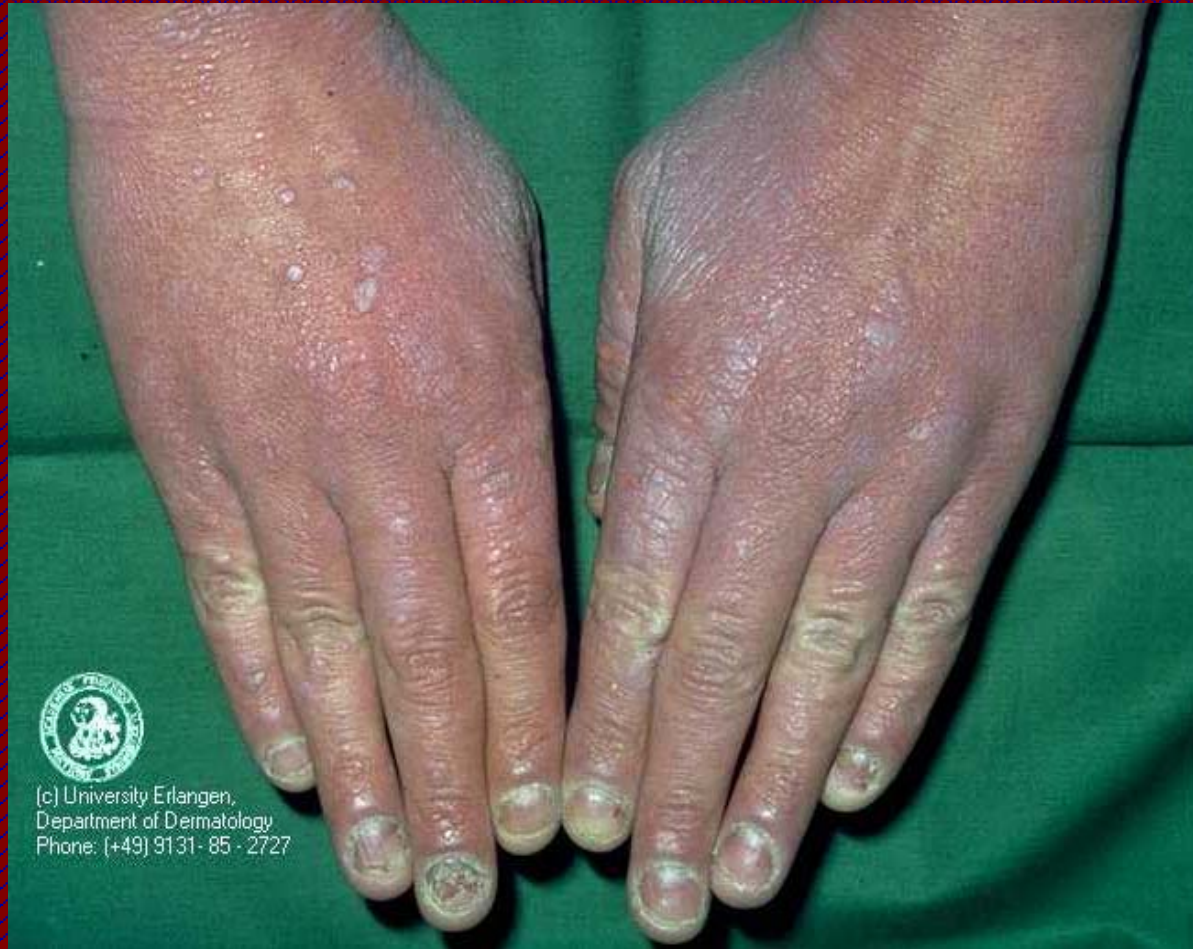# Pigmentary changes

Brownish  
Melasma



# Pigmentary changes

Greyish blue  
- lichen planus



(c) University Erlangen,  
Department of Dermatology  
Phone: (+49) 91 31 - 85 - 2727

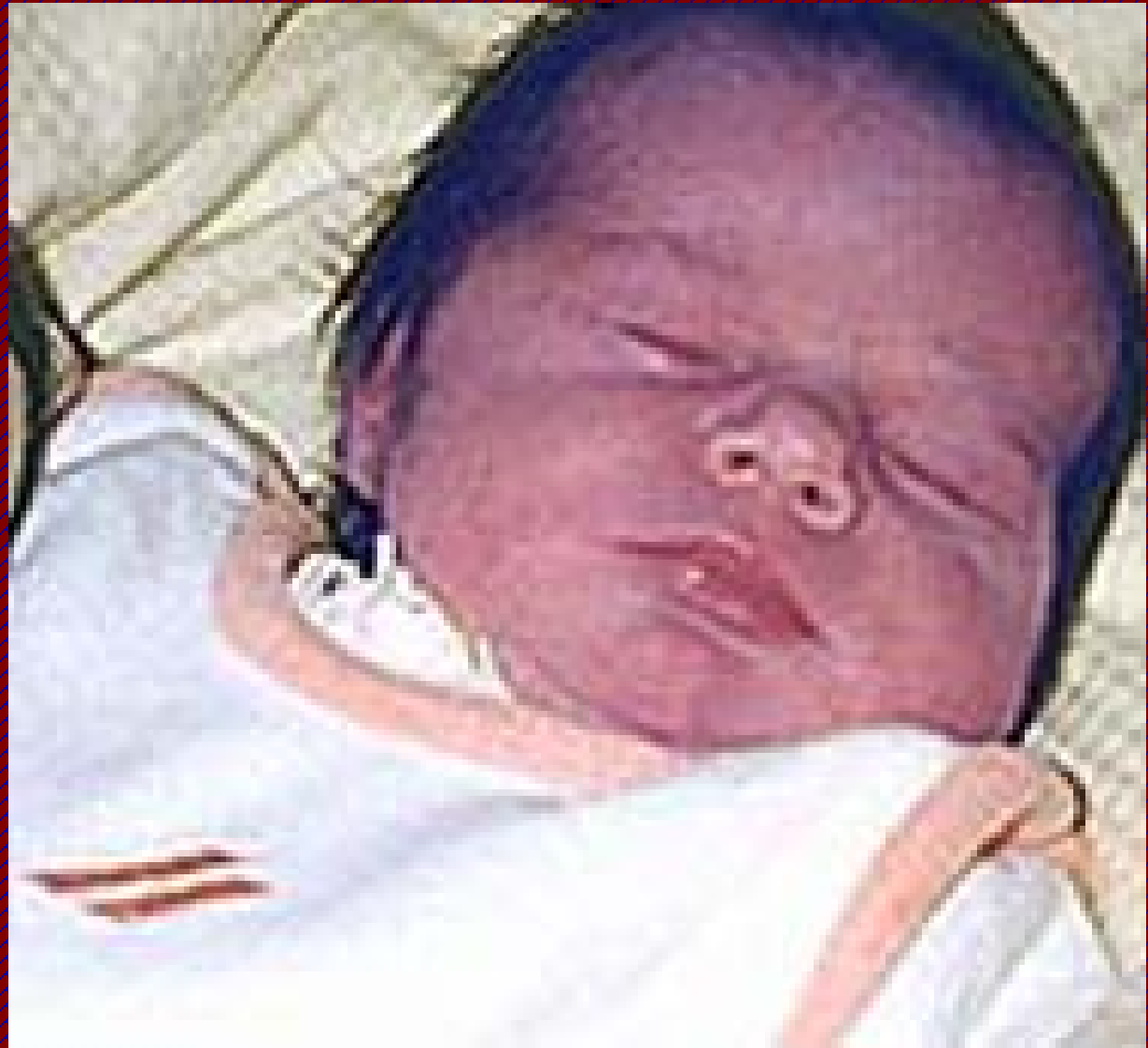

# Pigmentary changes

Dyschromicus perstans

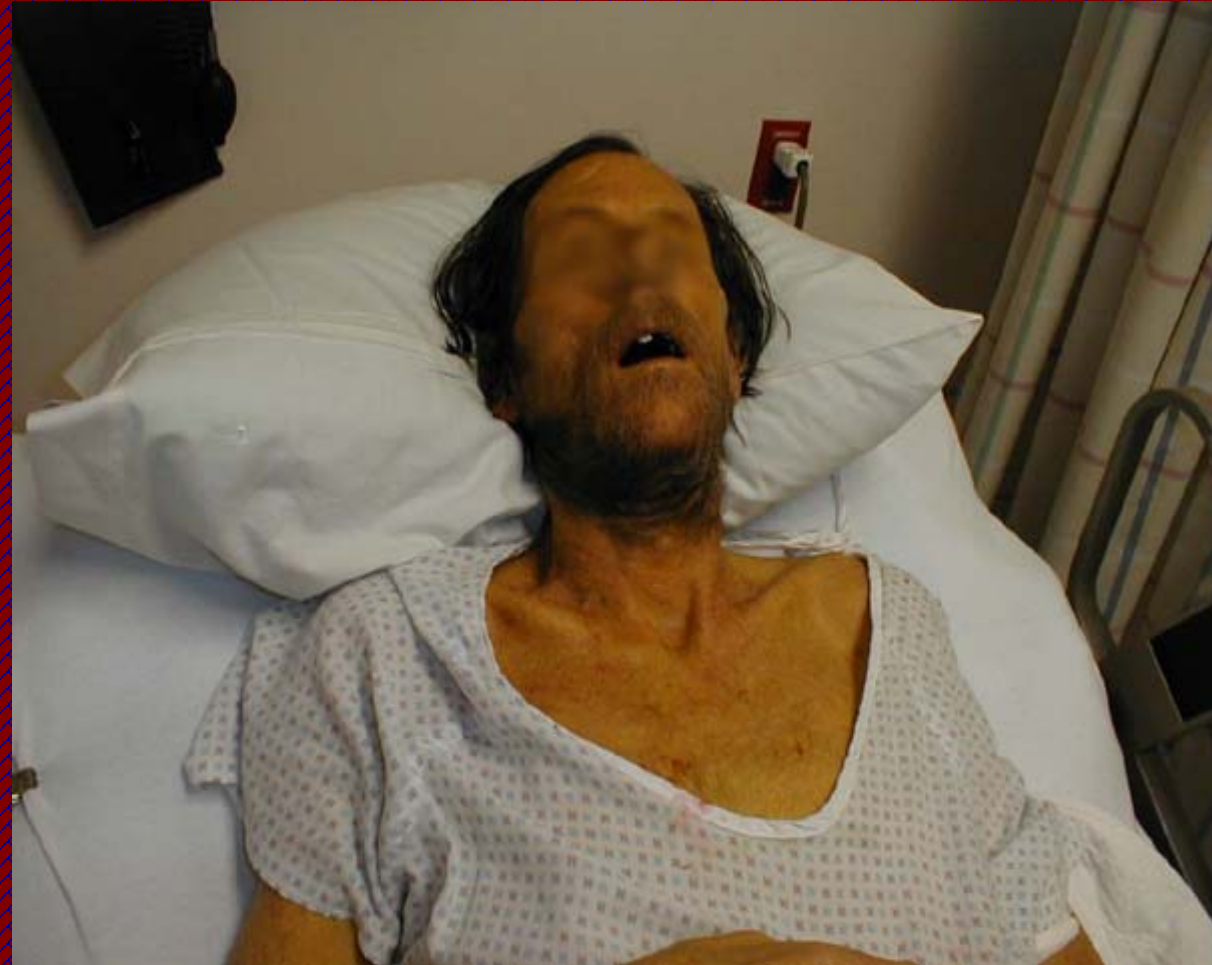**Discoloration**

**Cyanosis**



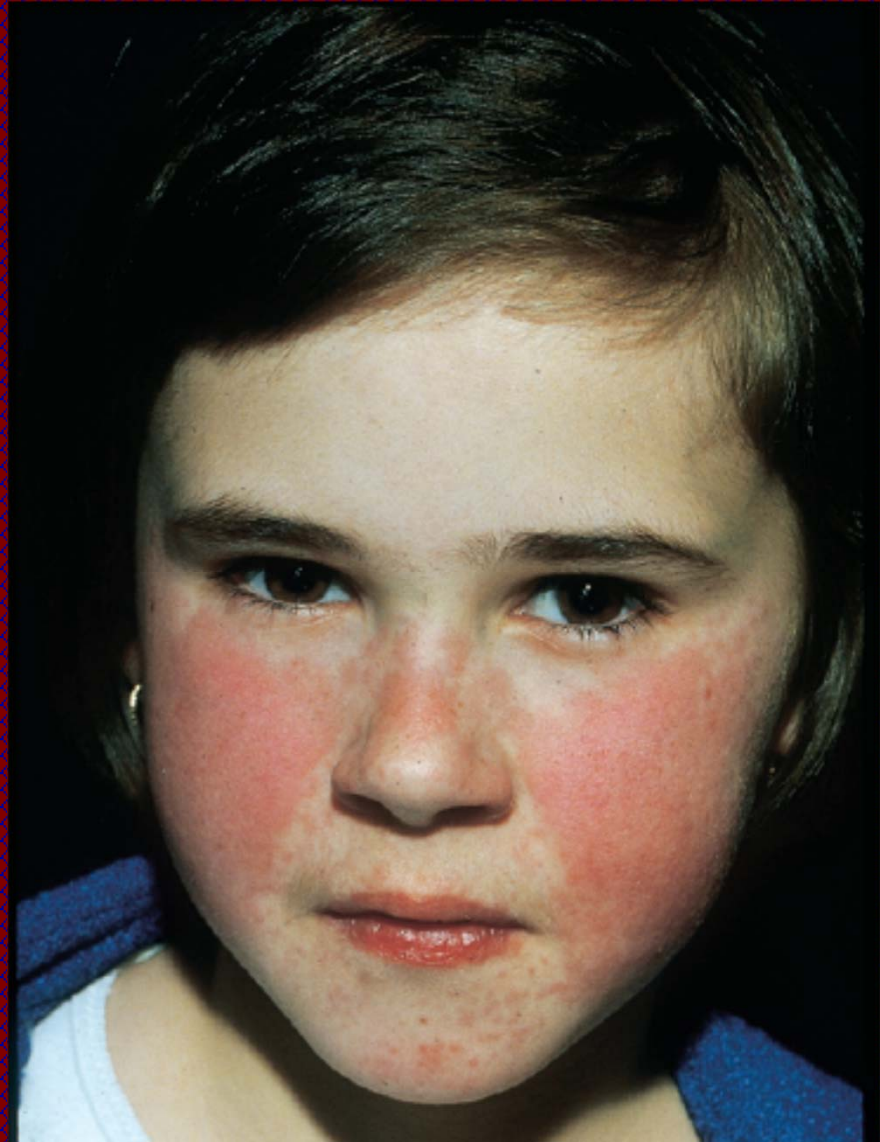# Discoloration

Jaundice



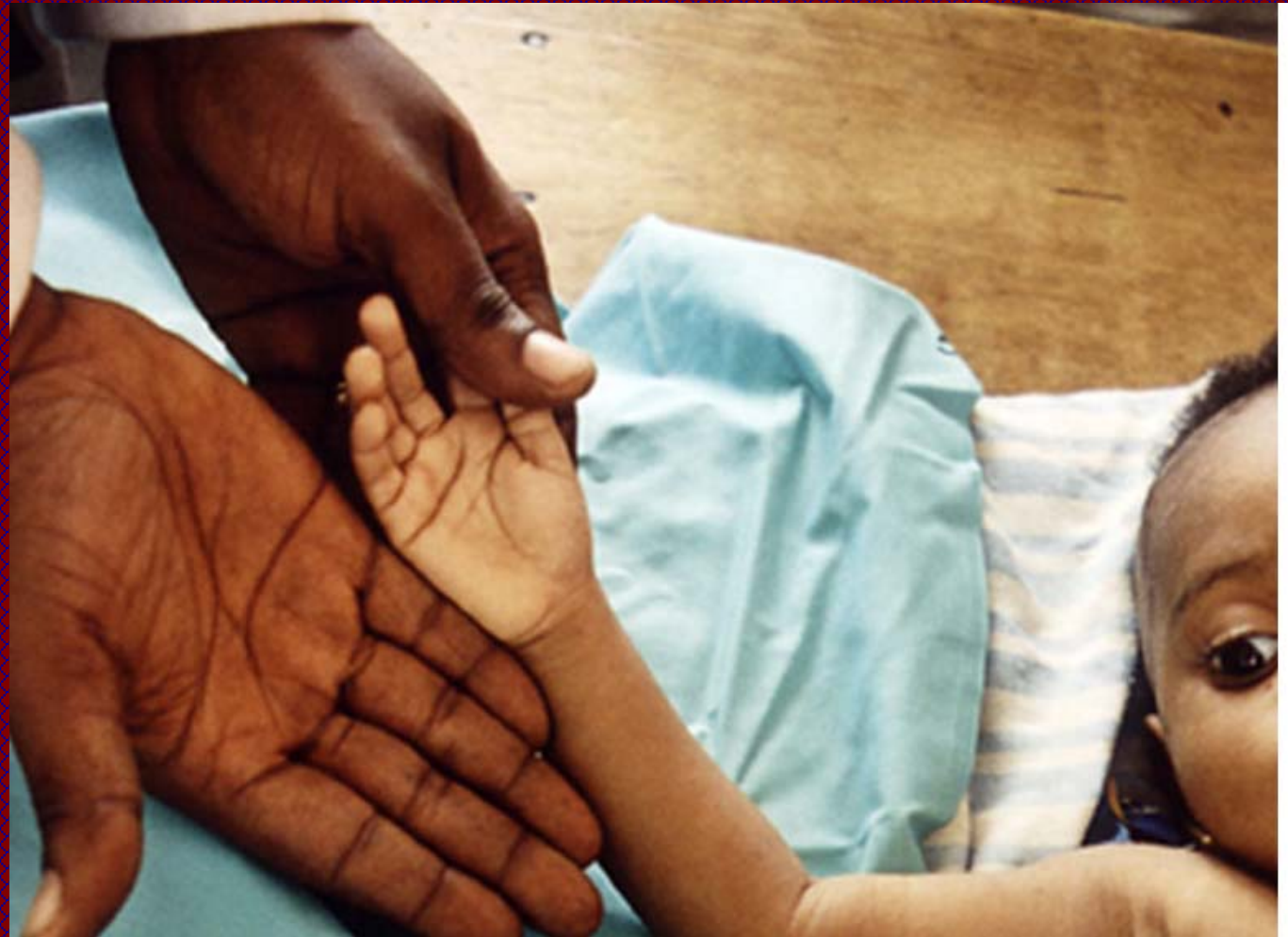# Discoloration

Erythema



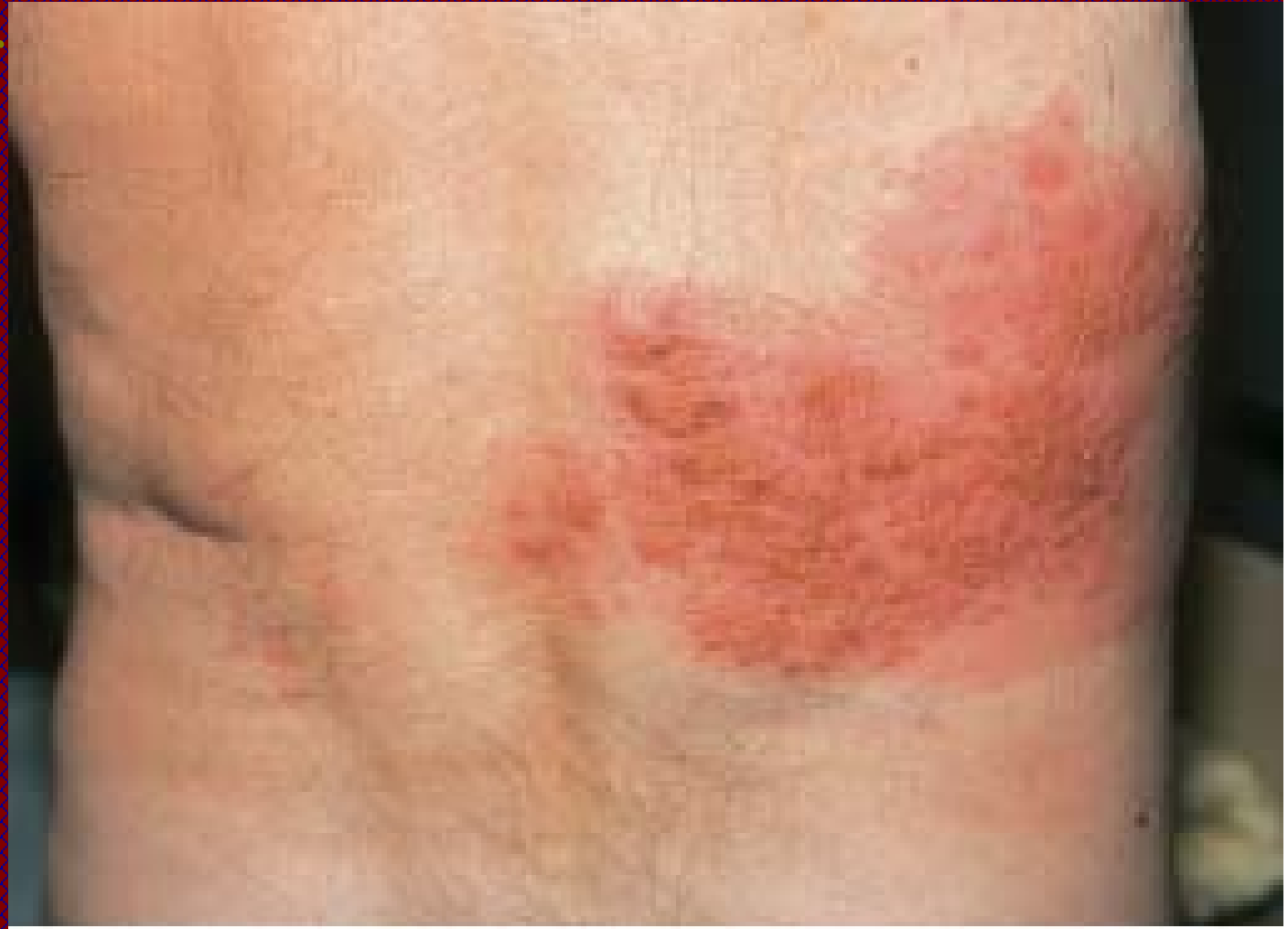# Discoloration

Pallor



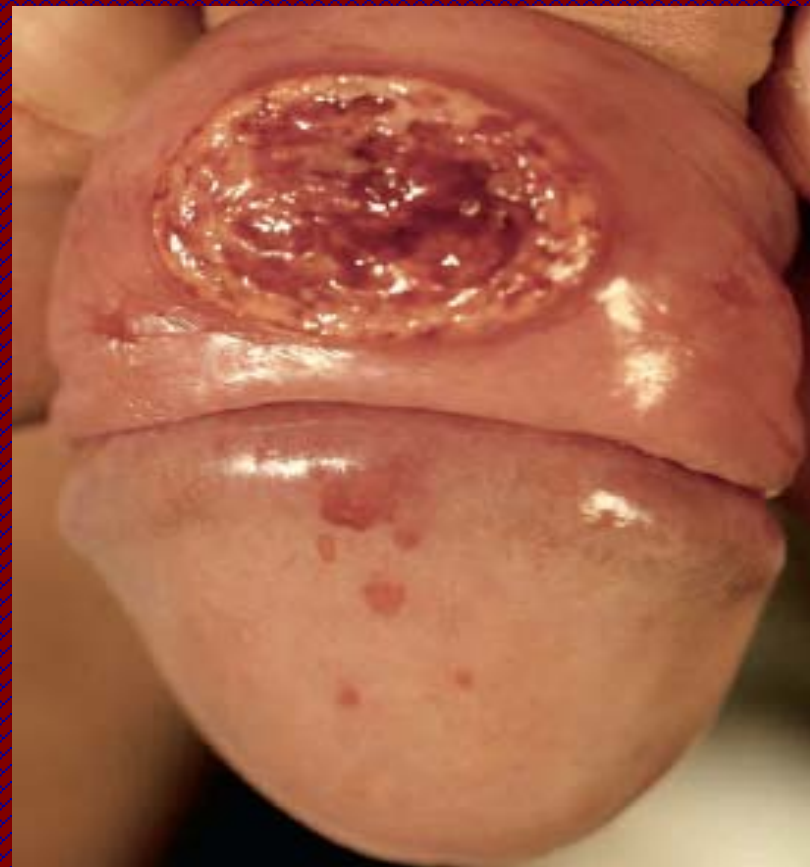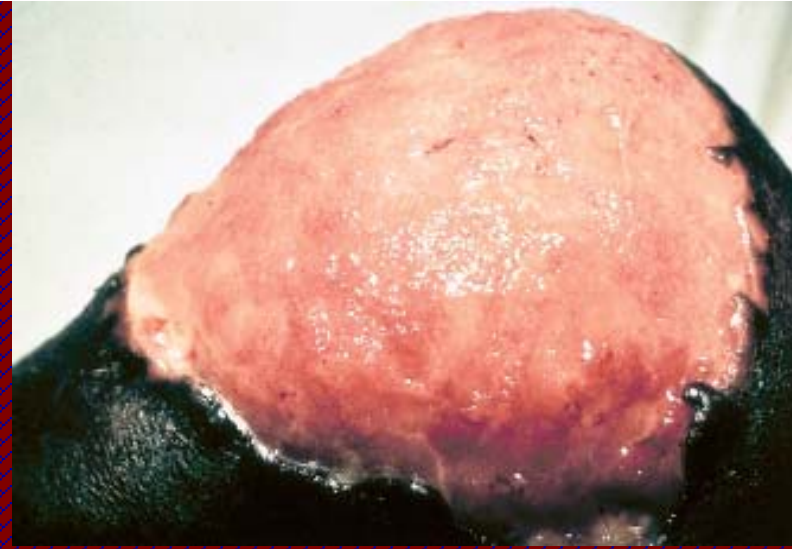# Pain or Discomfort

Herpes Zoster



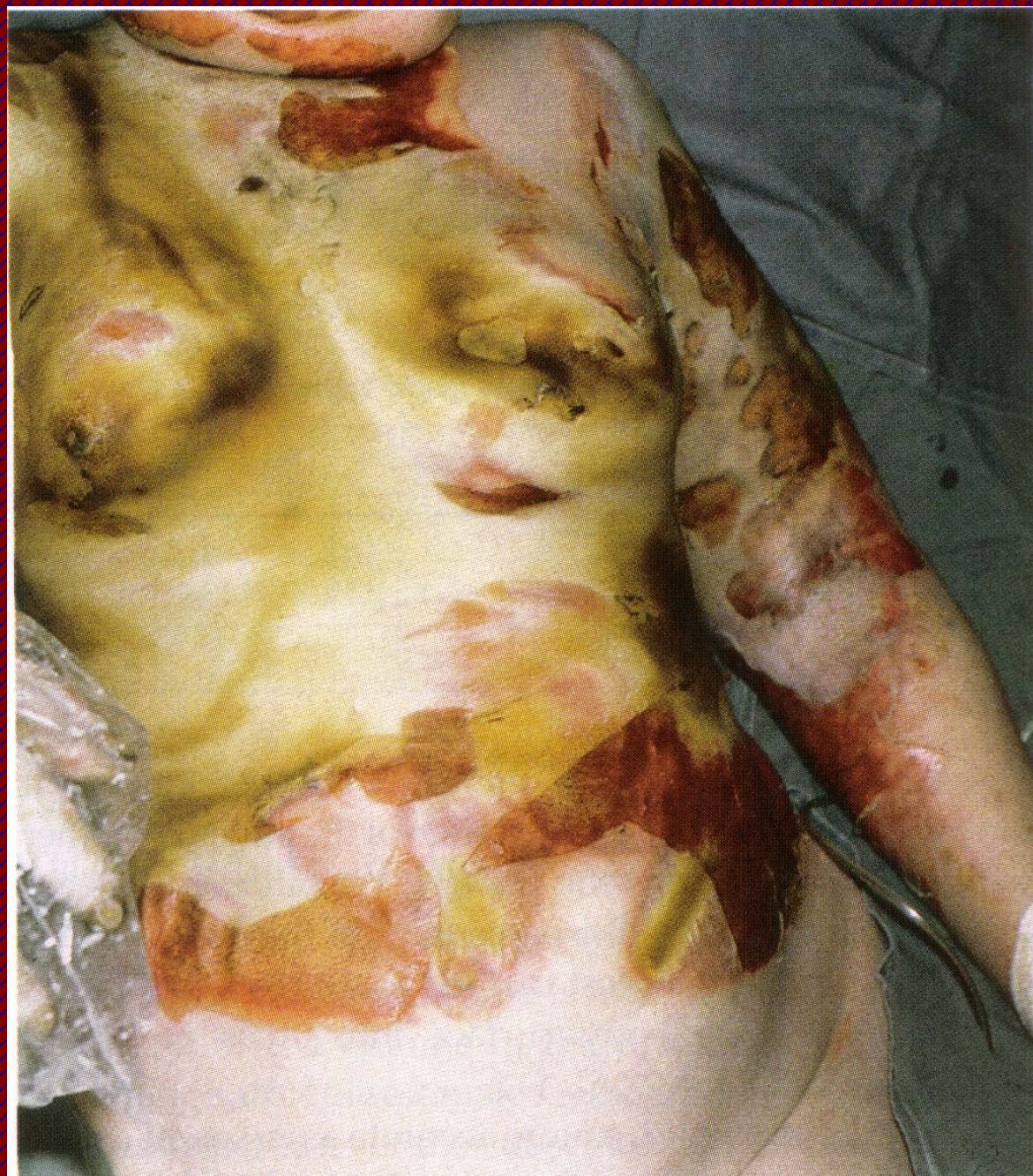
**Pain or  
Discomfort**

Ulcer



**Pain or  
Discomfort**

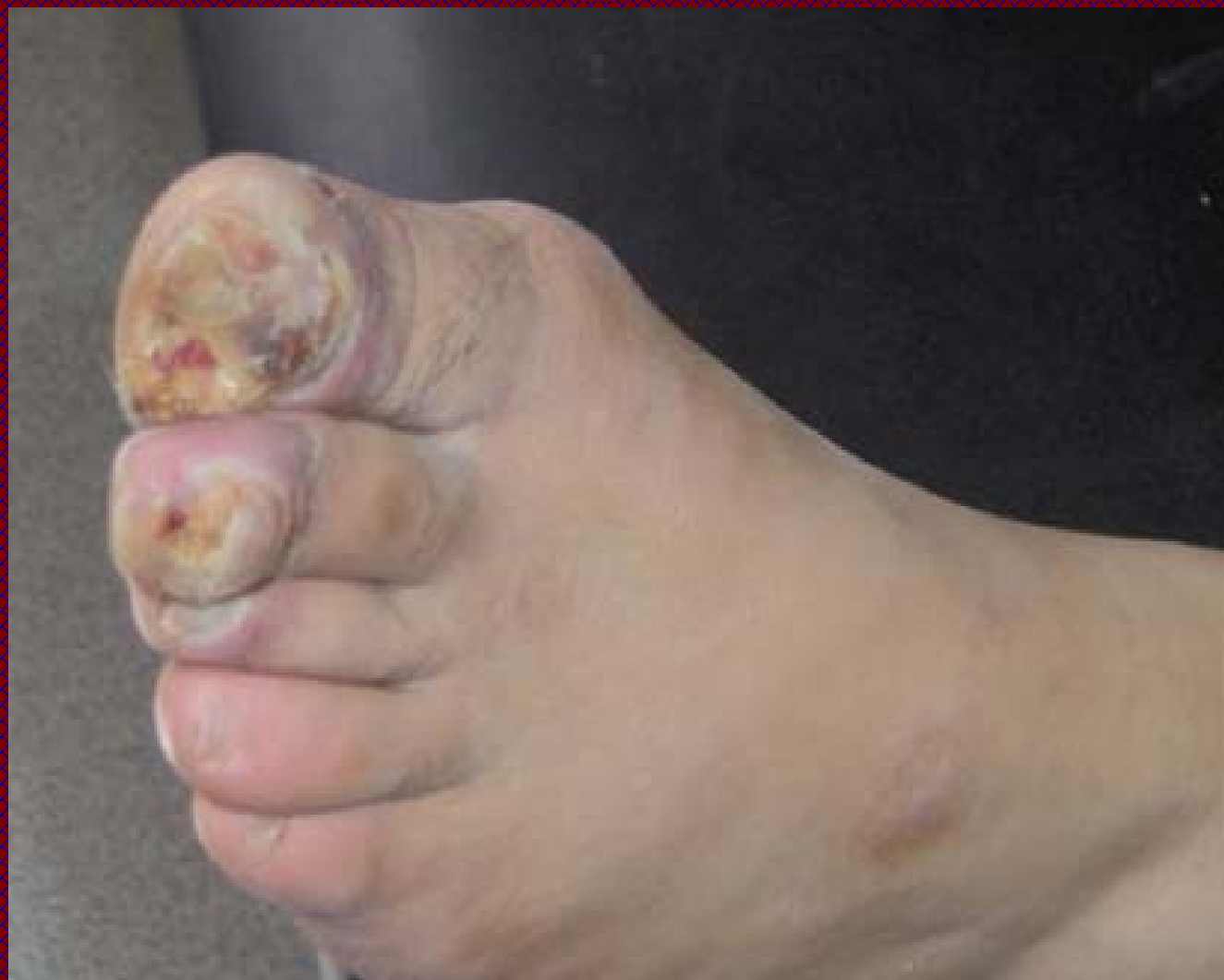Burns





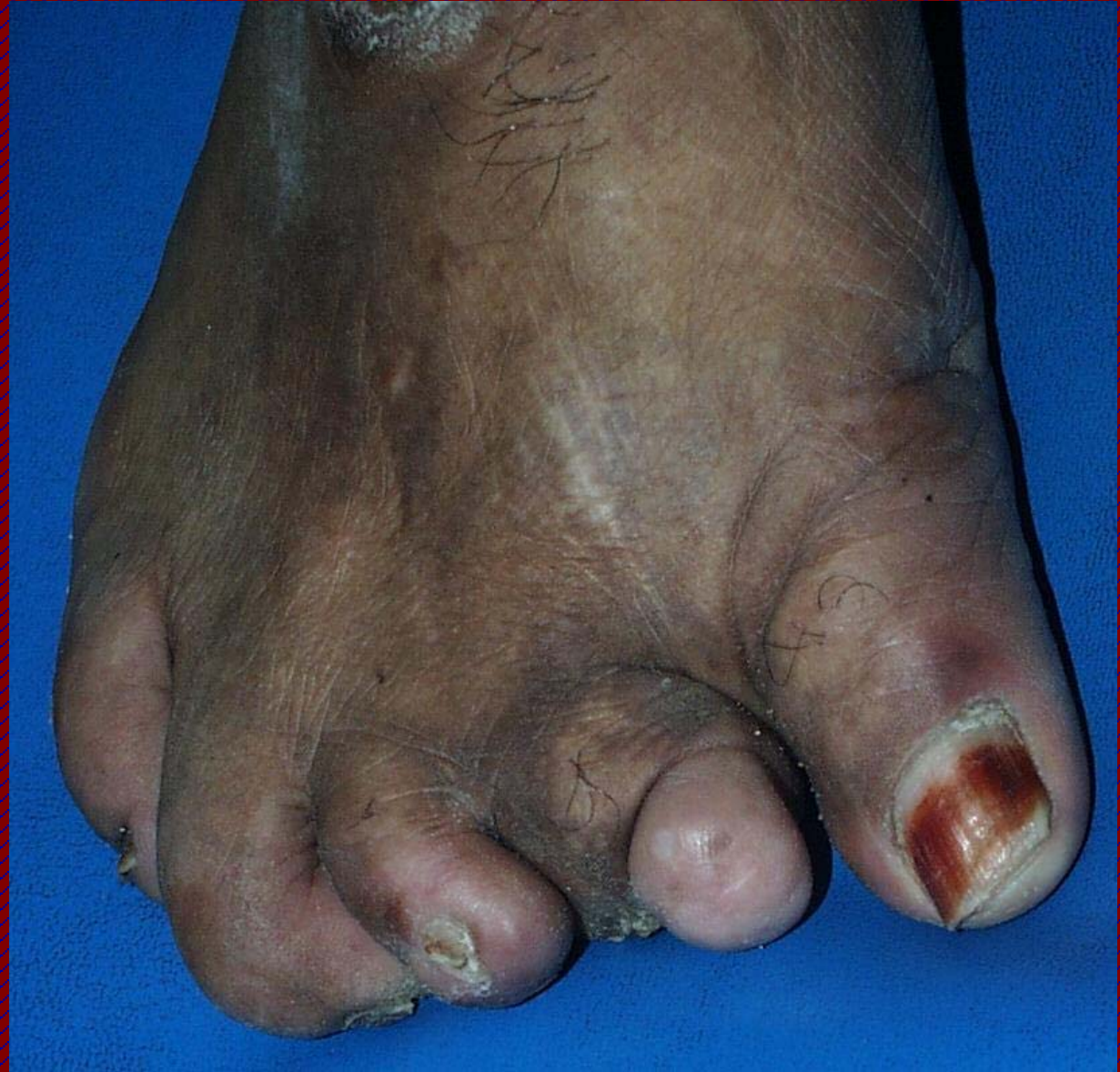# Loss of sensation

Trophic ulcer



# Loss of sensation

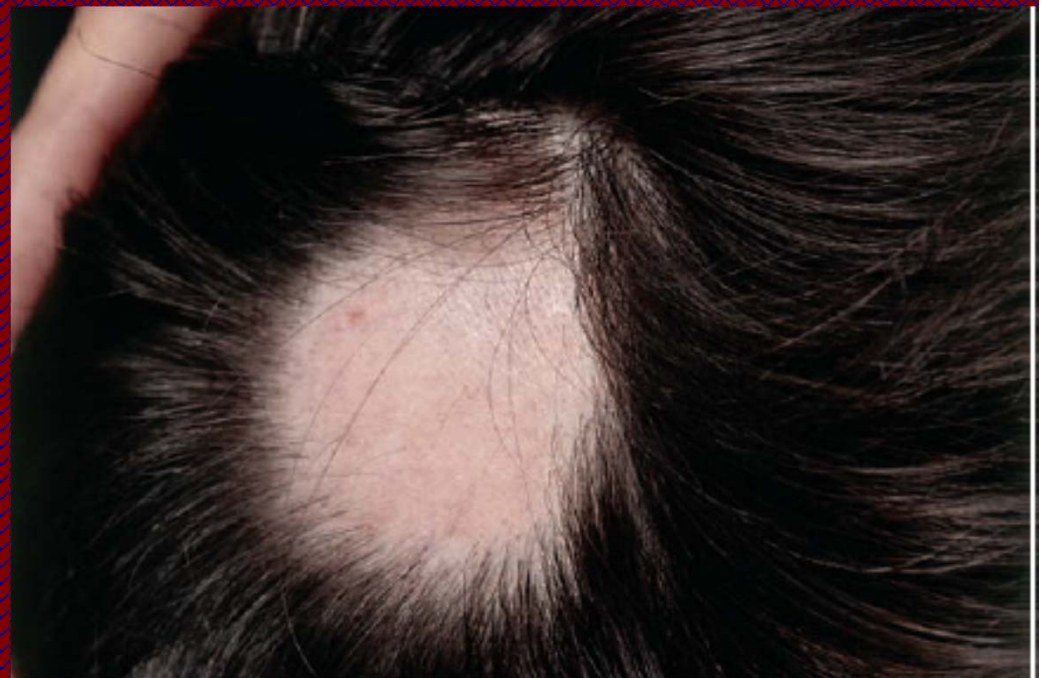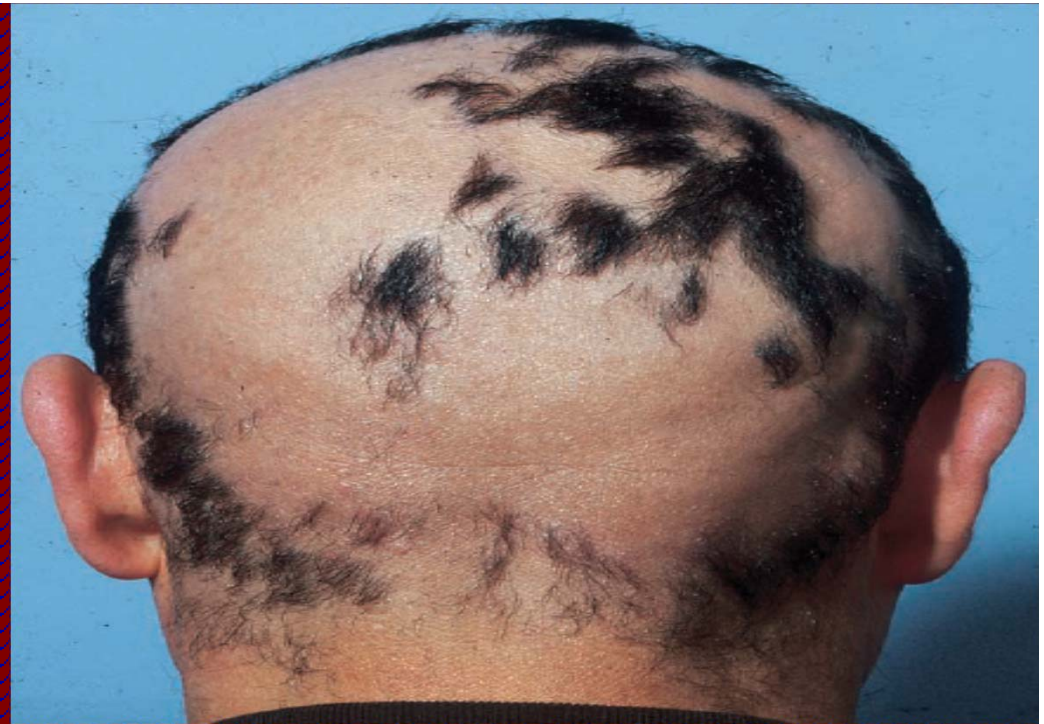Deformities



# Complaints pertaining to hair

**Alopecia (Loss of Hair)**

**Patchy- Alopecia Areata**

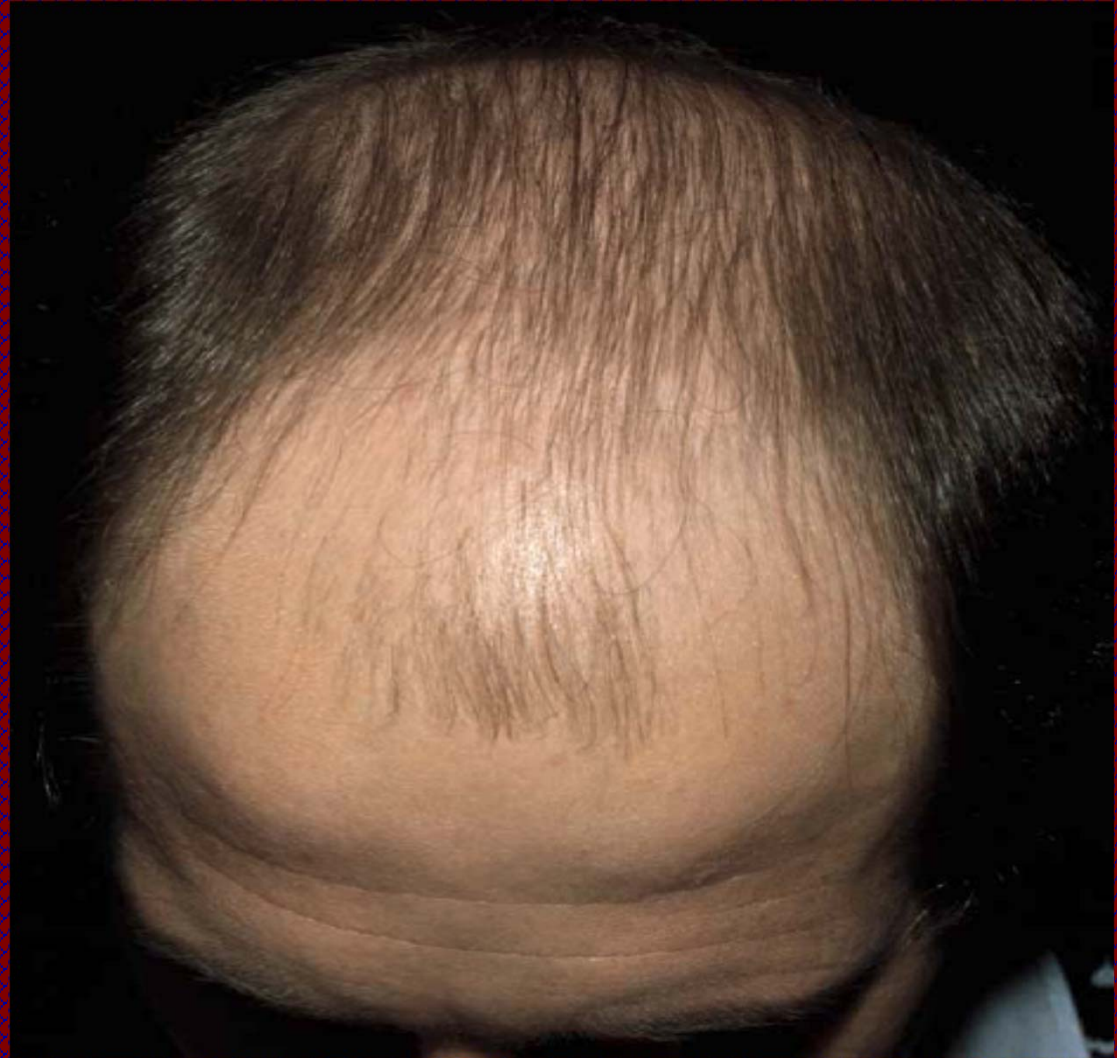

# *Alopecia Universalis*



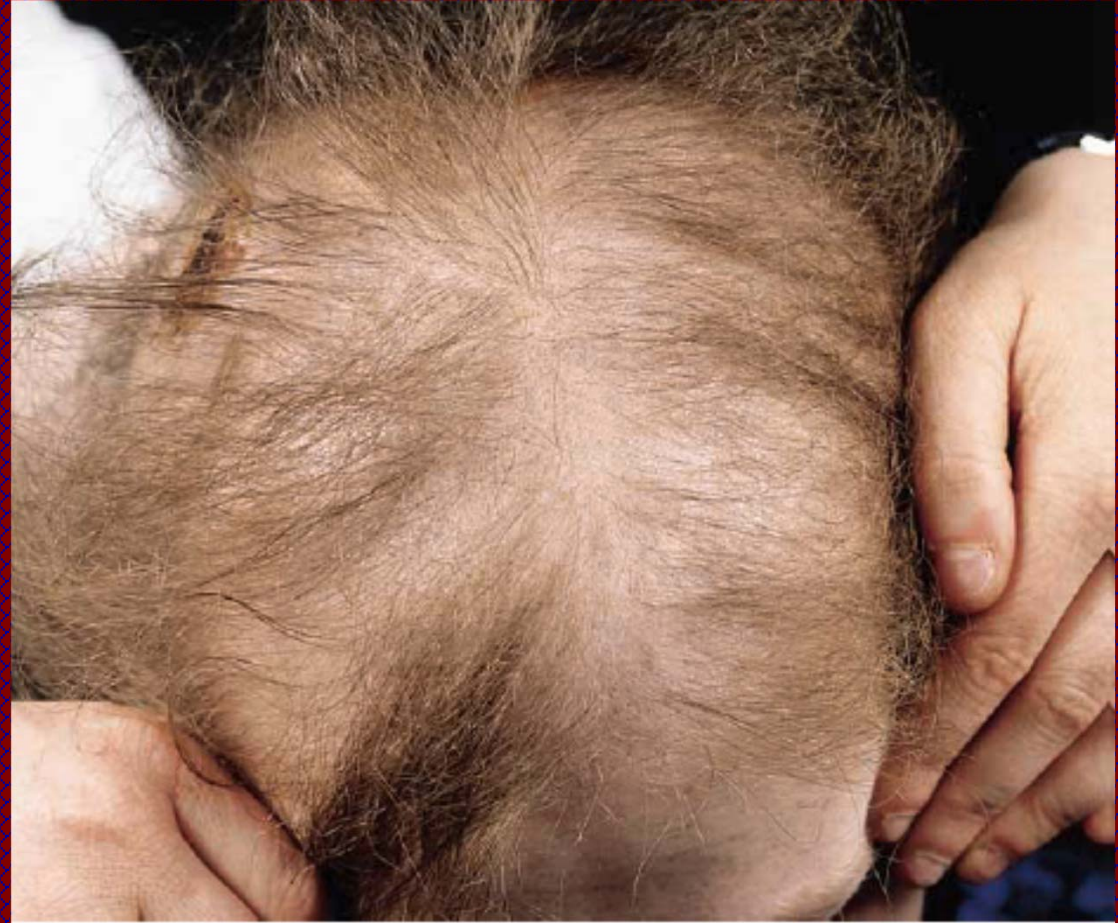# Diffuse Alopecia

Androgenetic  
Alopecia



# Diffuse Alopecia

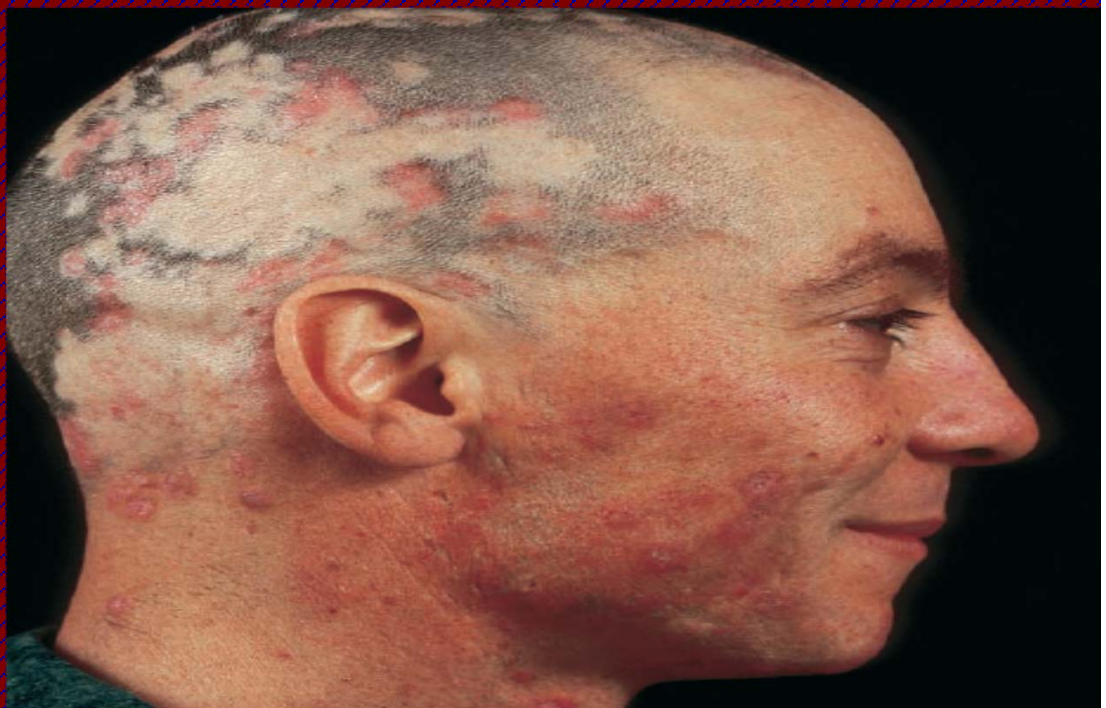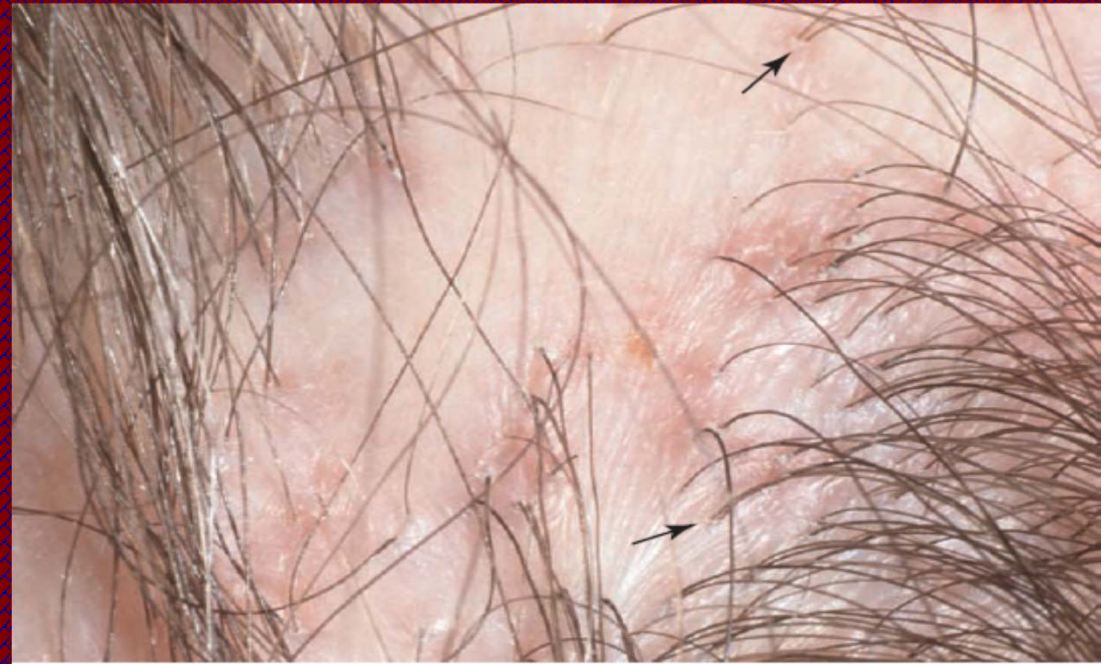Systemic Disease



# Scarring Alopecia


Lichen planus

DLE



# Hypertrichosis

Excessive hair



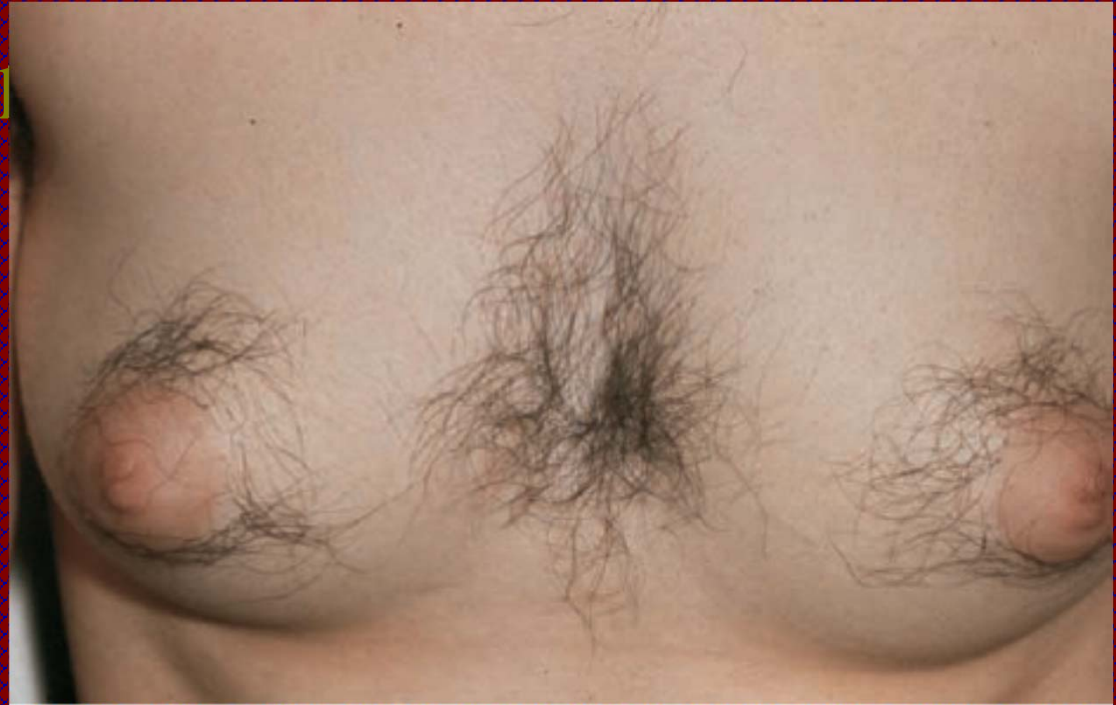

# Hirsutism

Excessive hairs in male  
pattern distribution

-Porphyrias

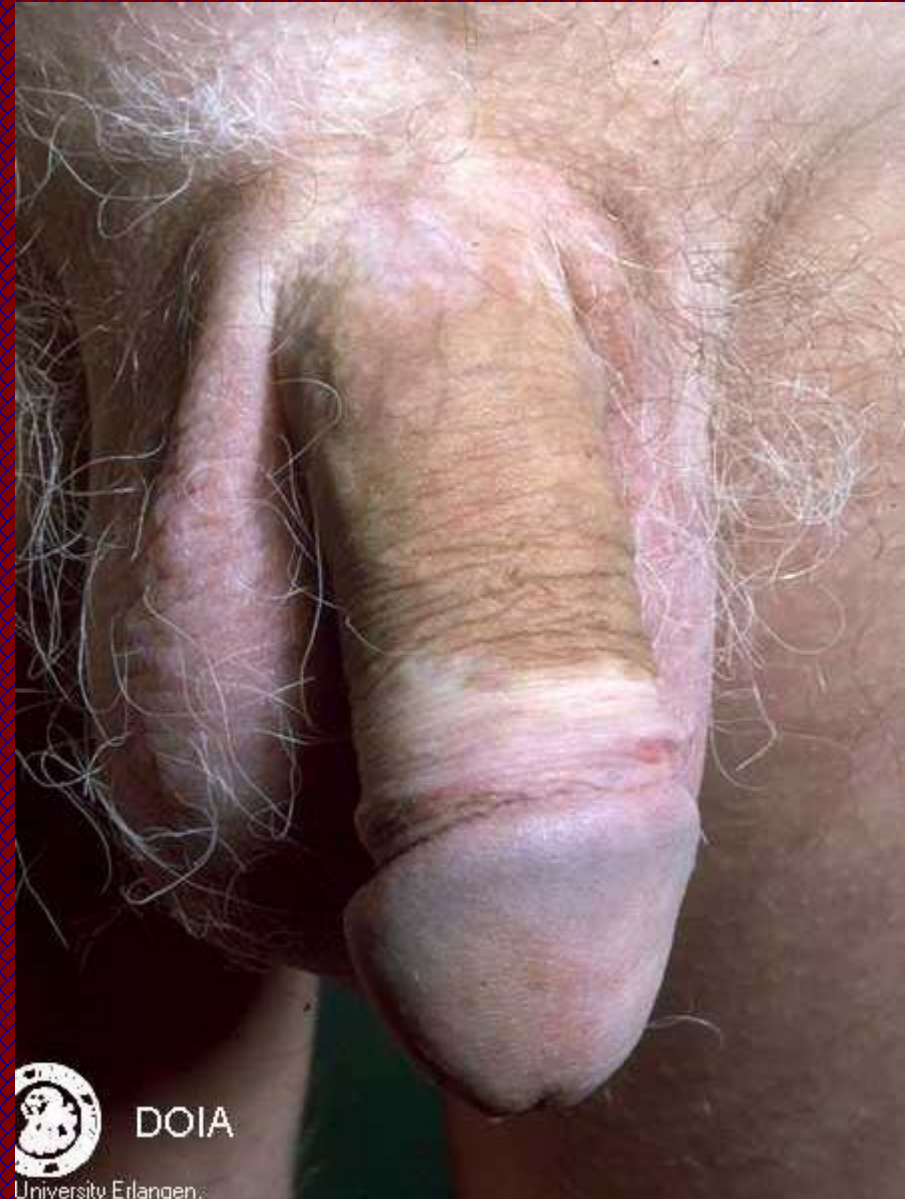-Drugs



# Discolouration of hair

Premature Greying (Canities)

Leukotrichia



DOIA

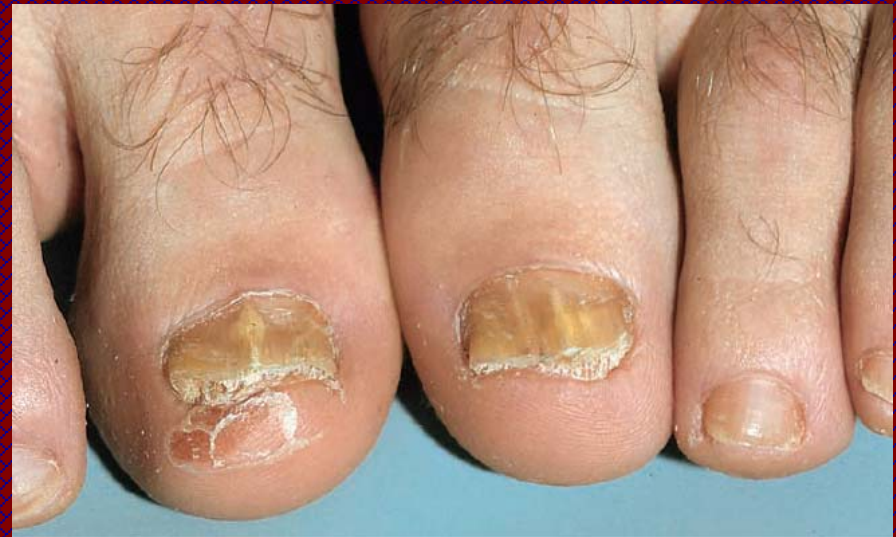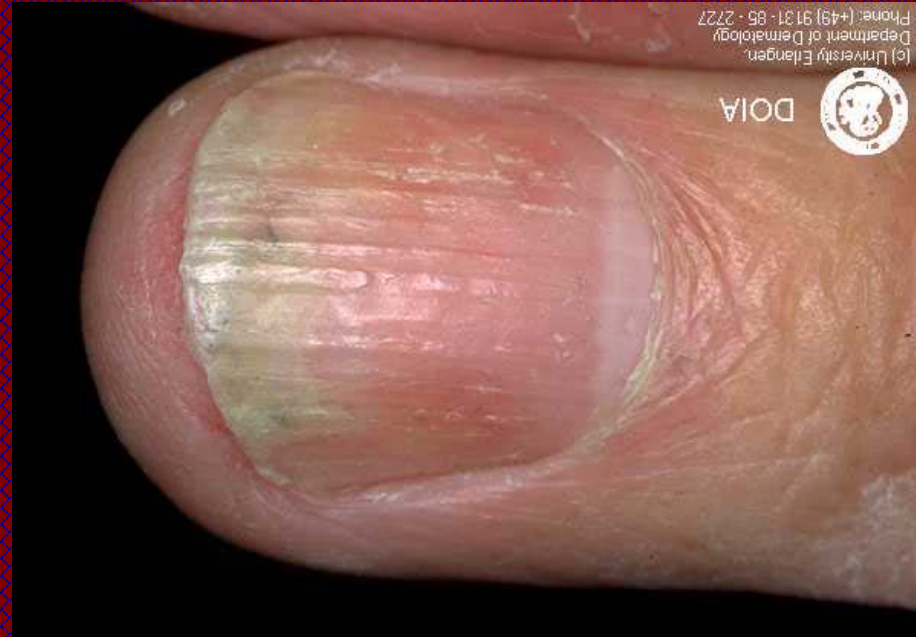University Erlangen

# Nail Changes

Discolouration of nail plate

-Psoriasis

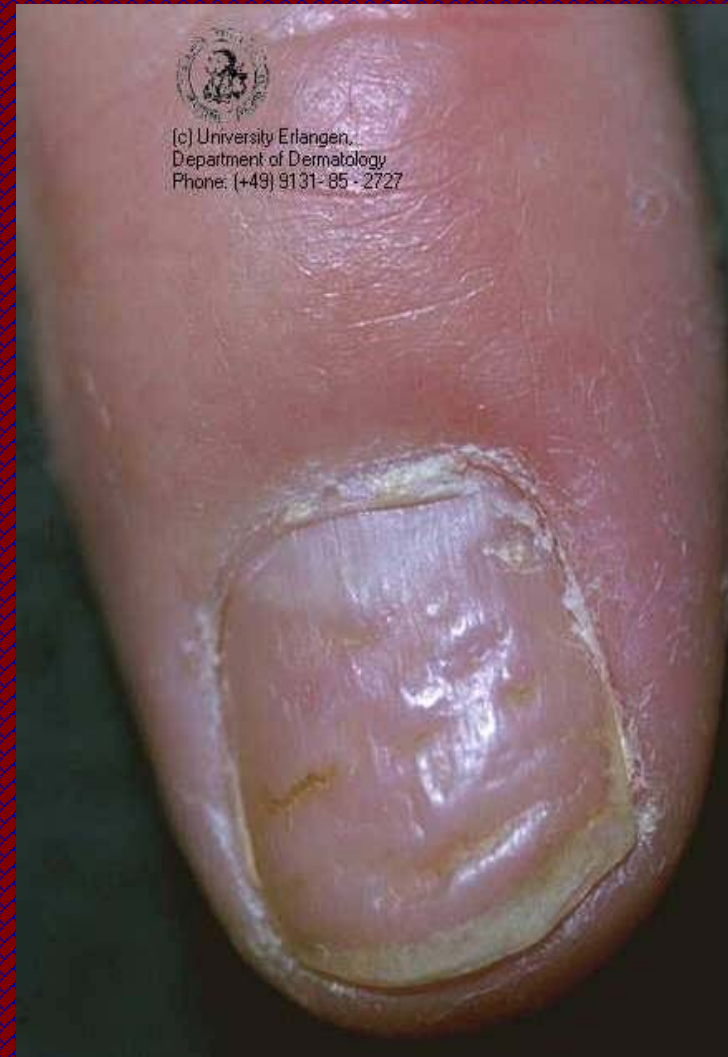-Onychomycosis



# Nail Changes

Destruction of nail plate

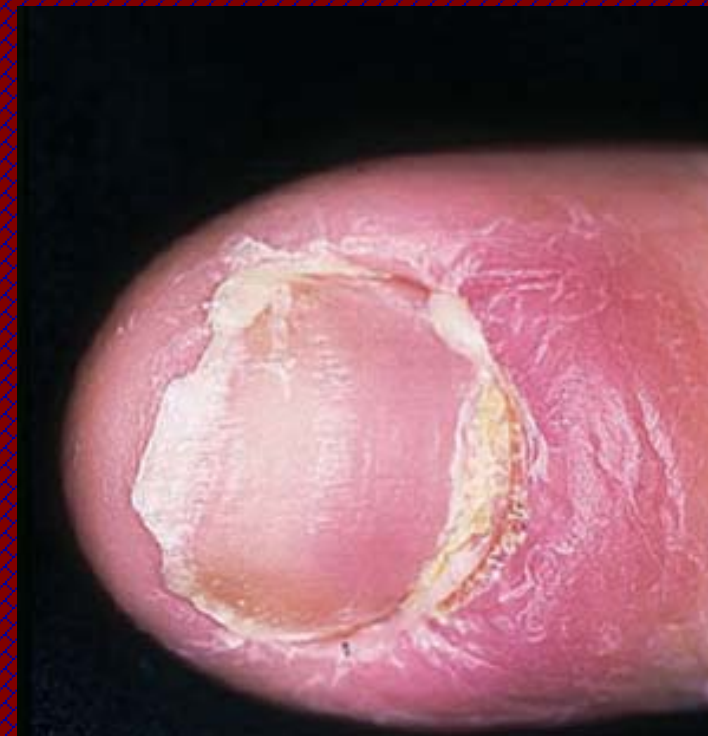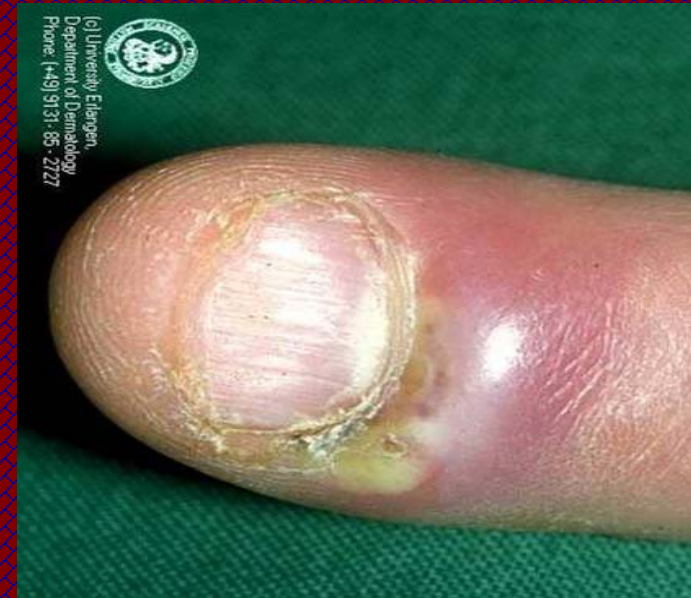Psoriasis



# Nail Changes

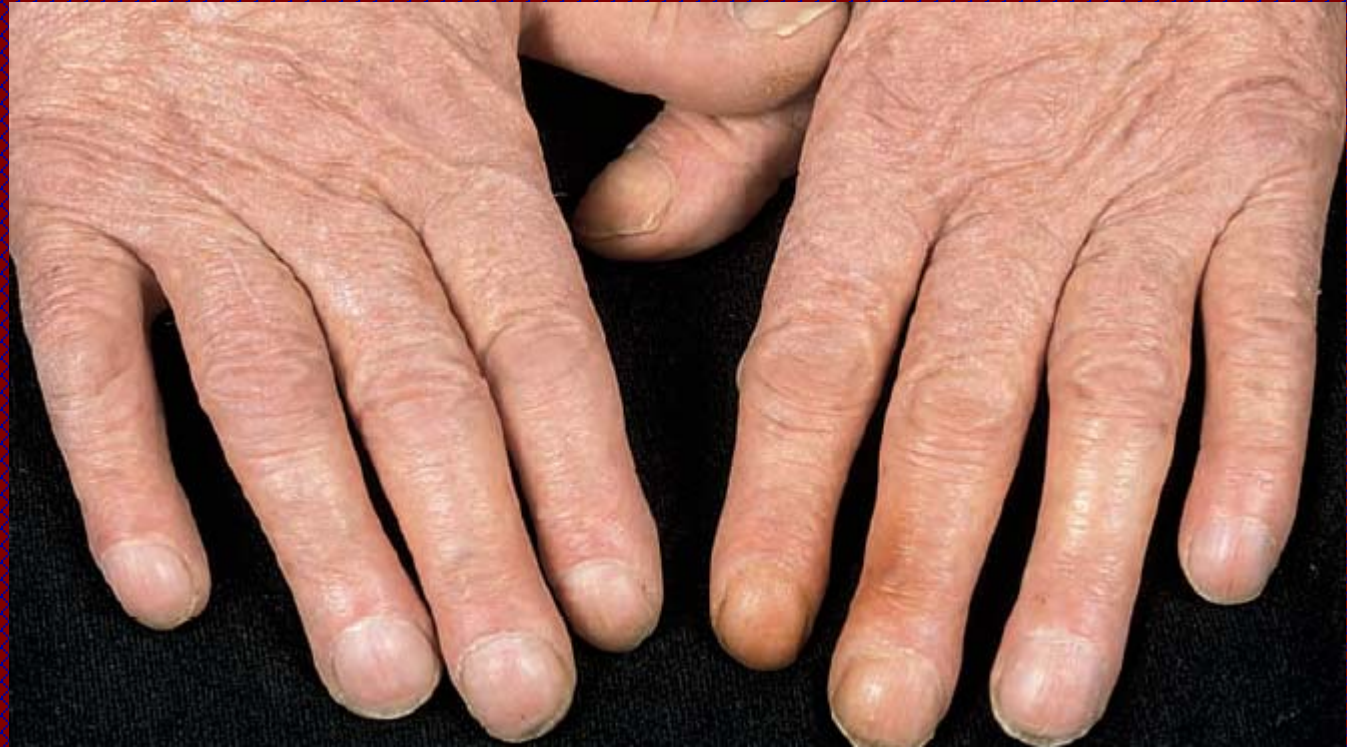## Paronychia

Inflammation of nail folds



# Nail Changes

## Clubbing



## **HYPERKERATOSIS**

Thick St. corneum (Hardening)

## **PARAKERATOSIS**

Nucleated cells in St. corneum (scaling )

## **ACANTHOSIS**

Thickness of epidermis

## **ACANTHOLYSIS**

Separation of Keratinocytes

# Clinical examination

## History

- Present
- Past
- Family history
- SE status



# General Physical Examination

## Systemic Examination

As in Internal Medicine

# Cutaneous Examination

Examination of

-Hair

-Nail

-Mucosae- Nasal, oral  
conjunctival, genital, anal

-Palms & soles


-Scalp

-Flexures

# CUTANEOUS EXAMINATION

Inspection

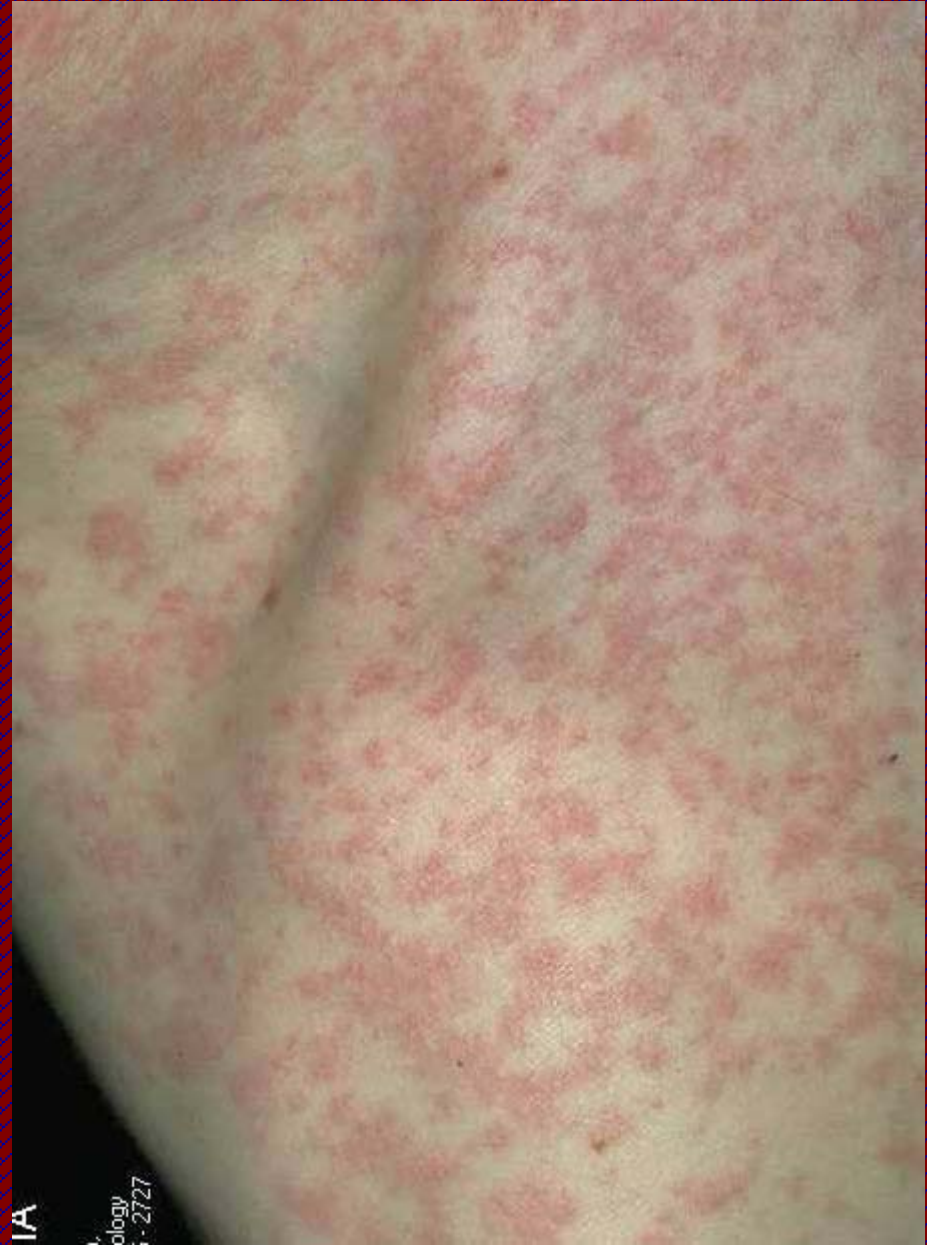Palpation



Mainly

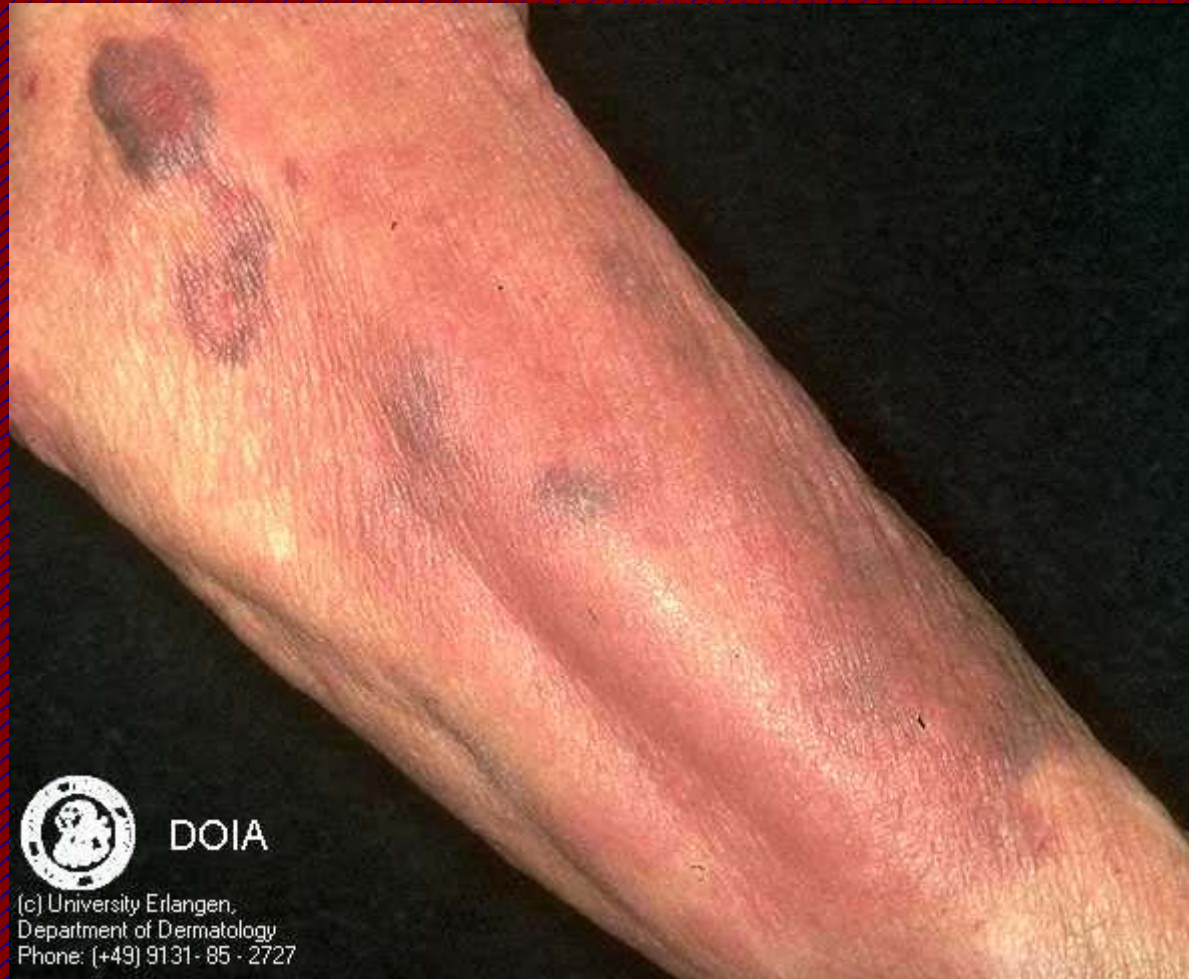## Visible skin lesion

**Macule** :Circumscribed  
change in skin colour without  
change in texture or palpable  
thickening(<0.5cm)



# PATCH

>0.5cm dia.

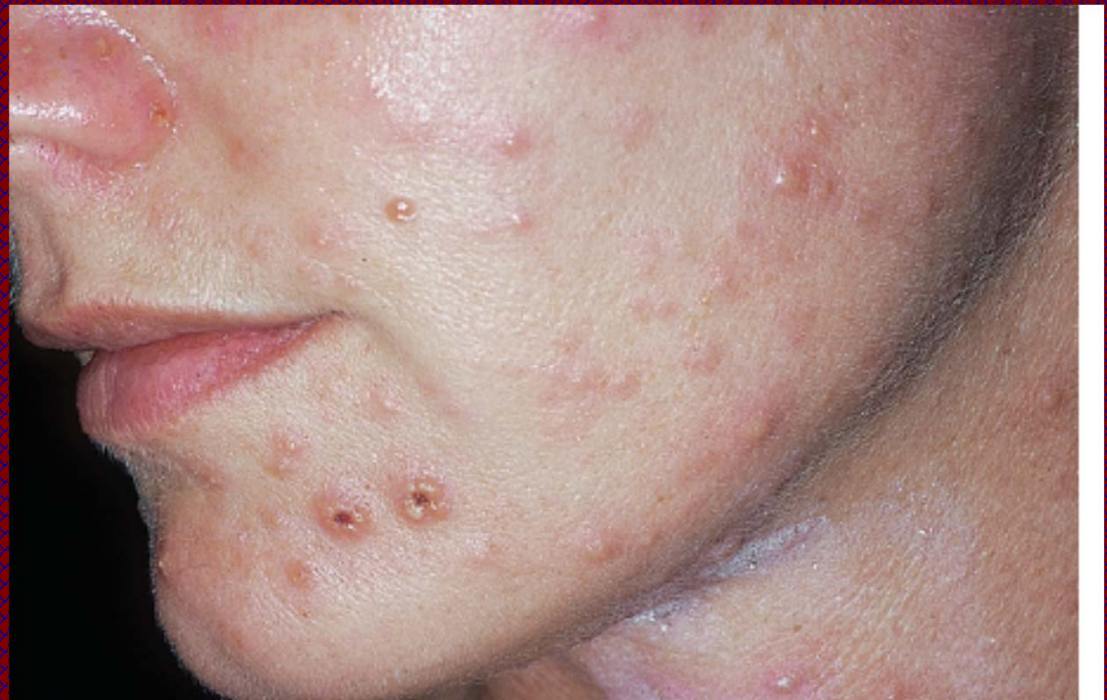


DOIA

(c) University Erlangen,  
Department of Dermatology  
Phone: (+49) 9131-85-2727

# Papule

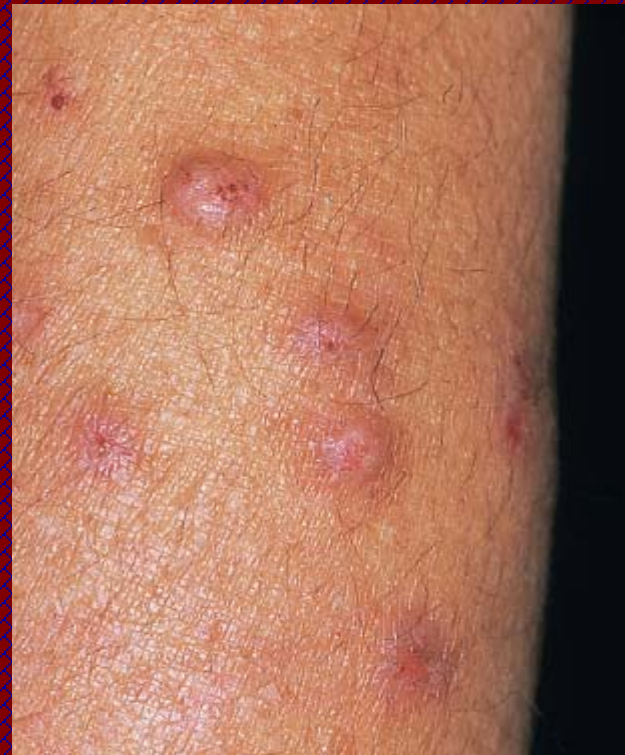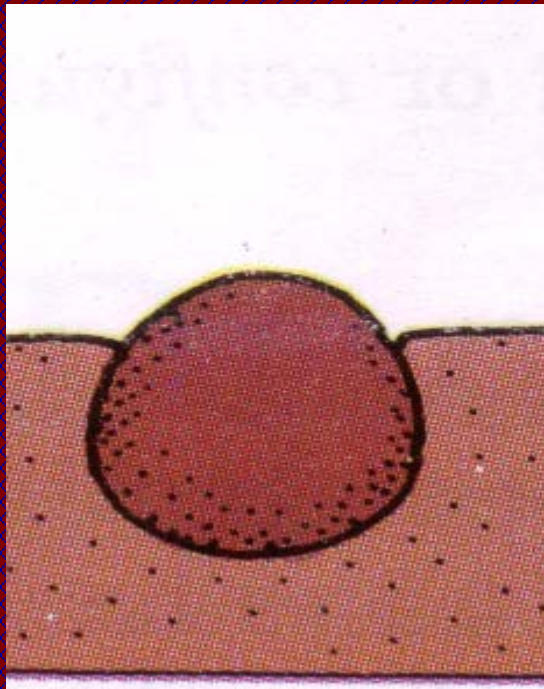
Circumscribed palpable elevation upto 0.5cm dia



# Nodule

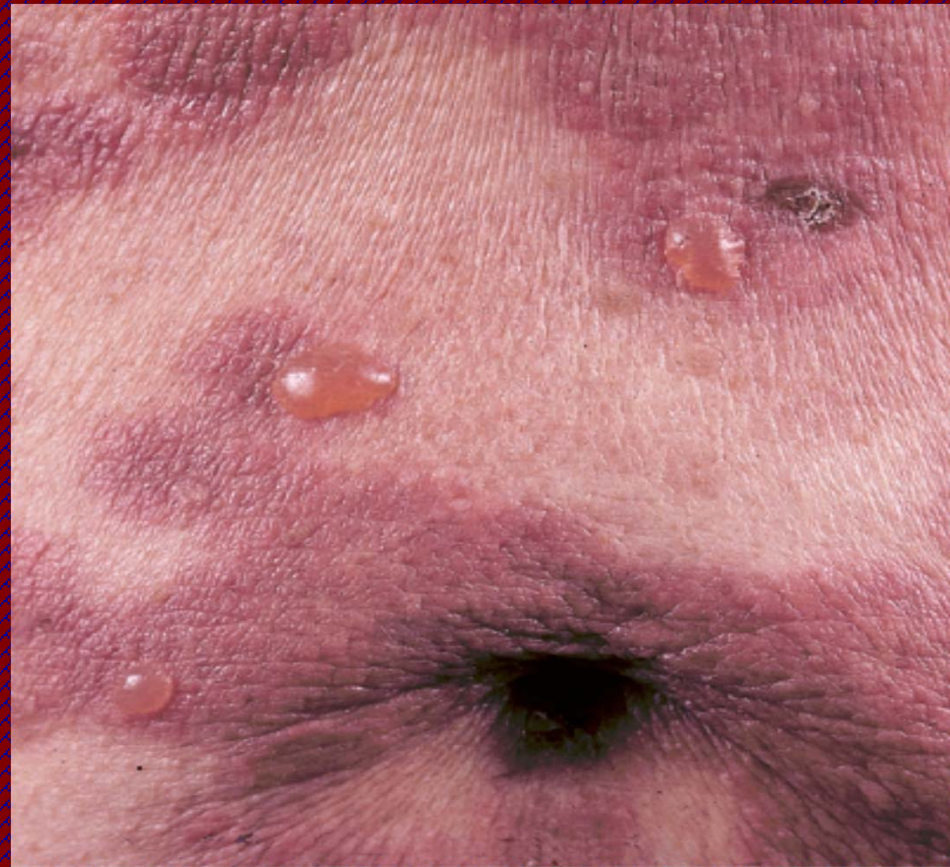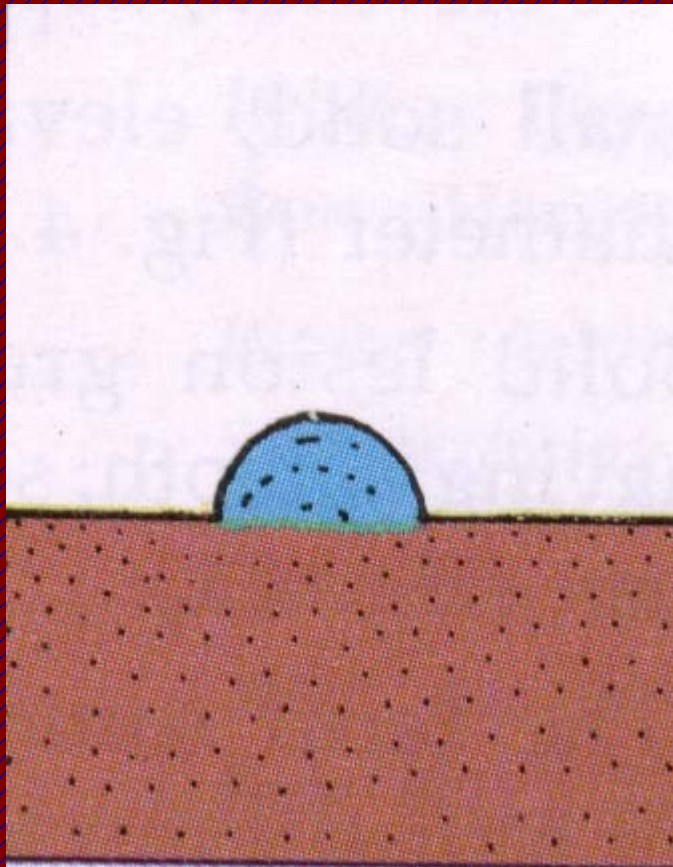
>0.5cm diameter

More felt than seen



# Vesicle

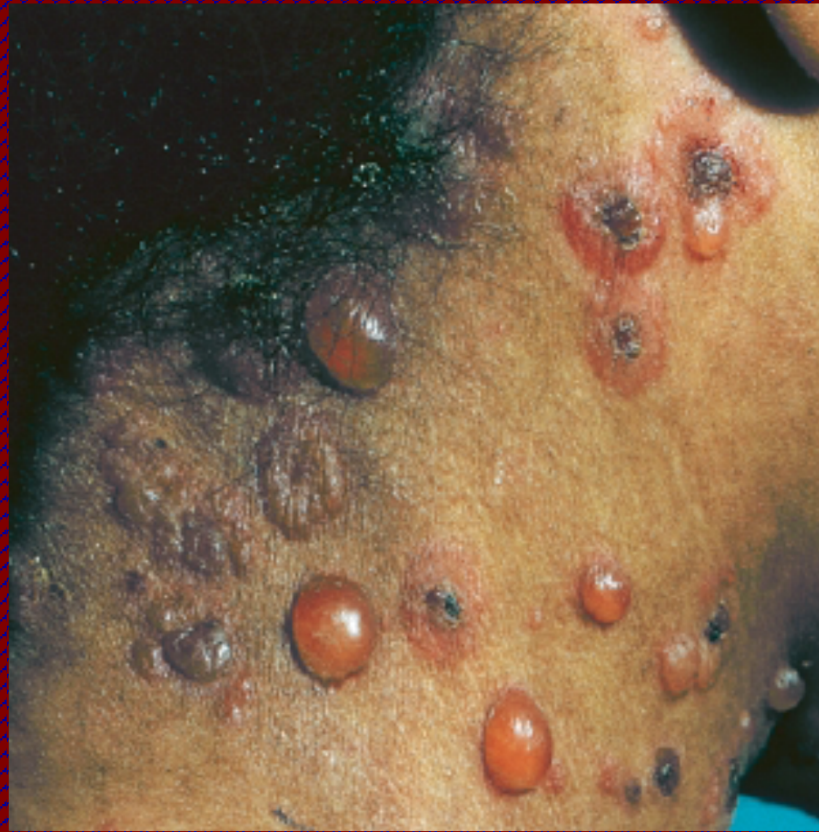
Visible accumulation of fluid upto 0.5cm dia





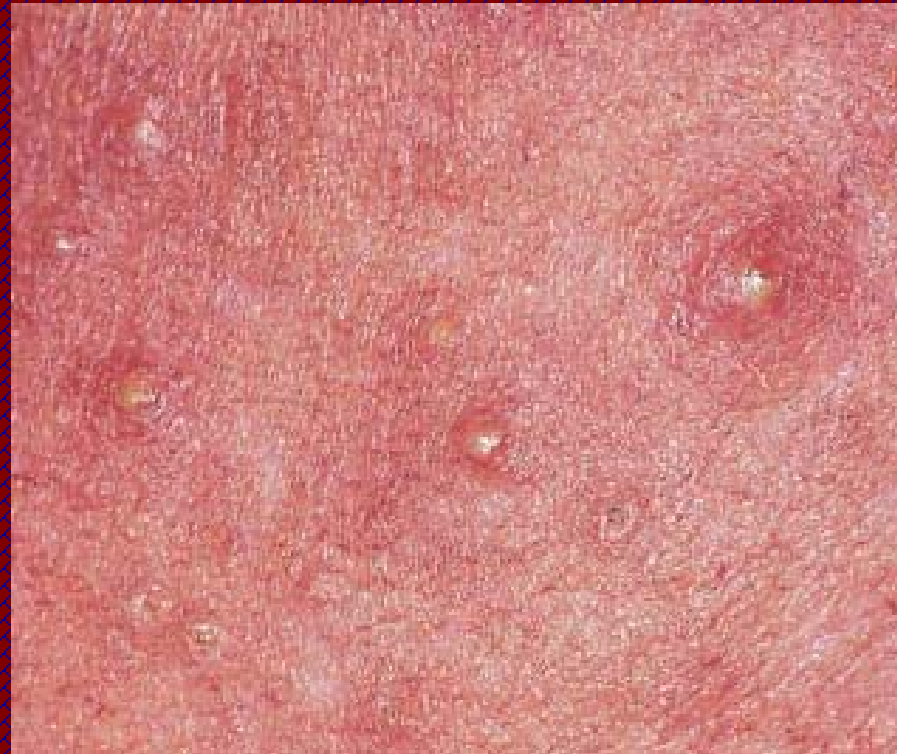
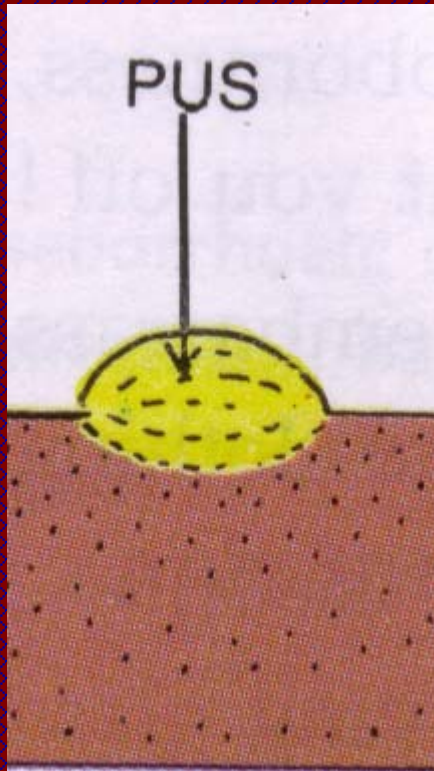
# Bulla

>0.5cm dia.



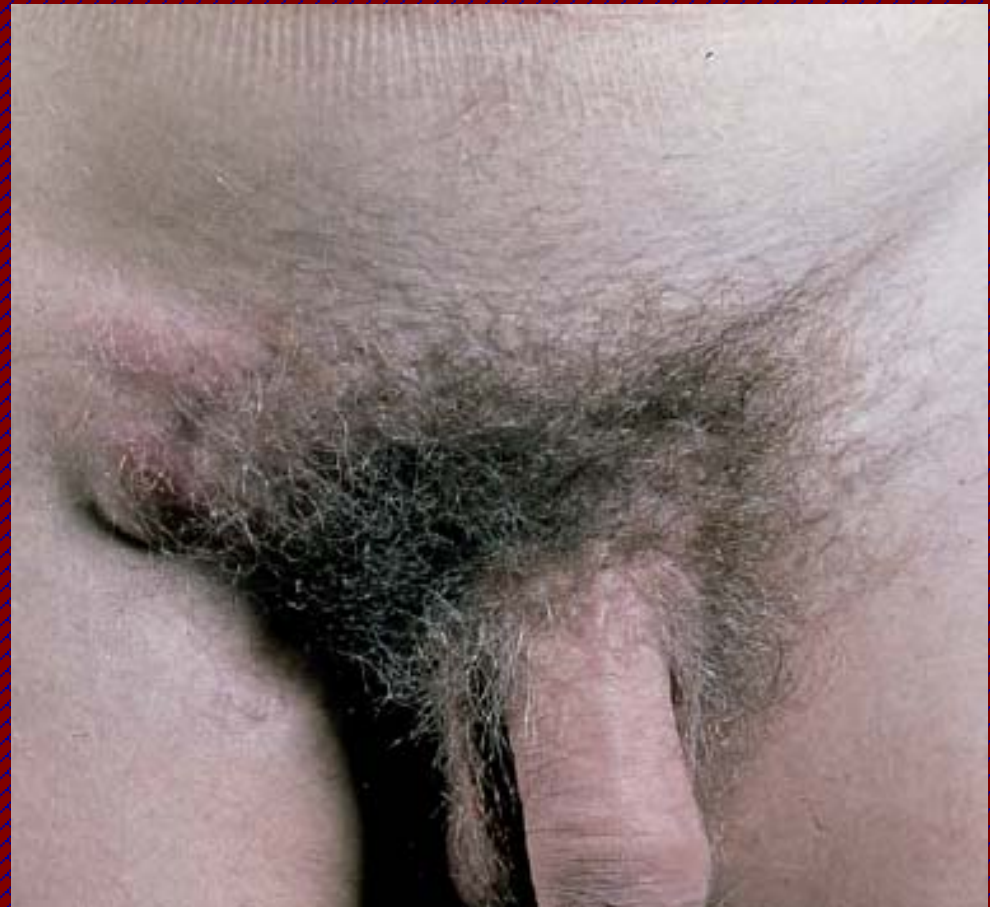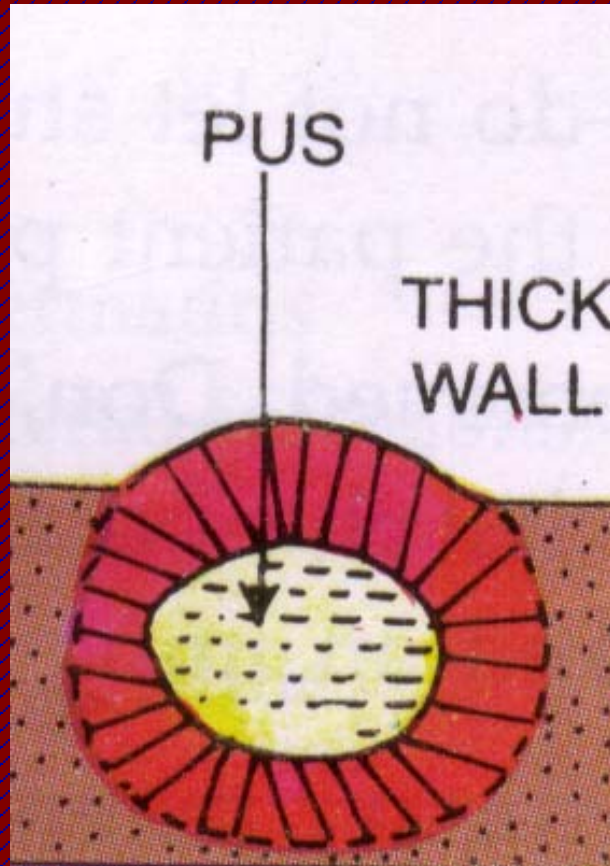
# Pustule

Pus filled lesion upto 0.5cm



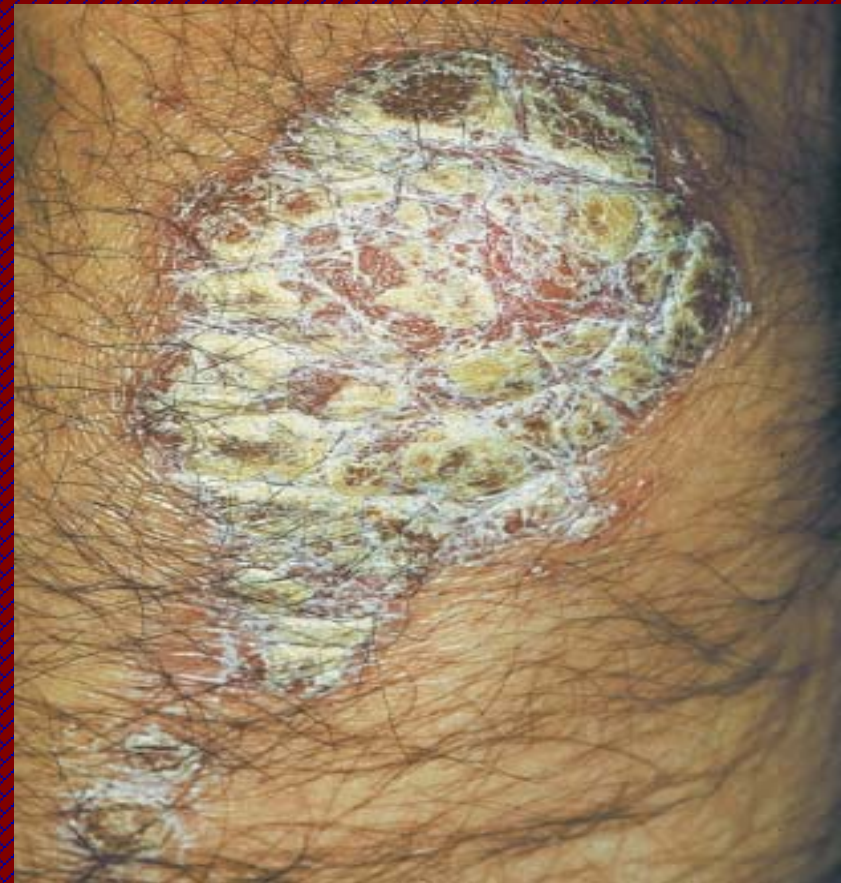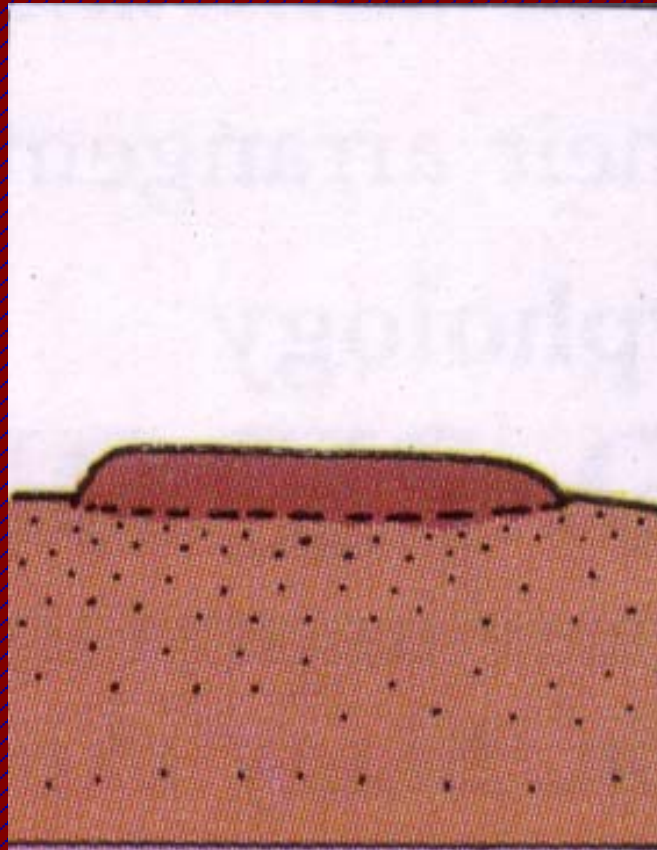
# Abcess

>0.5cm dia. deeper



# Plaque

Disc shaped lesion  $>0.5\text{cm}$  dia

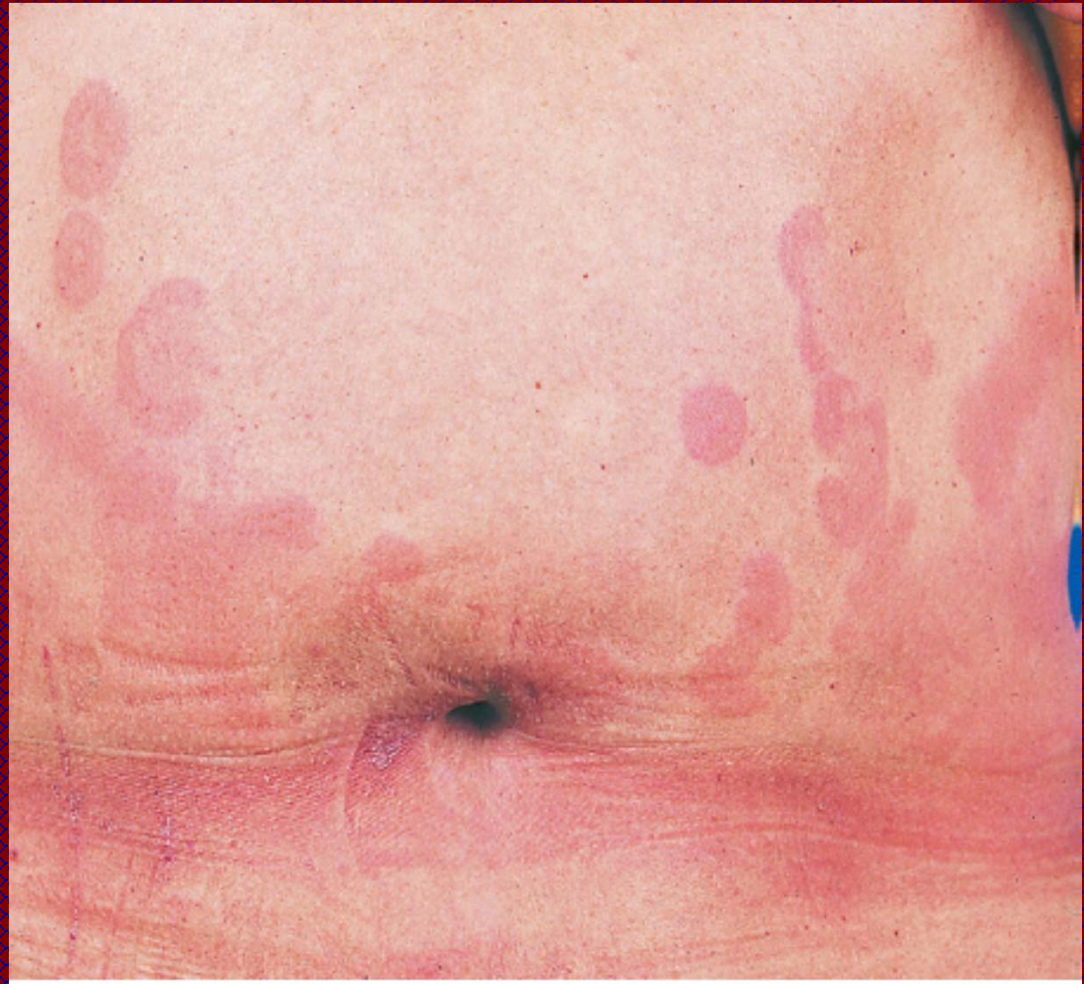

# Weal

Dermal /hypodermal  
edema ,compressible,

Pitted,Evanescent

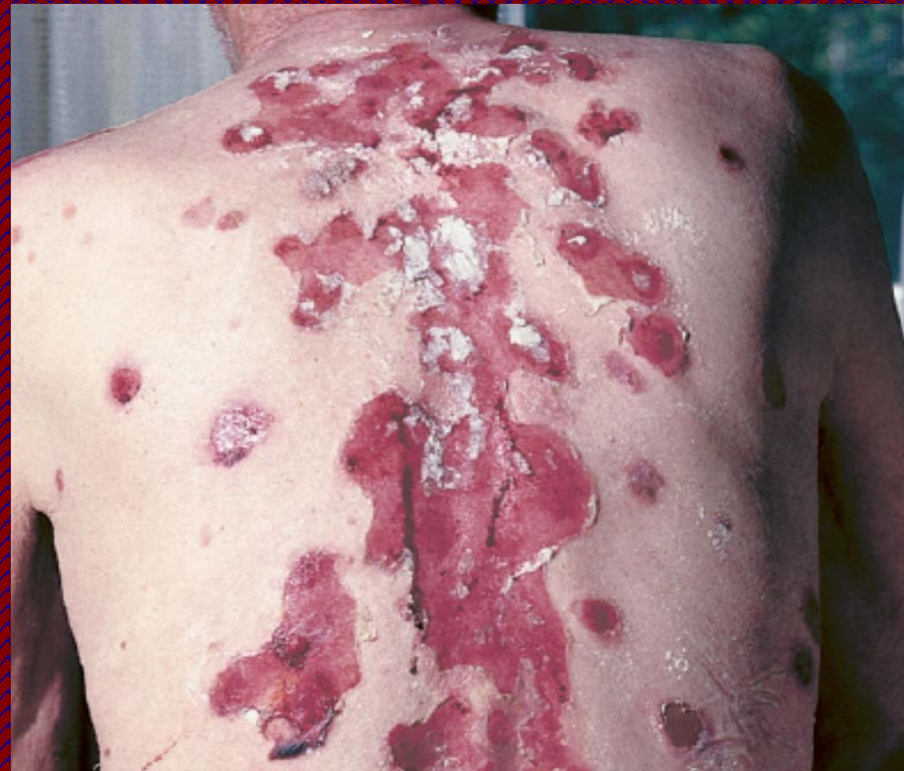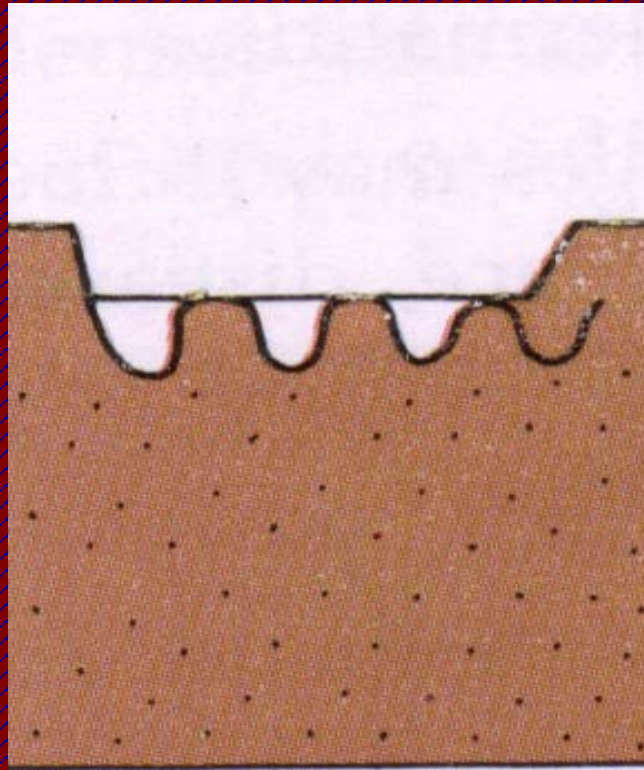
urticaria



# Erosion

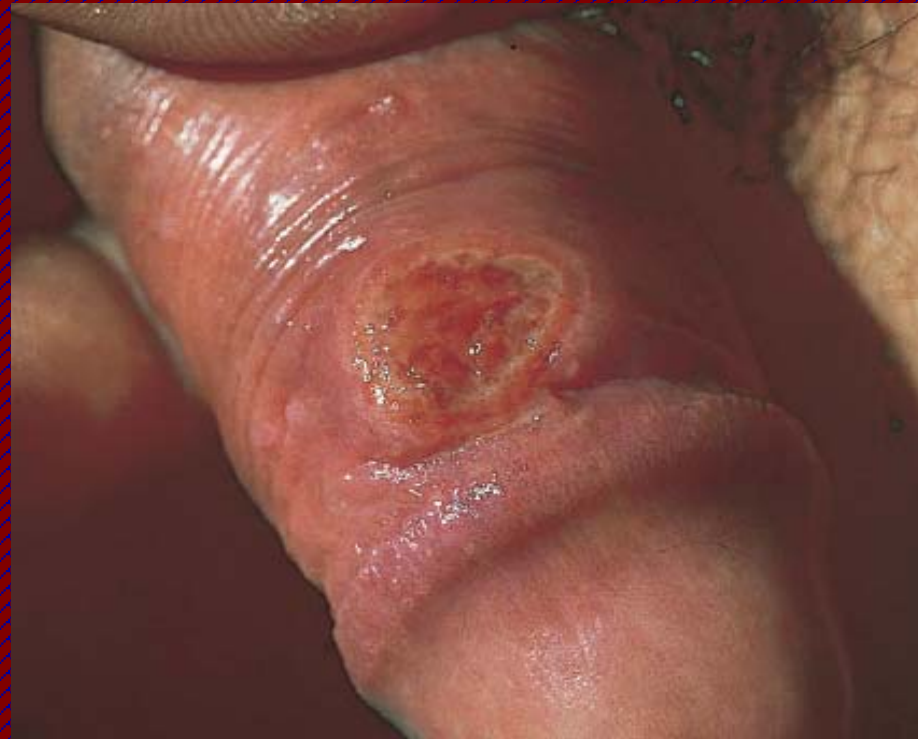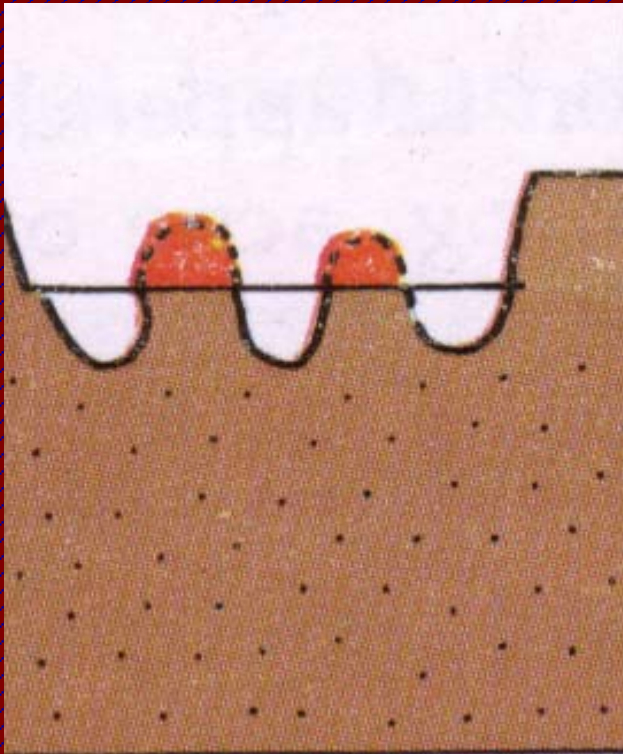
Loss of epidermis/epithileum

Abrasion/Excoriation



# Ulcer

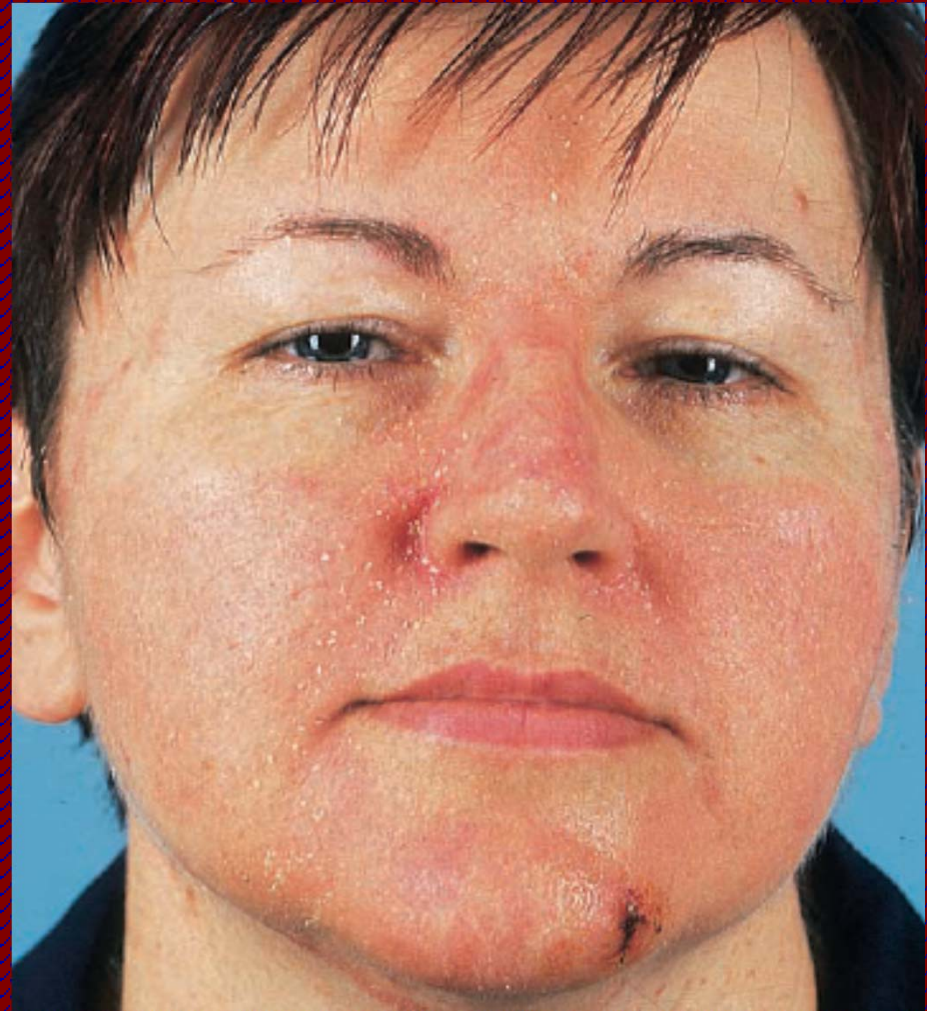circumscribed full thickness loss of tissue



# Scale

Visible accumulation of keratin/st. corneum

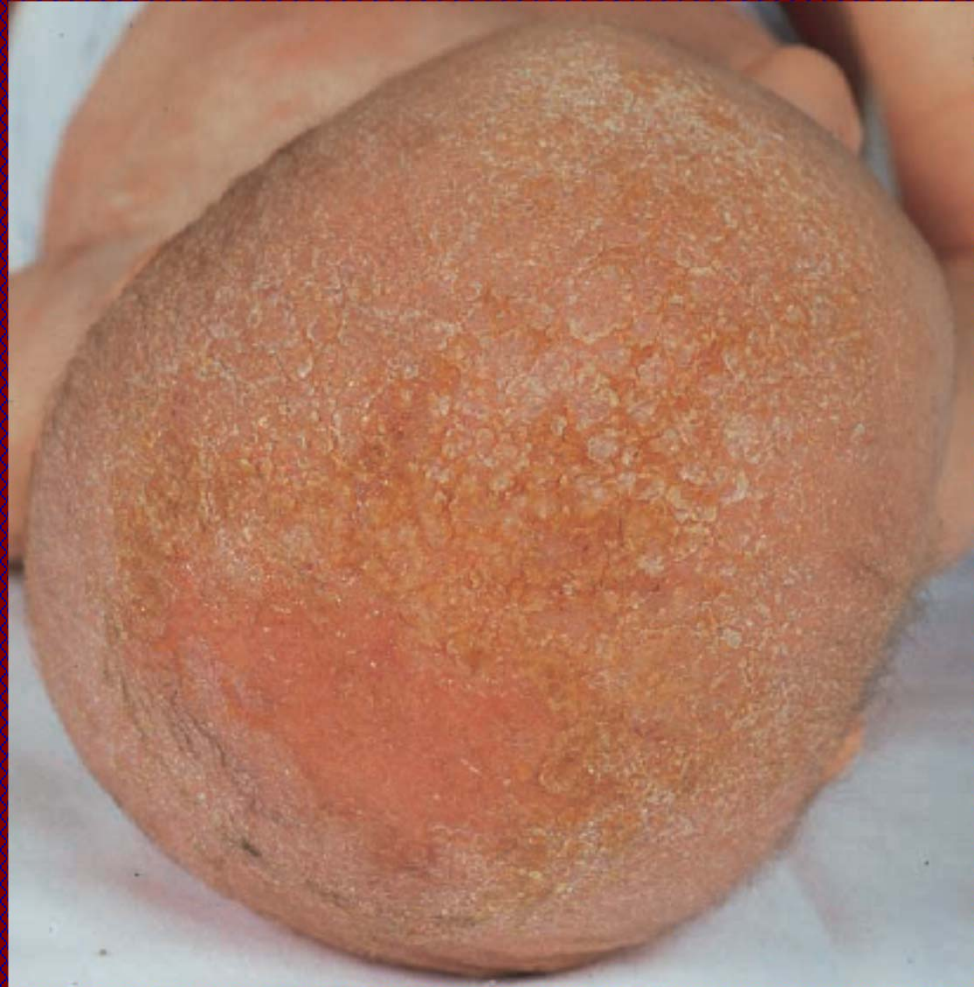- Adherent
- Greasy
- Silvery
- Non-adherent
- Dry





# Crust

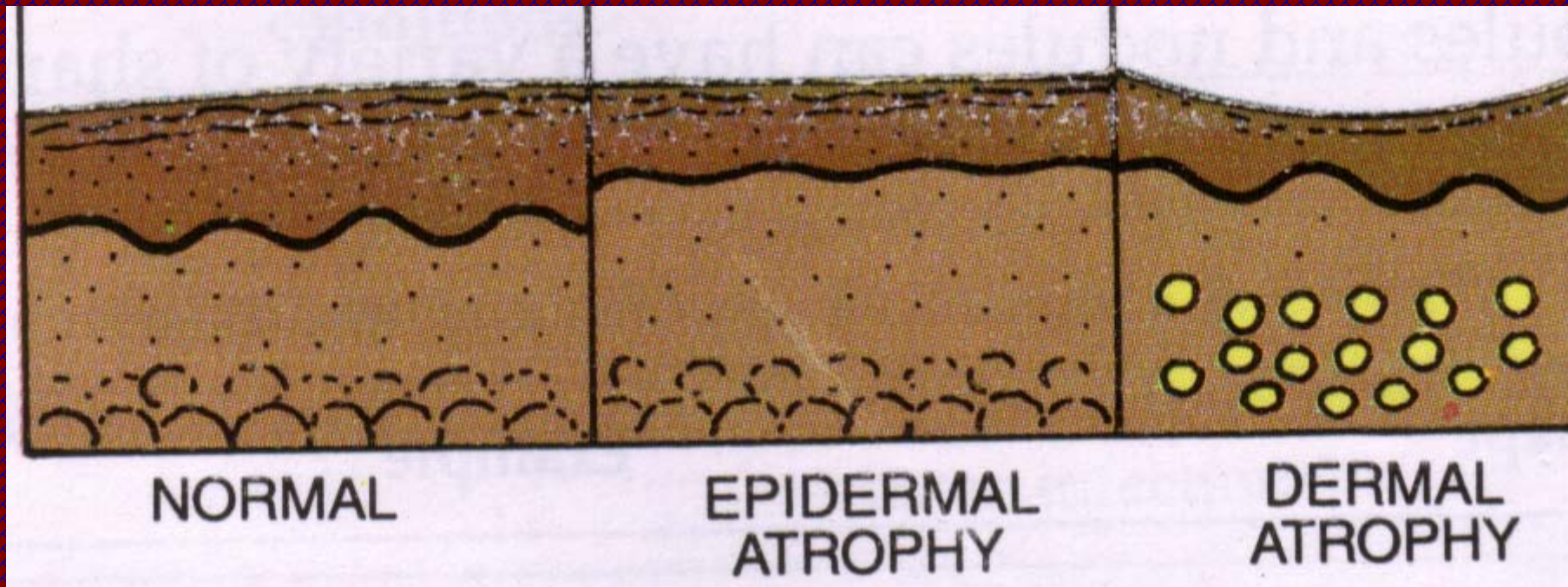
Dried serum/exudates/cell debris



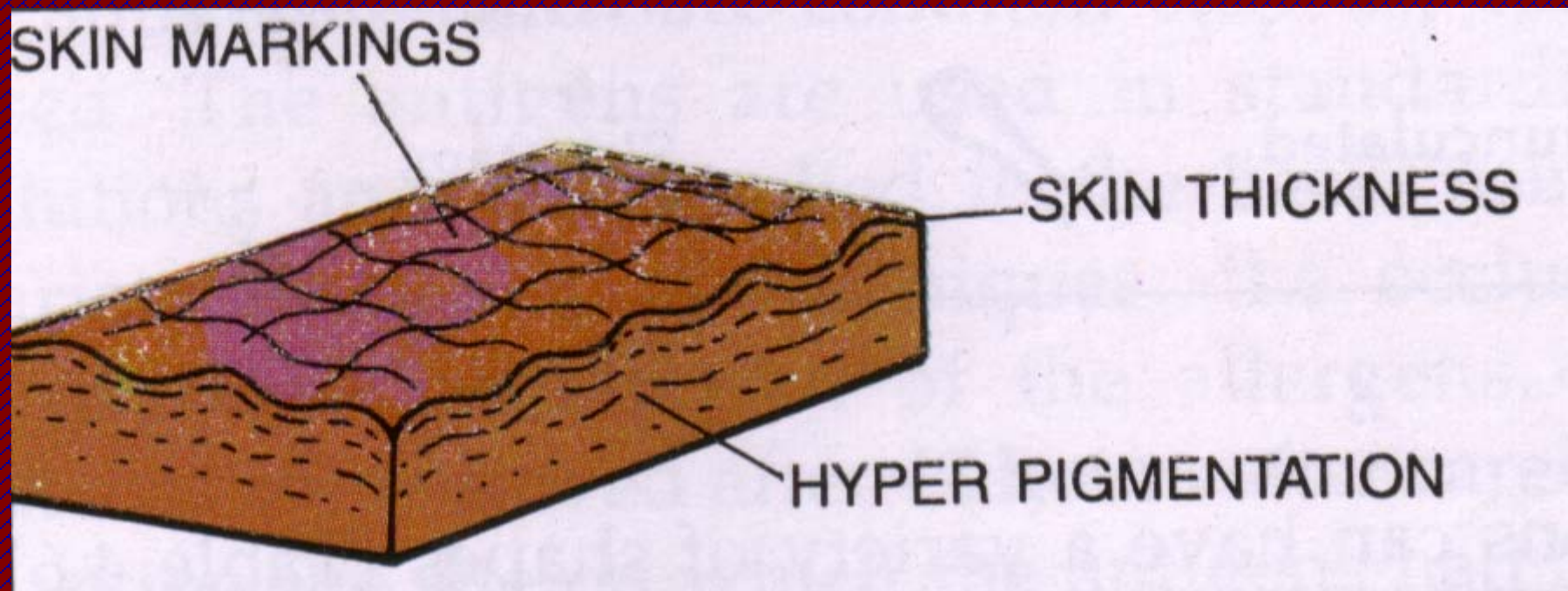
# Atrophy

Decrease in full thickness of skin

- Epidermal
- Dermal

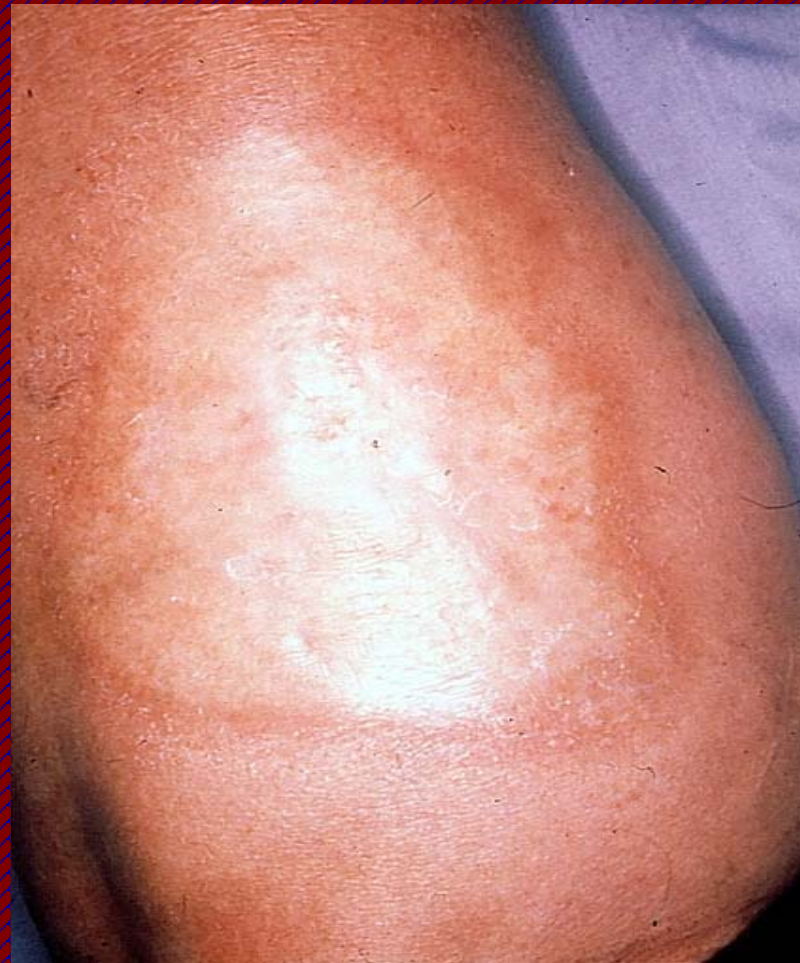

# Lichenification



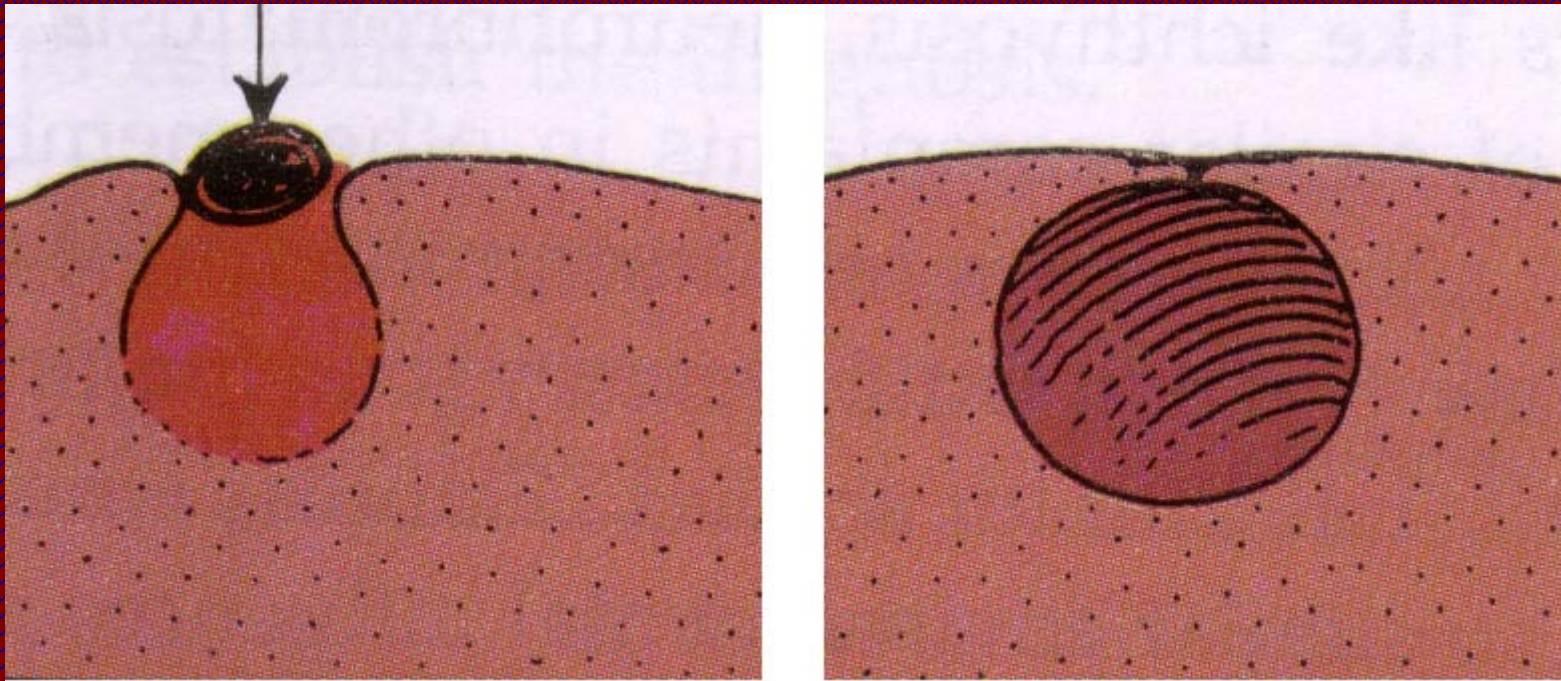
# Sclerosis

Loss of elasticity, binding down, combined with atrophy








# Comedone







## Acne Vulgaris



# PATHOLOGICAL DIAGNOSIS

- Dermatitis reg
- Gen. Pruritus
- Purpura
- Vasculitis
- Exfoliative dermatitis (Erythroderma)
- Hypomelanosis
- Hypermelanosis
- Alopecia
- Urticaria

Arrangement		Example
Grouped		Herpes simplex
Linear		Linear epidermal naevus
Dermatomal		Herpes zoster
Serpiginous		Burrow
Arcuate		Granuloma annulare

Shape		Example
Dome shaped		Molluscum conta
Flat topped		Plane warts
Umblicated		Molluscum conta
Acuminate		Genital warts
Verrucous		Verruca vulgaris
Pedunculated		Skin tags



**Table 4.6 : Shapes of skin lesions.**

**Nummular (Discoid)**



Nummular dermatiti

**Annular**



Tinea corporis

**Circinate**



Herpes simplex

**Arcuate (arciform)**




Granuloma annulare

**Gyrate**



Some forms of tinea

**Retiform (reticulate)**



Macular amyloidosis