

# FUNGAL INFECTIONS ( MYCOSES )



## **SUPERFICIAL MYCOSES**

- Pityriasis versicolor (*Malassezia furfur*)
- Dermatophytosis  
(Tinea/Ringworm)

## **DEEP MYCOSES**

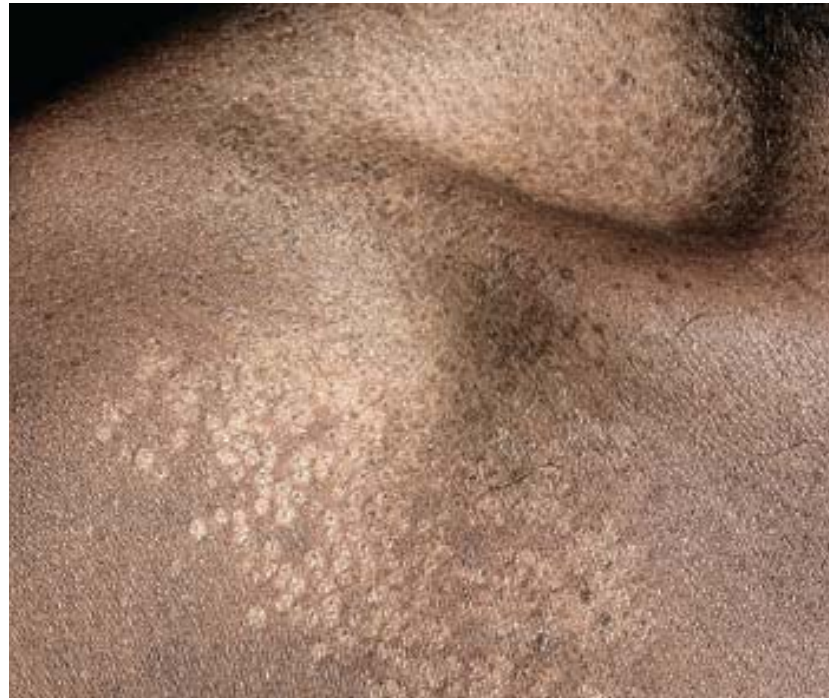## **MIXED MYCOSES**

- Candidiasis

# Pityriasis Versicolor

**Malassezia furfur**

**(Pityrosporum - ovale - orbiculare)**



# **P. Versicolor**

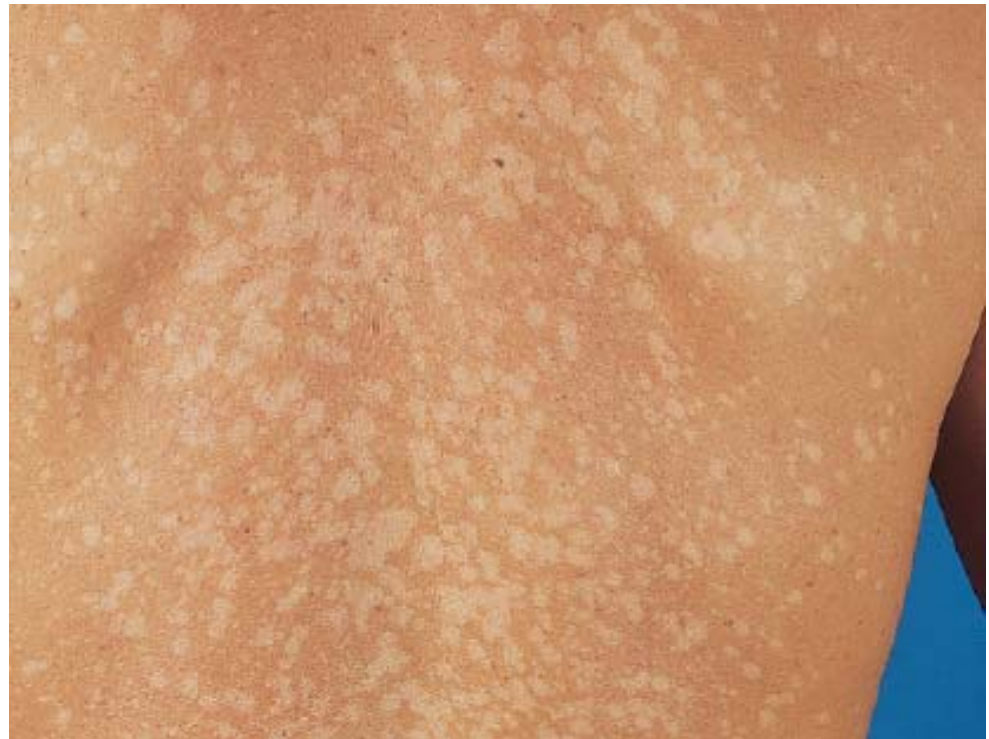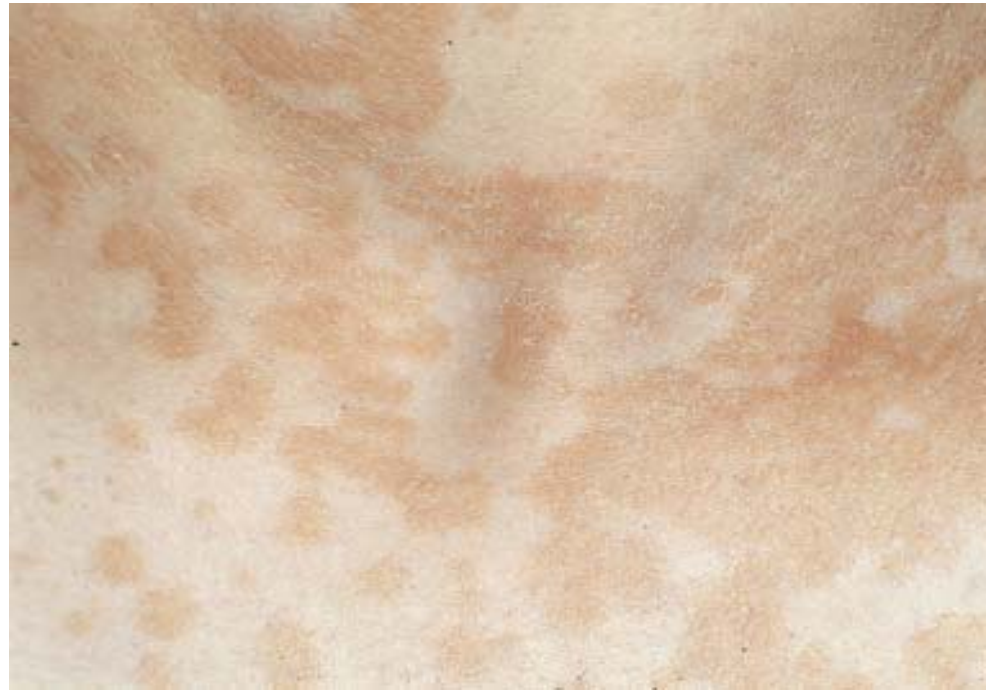## **Variable colour**

Hypopigmented

Hyperpigmented

-Superficial scaly plaques

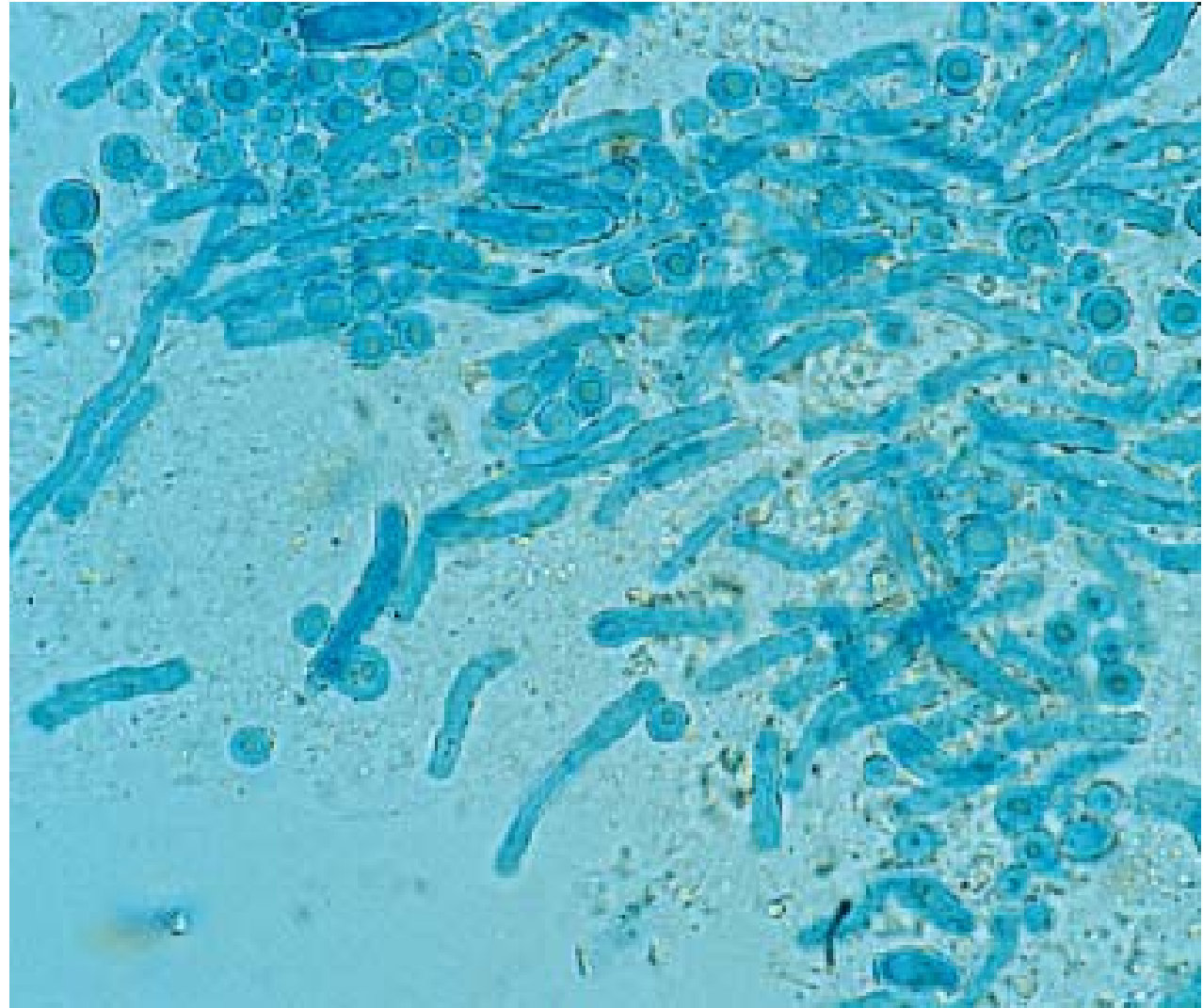
-Recurrence/ Relapse



# **P. Versicolor**

## **Diagnosis**

- KOH exam
- Culture



# Treatment



## Topical

- Clotrimazole
- Selenium sulphide
- Zinc pyrithione



## Systemic

Fluconazole - 400mg single dose

Itraconazole - 100mg BD x 7 days

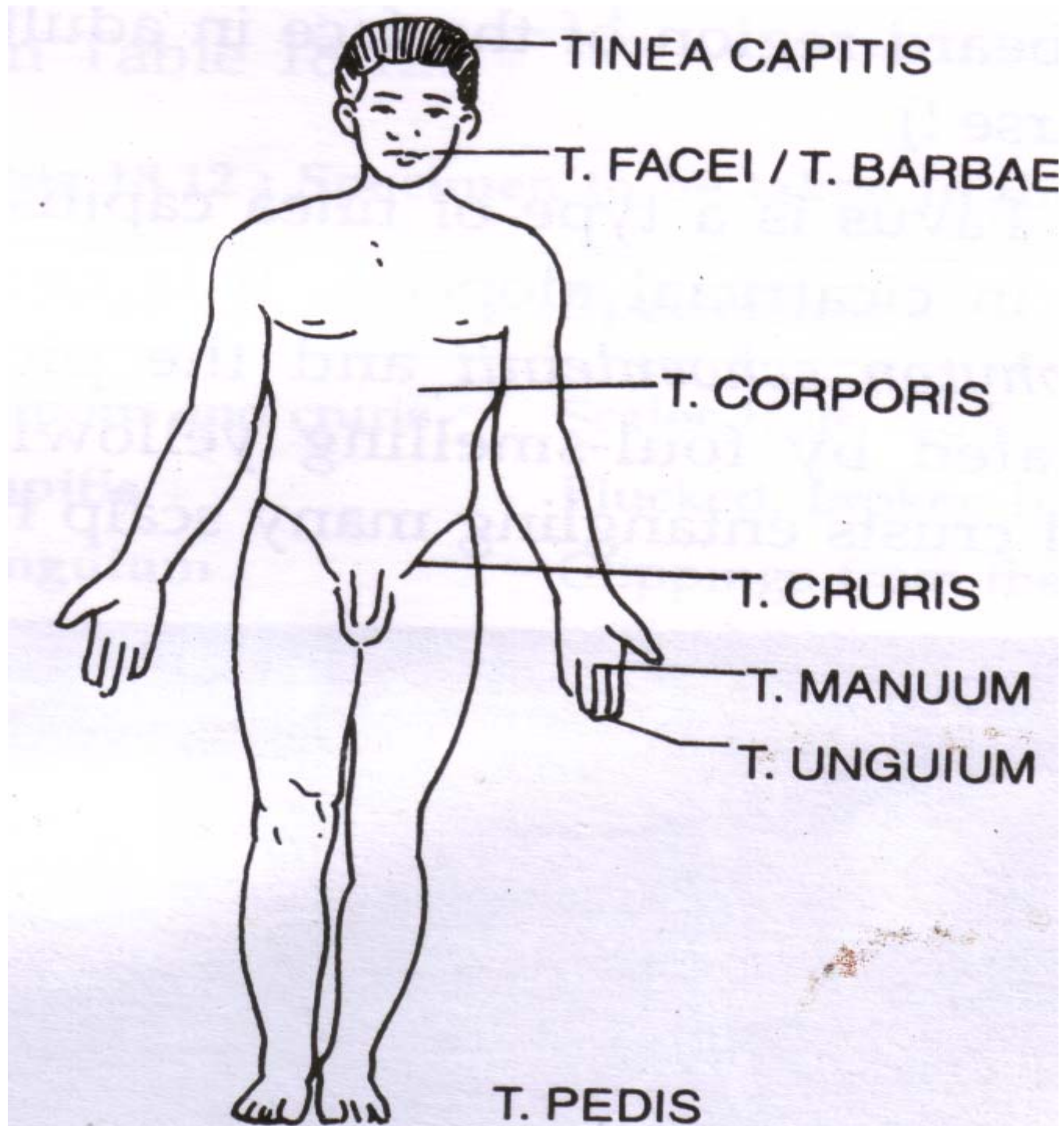
Ketaconazole - 400mg single dose

# DERMATOPHYTIC INFECTIONS

## TINEA

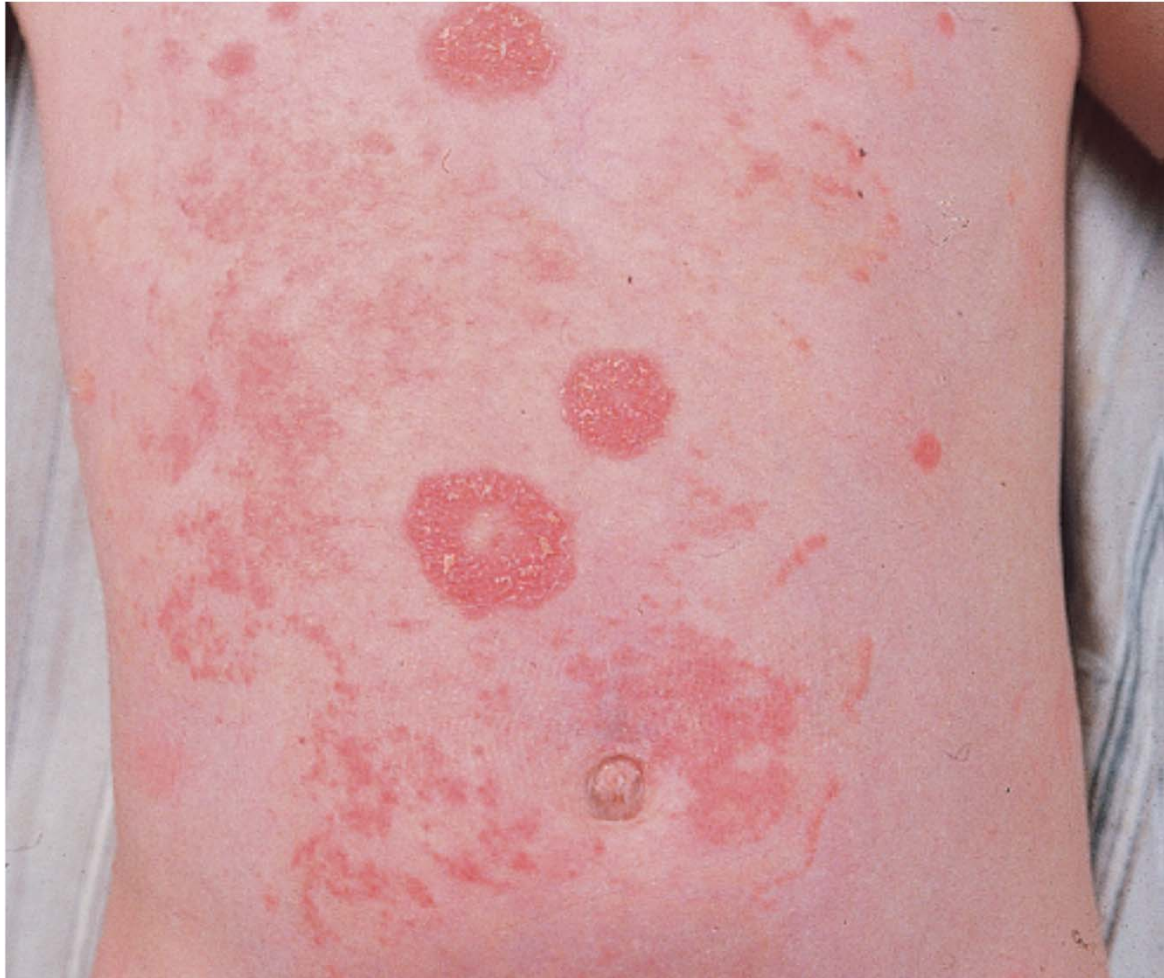

- Fungi imperfecti - Trichophyton
  - Epidermophyton
  - Microsporum
- Keratinophilic
- Sites :
  - a) Skin - face, palm, soles, body folds
  - b) Nail
  - c) Hair





# TINEA CORPORIS

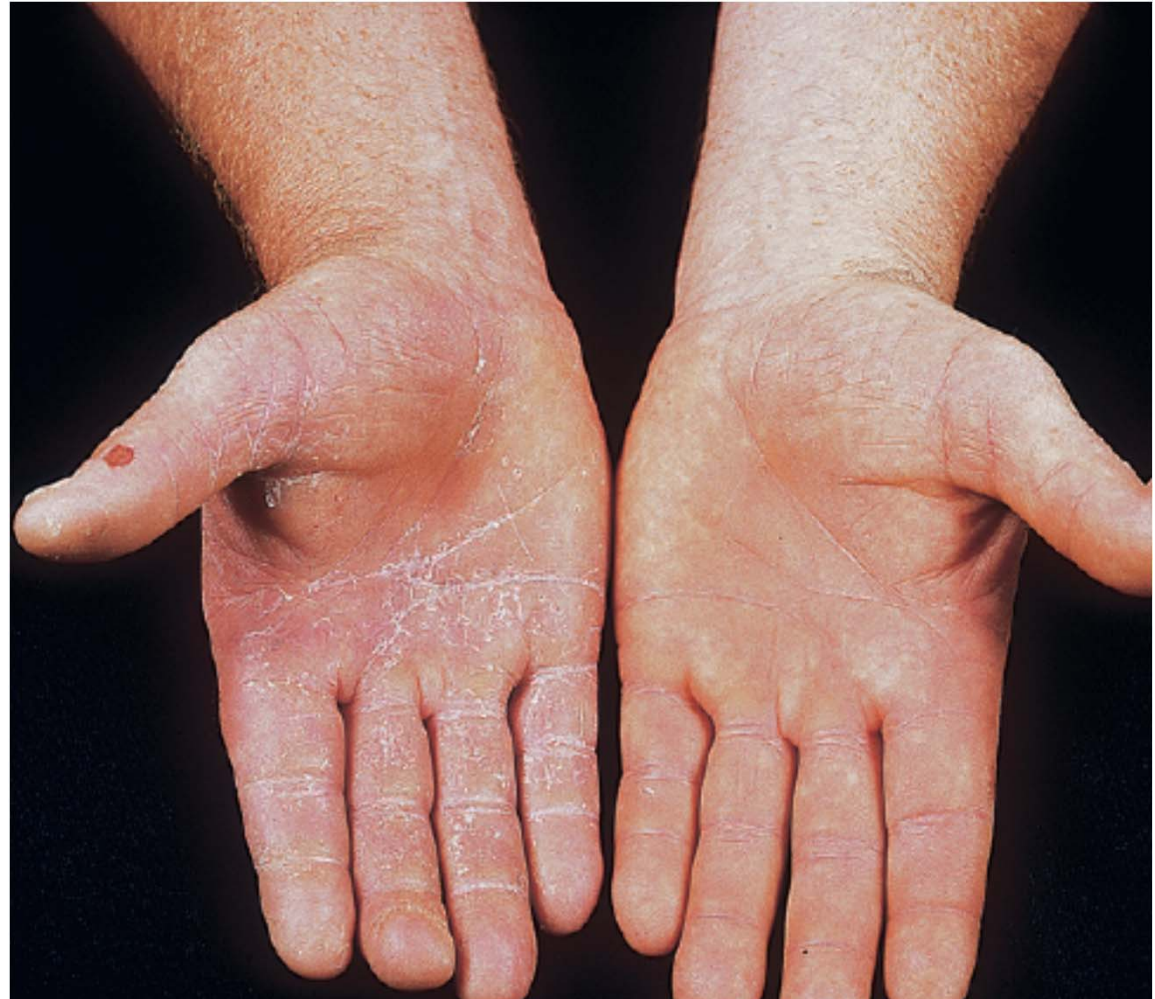

# TINEA MANUUM

Diffuse hyperkeratosis

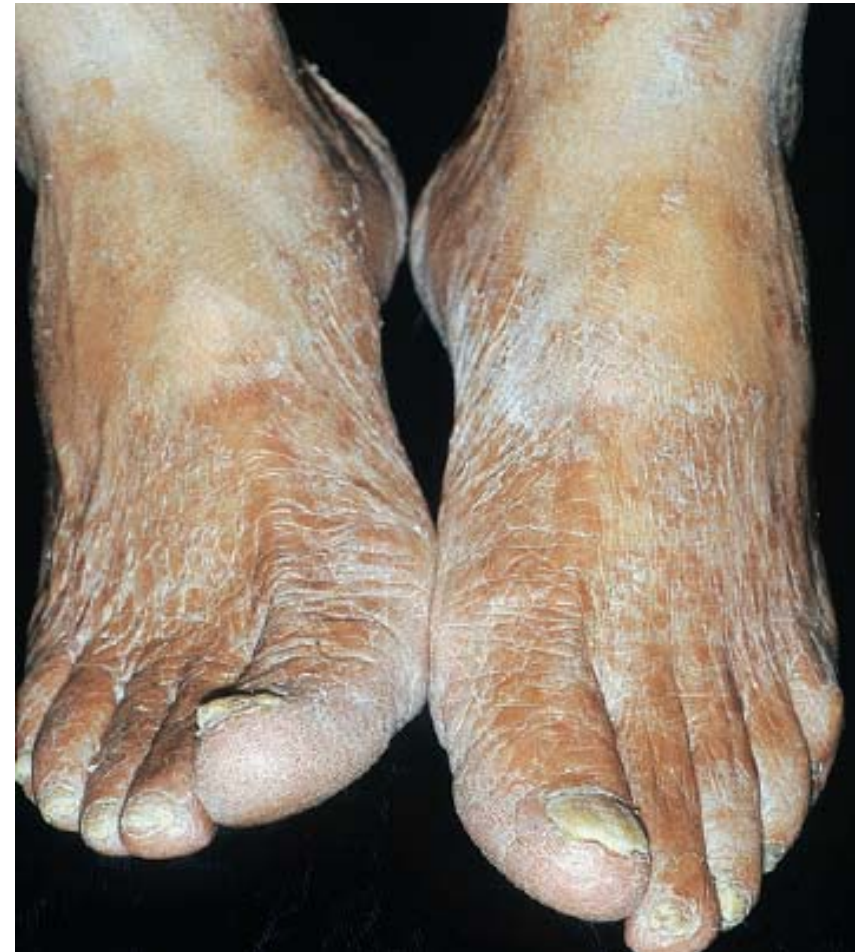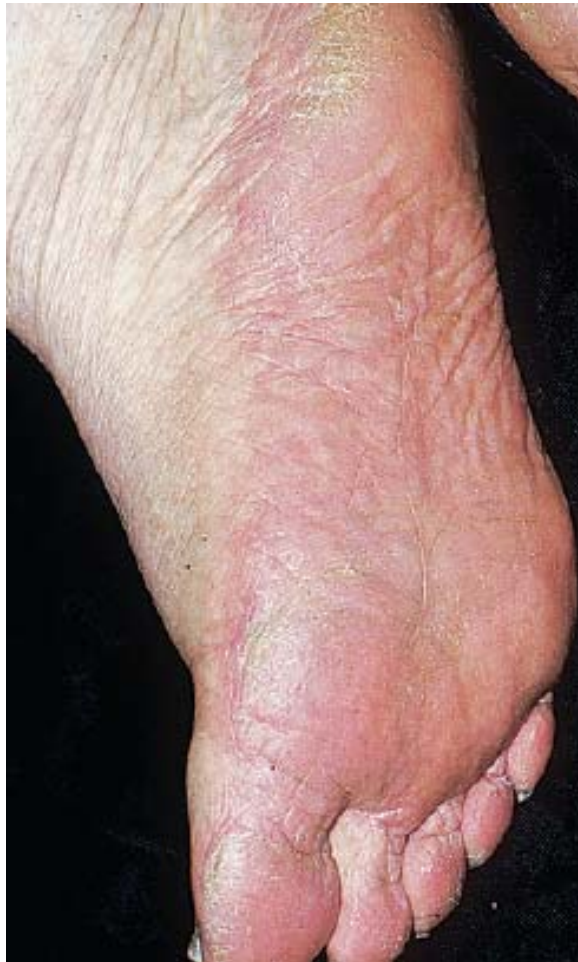Vesicular type

Nail



# TINEA PEDIS

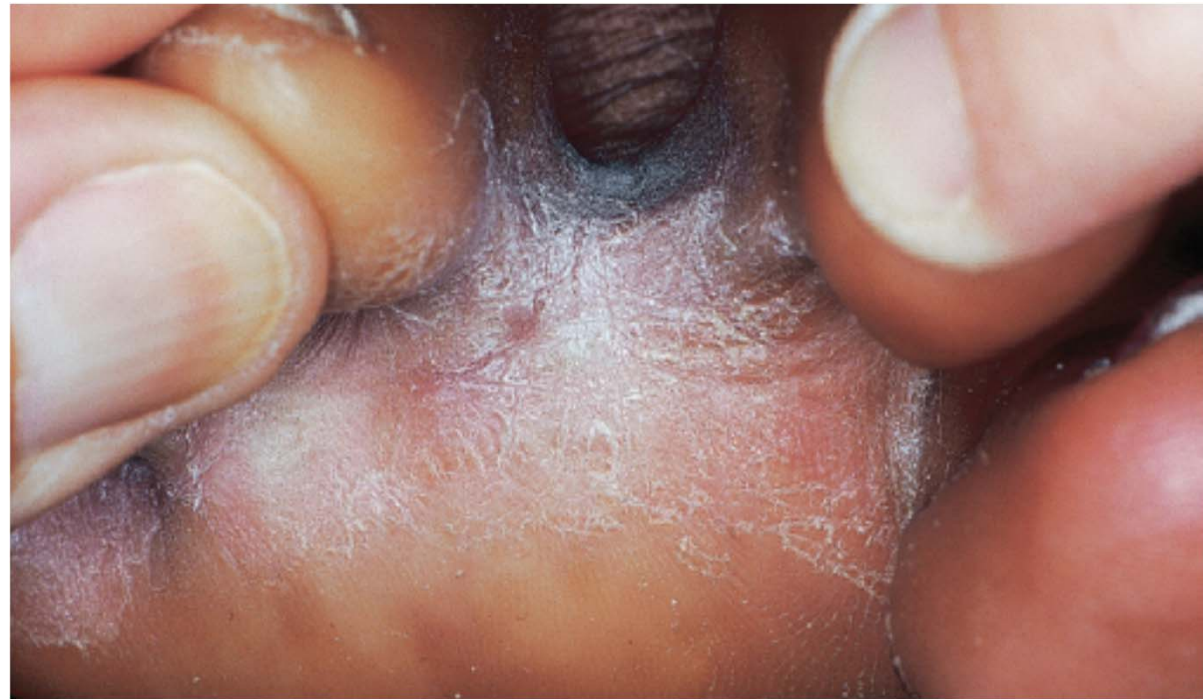Diffuse hyperkeratosis (Moccasin type)





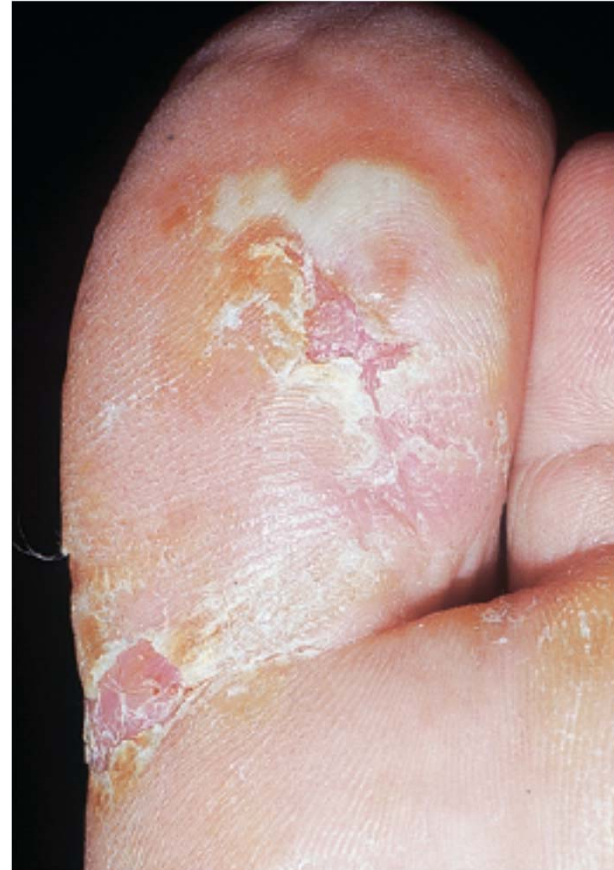# TINEA PEDIS

Intertrigo



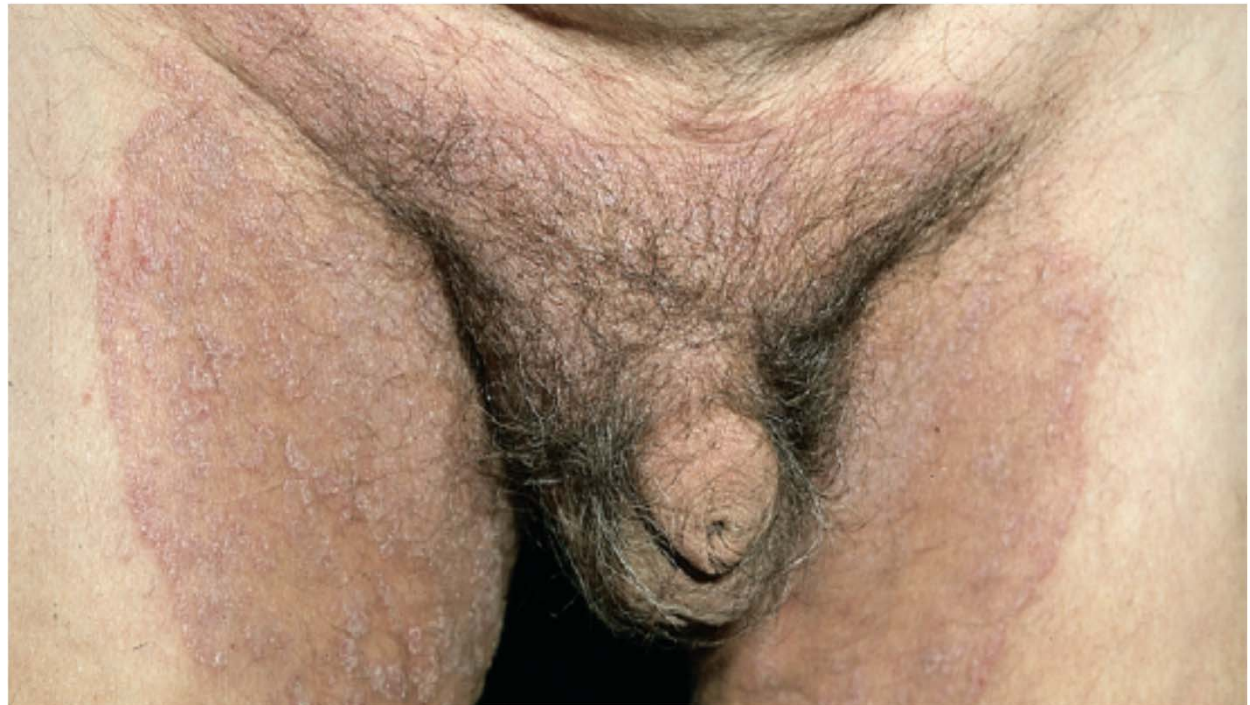# TINEA PEDIS

Vesicular type

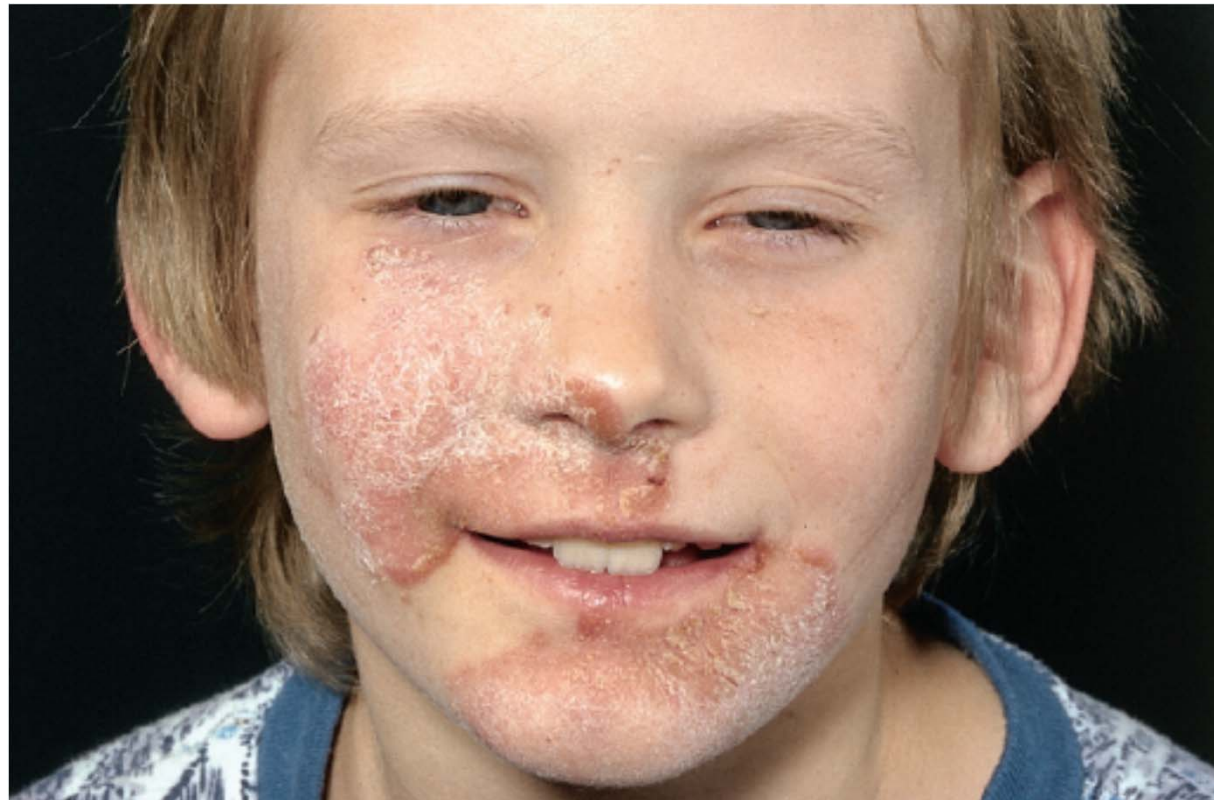

# TINEA CRURIS

Inguinal folds, buttock

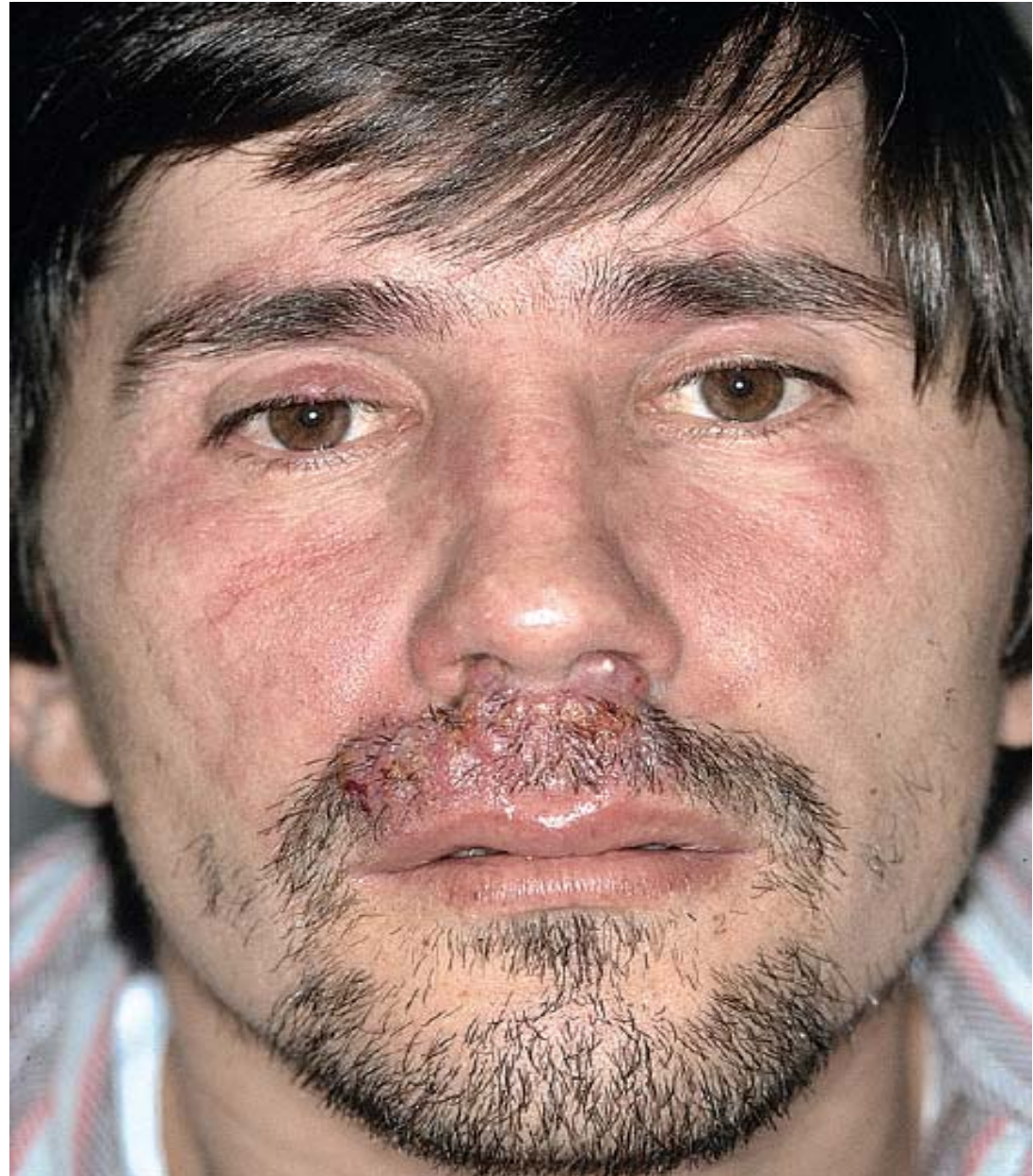

# TINEA FACIEI



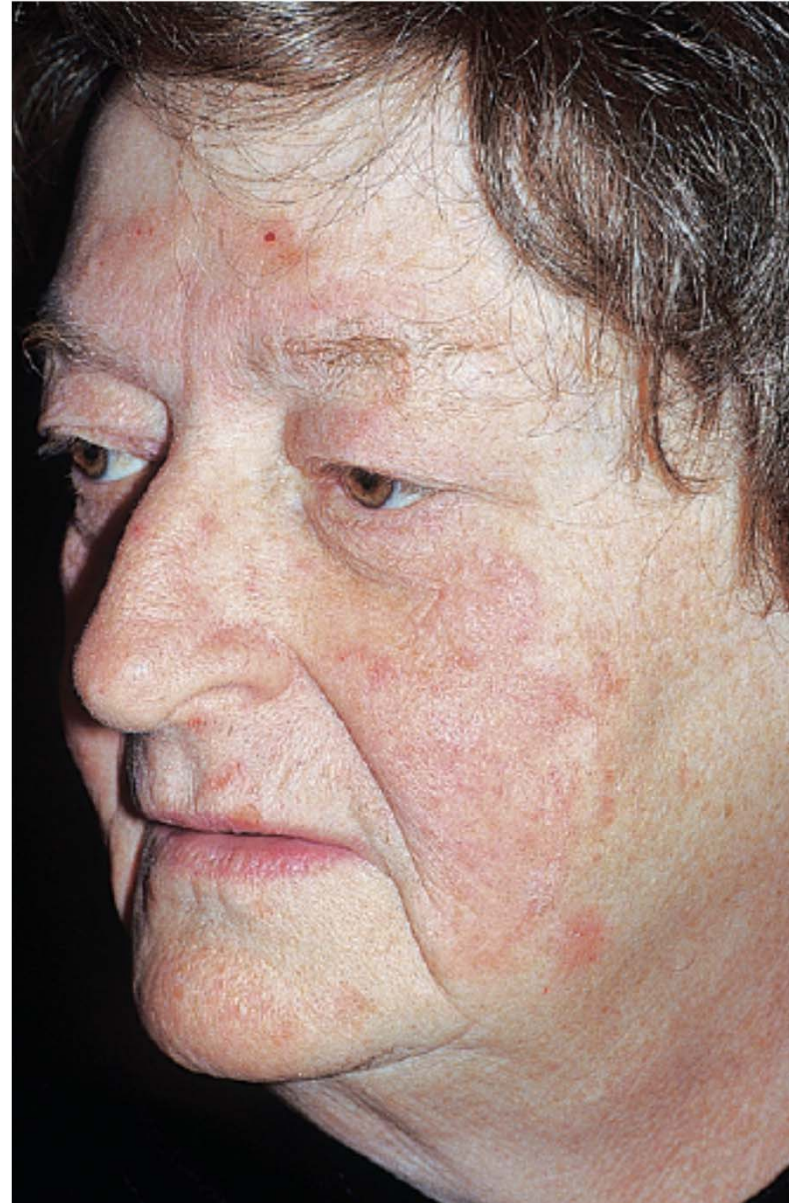

# TINEA FACIEI





# TINEA FACIEI



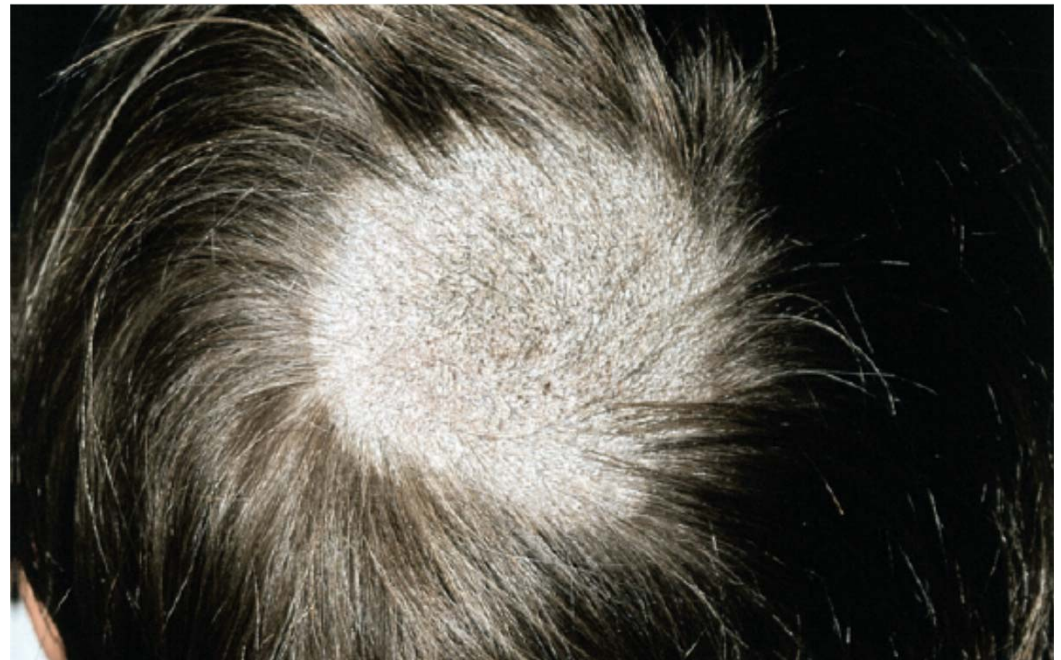# TINEA CAPITIS

**Alopecia**

**Hair easily pluckable**

**Children**

**Grey patch**

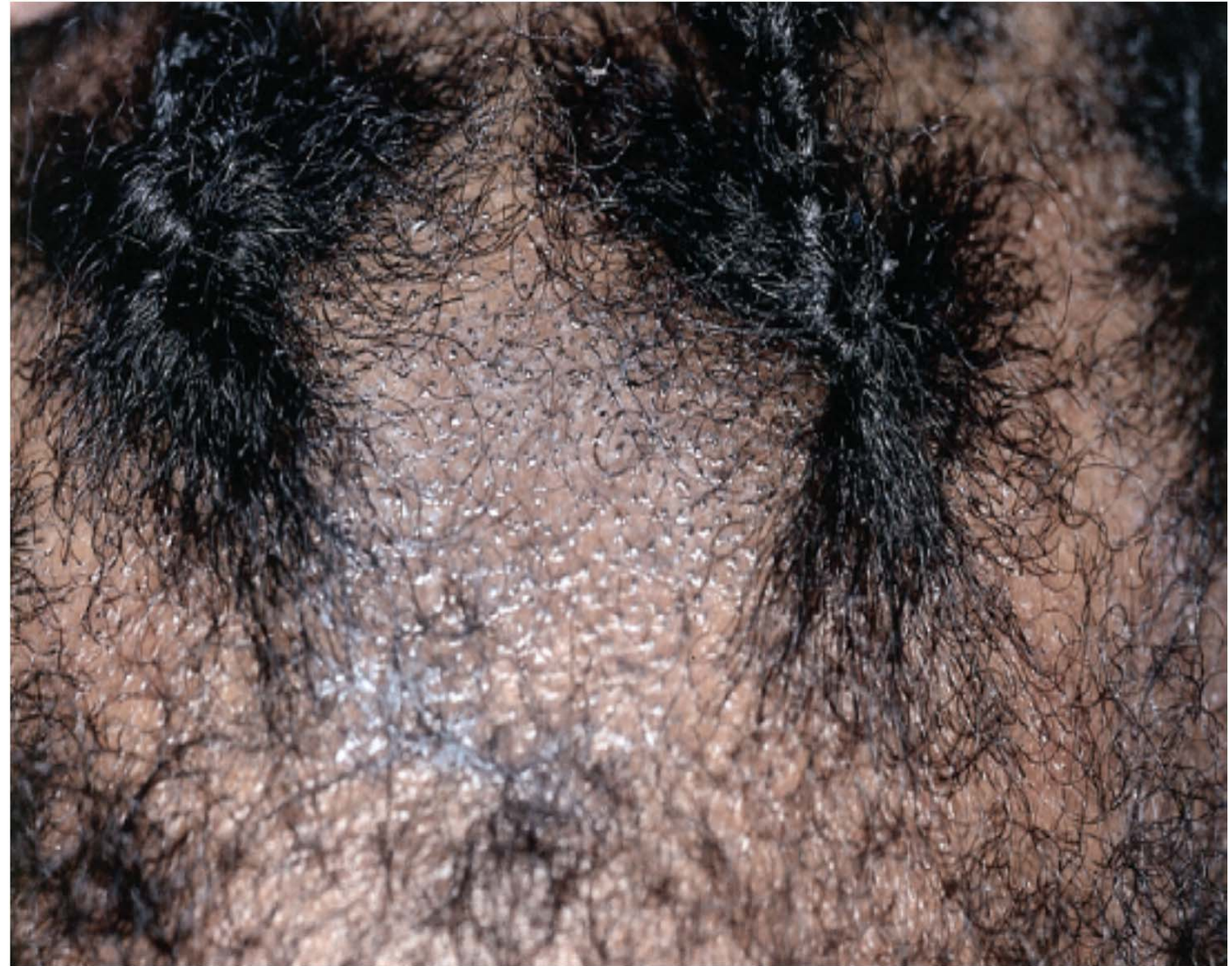



# TINEA CAPITIS

**Black dot**

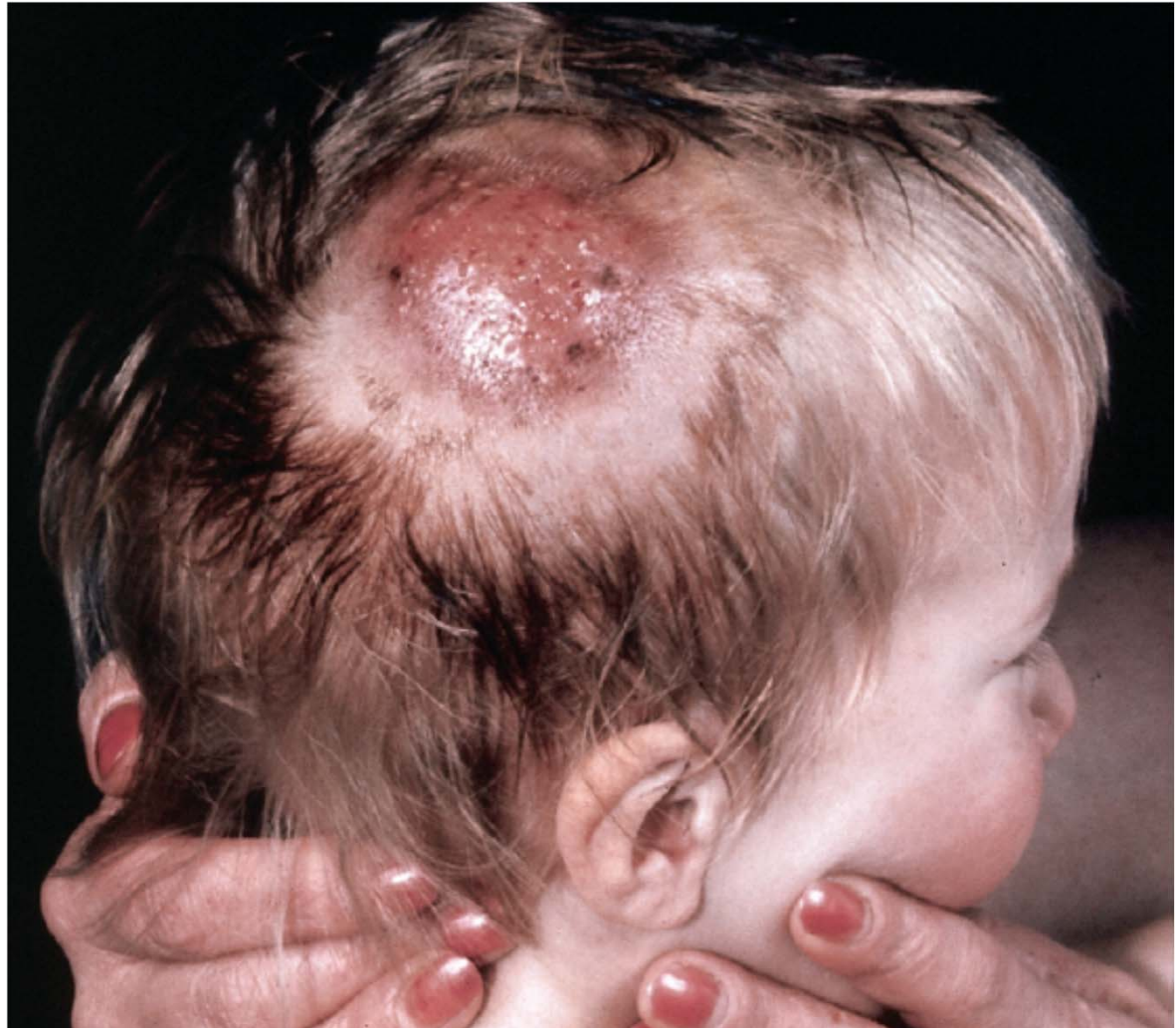**Alopecia  
Microsporum**



# TINEA CAPITIS

## Kerion

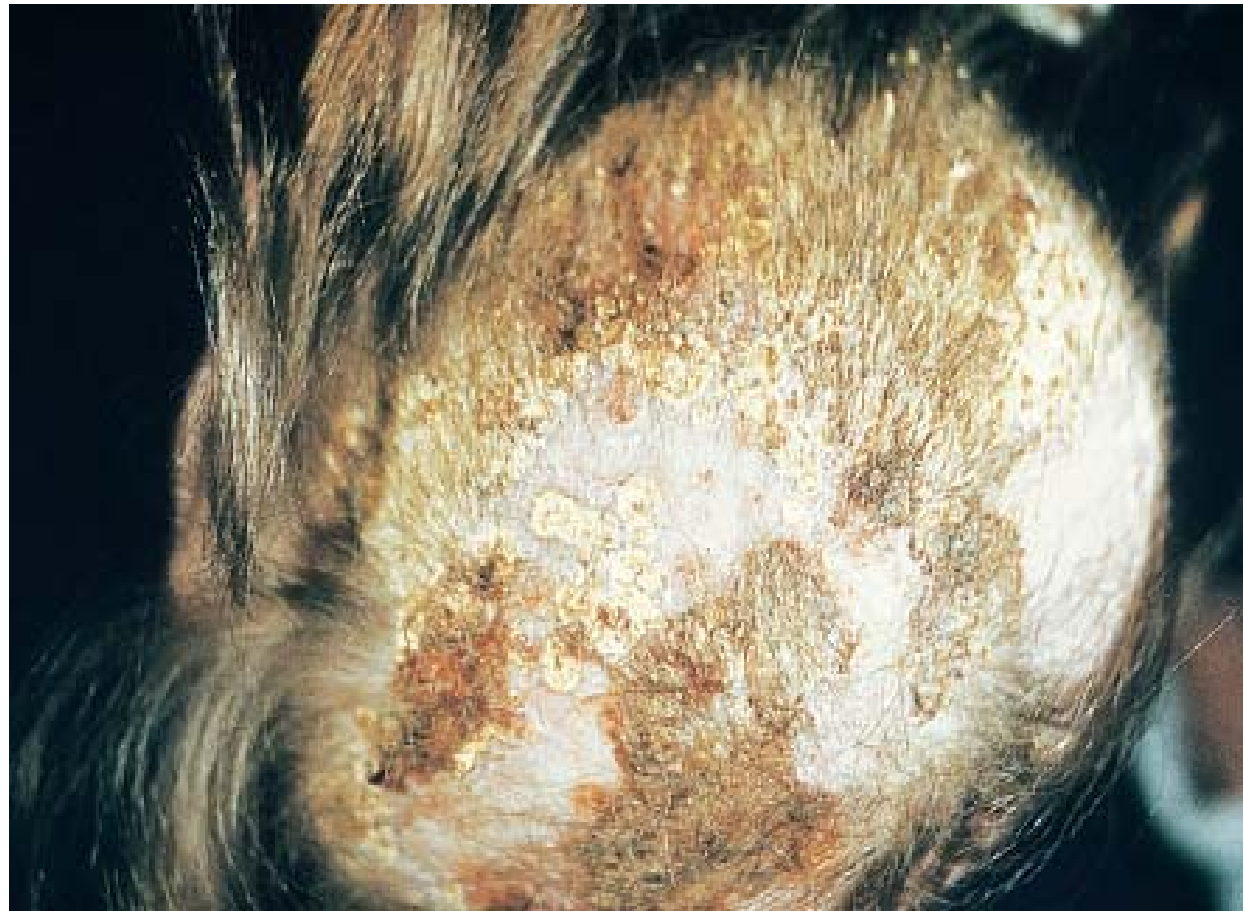- T. mentagrophytes
- Zoophilic
- **children**



# TINEA CAPITIS

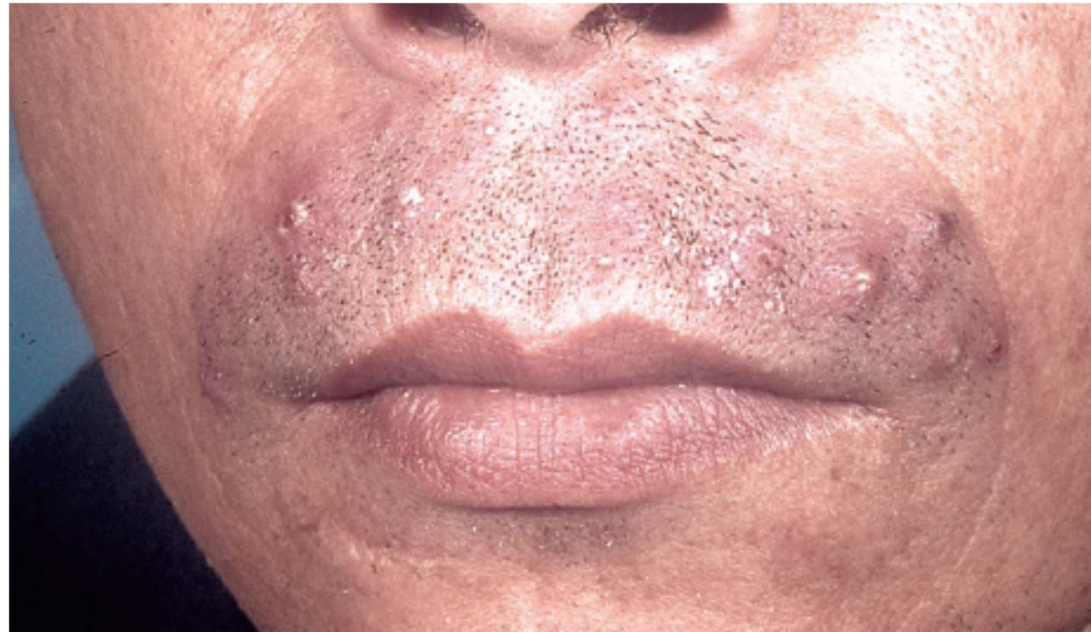## Favus

- *T. schoenlenii*
- scaly (scutula)



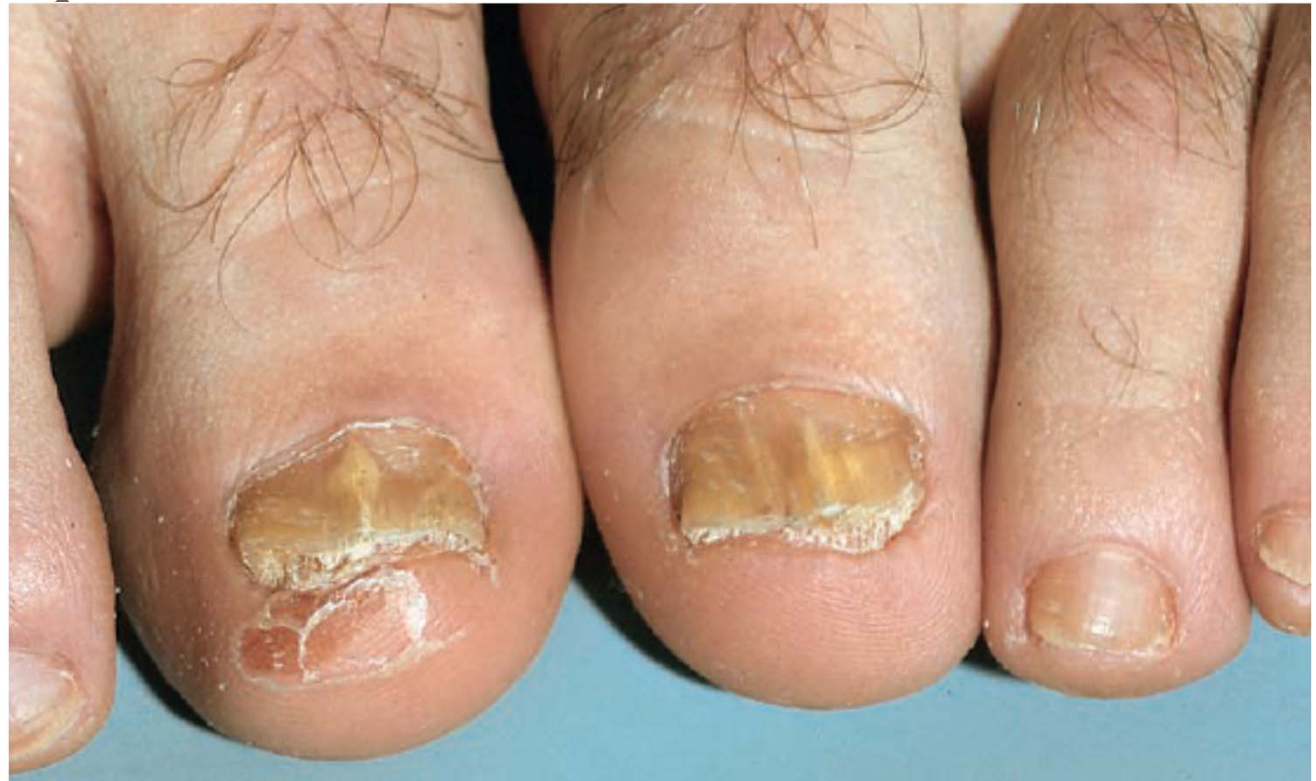

# TINEA BARBAE



# TINEA UNGUIUM

**Nail plate**





## **TINEA INCOGNITO**

- Steroid modified tinea

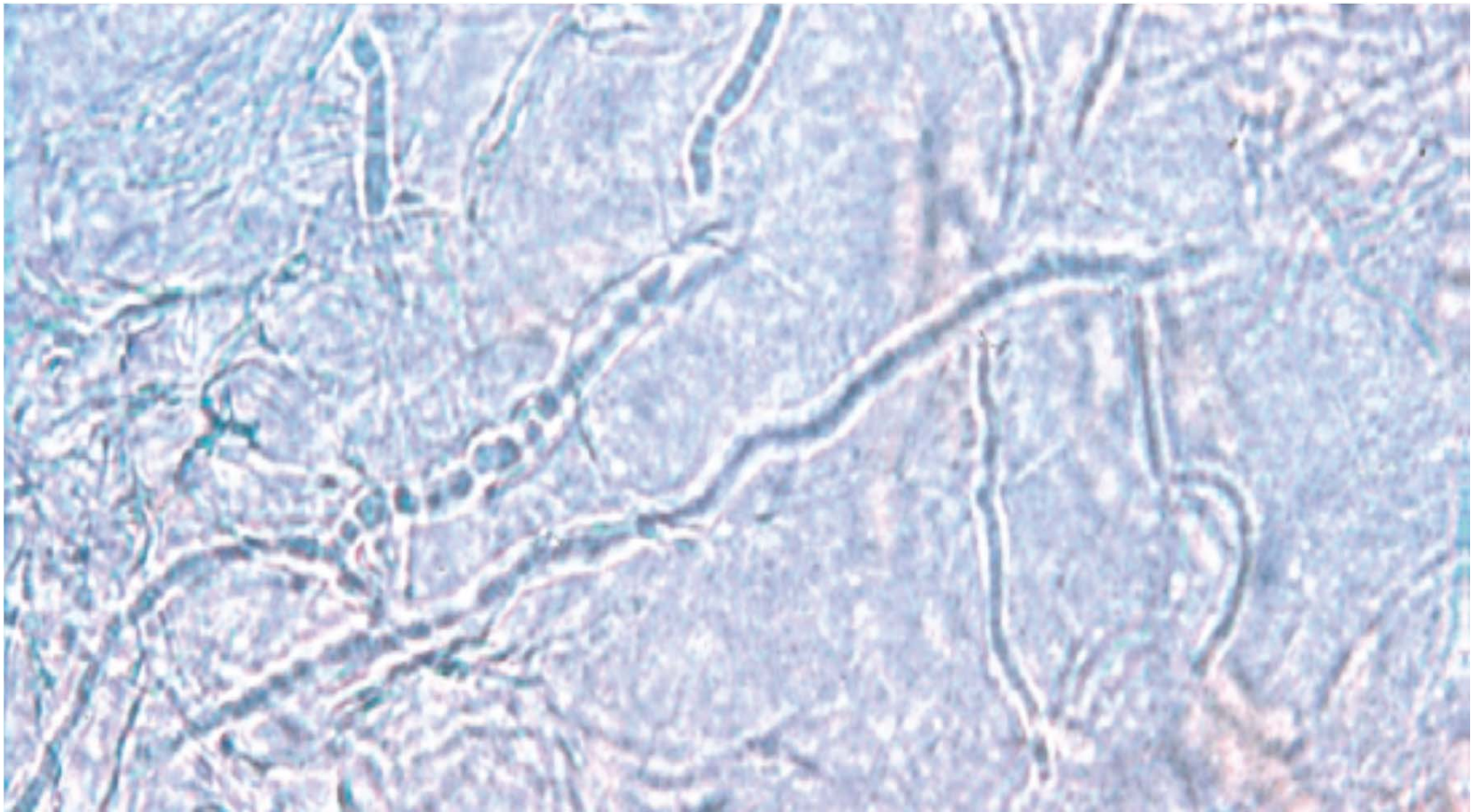
## **TINEA IMBRICATA**

- Trichophyton concentricum



# Diagnosis

- Isolation - KOH exam (10%)



- Culture

Sabouraud;s Dextrose agar

- Woods lamp Examination

# Treatment



## Topical

### a) Imidazole derivatives

- Clotrimazole
- Miconazole 1% cream/lotion
- Oxiconazole

## **b) Alkylamine derivatives**



Terbinafine 1% cream/lotion

Butenafine

Ciclopiroxolamine

## **c) Keratolytics**

Salicylic acid 3-6%

Urea/ lactic acid - 10-20%

- **OTHERS**



- Tolnafatate cream
- Whit field's ointment
- Undecenoic acid oint
- Haloprogin cream

# SYSTEMIC :

## Drug of choice (griseofulvin)

- Imidazoles
  - Fluconazole
  - Itraconazole
  - Ketoconazole
- Terbinafine

**CURE** - 6 weeks

**NAILS** - 6 months or more



**THANK YOU**